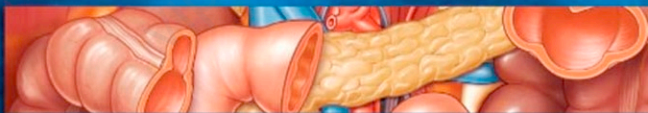
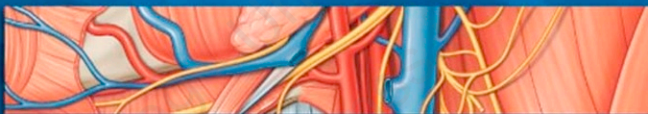
GRAY'S

ANATOMY

FOR STUDENTS **FLASH CARDS**

THIRD EDITION



United VRG

CHURCHILL
LIVINGSTONE
ELSEVIER

barbar77

Richard L. Drake
A. Wayne Vogl
Adam W. M. Mitchell

vip.bartons.ir

Study smart with

Student | **CONSULT**

Built with **inking**

Elsevier / StudentConsult.com

Transform the way you learn.

Compatible with PC, Mac®, most mobile devices, and eReaders, Student Consult allows you to browse, search, and interact with this title – online *and* offline. Redeem your PIN at studentconsult.com today!

PIN REDEMPTION INSTRUCTIONS

Start using these innovative features today:

- Seamless, real-time integration between devices
 - Straightforward navigation and search
 - Notes and highlights sharing with other users through social media
 - Self-assessment tools such as questions embedded within the text and multiple-format quizzes *
- * some features vary by title*

1. Login or Sign Up at StudentConsult.com
2. Scratch off your PIN code below
3. Enter PIN into the “Redeem a Book Code” box
4. Click “Redeem”
5. Go to “My Library”

Use of the current edition of the electronic version of this book (eBook) is subject to the terms of the nontransferable, limited license granted on StudentConsult.com. Access to the eBook is limited to the first individual who redeems the PIN, located on the inside cover of this book, at StudentConsult.com and may not be transferred to another party by resale, lending, or other means.

For technical assistance: Email: online.help@elsevier.com;

Call: within the US and Canada: 800-401-9962;
outside the US and Canada: +1-314-447-8200

UnitedVRG
Copyright © 2013



tahir99 - UnitedVRG
vip.persianss.ir



GRAY'S ANATOMY

FOR STUDENTS **FLASH CARDS**

tahir99 - UnitedVRG
vip.persianss.ir



tahir99 - UnitedVRG
vip.persianss.ir

GRAY'S ANATOMY

FOR STUDENTS FLASH CARDS

THIRD EDITION

Richard L. Drake, PhD, FAAA

Director of Anatomy
Professor of Surgery
Cleveland Clinic Lerner College of Medicine
Case Western Reserve University
Cleveland, Ohio, USA

A. Wayne Vogl, PhD, FAAA

Professor of Anatomy and Cell Biology
Department of Cellular and Physiological Sciences
Faculty of Medicine
University of British Columbia
Vancouver, British Columbia, Canada

Adam W. M. Mitchell, MB BS, FRCS, FRCR

Consultant Radiologist
Chelsea and Westminster Hospital
Honorary Senior Lecturer
Imperial College
London, UK

ILLUSTRATORS:

Richard M. Tibbitts and
Paul E. Richardson, Antbits Illustrations



ELSEVIER

tahir99
vipaper@stanos.ir

ELSEVIER

1600 John F. Kennedy Blvd.
Ste 1800
Philadelphia, PA 19103-2899

GRAY'S ANATOMY FOR STUDENTS FLASH CARDS
THIRD EDITION

ISBN: 978-1-4557-5898-2

Copyright © 2015 by Elsevier Inc.

All rights reserved. No part of this publication may be reproduced or transmitted in any form or by any means, electronic or mechanical, including photocopying, recording, or any information storage and retrieval system, without permission in writing from the publisher. Permissions may be sought directly from Elsevier's Rights Department: phone: (+1) 215 239 3804 (US) or (+44) 1865 843830 (UK); fax: (+44) 1865 853333; e-mail: healthpermissions@elsevier.com. You may also complete your request on-line via the Elsevier website at <http://www.elsevier.com/permissions>.

Notice

Knowledge and best practice in this field are constantly changing. As new research and experience broaden our knowledge, changes in practice, treatment and drug therapy may become necessary or appropriate. Readers are advised to check the most current information provided (i) on procedures featured or (ii) by the manufacturer of each product to be administered, to verify the recommended dose or formula, the method and duration of administration, and contraindications. It is the responsibility of the practitioner, relying on their own experience and knowledge of the patient, to make diagnoses, to determine dosages and the best treatment for each individual patient, and to take all appropriate safety precautions. To the fullest extent of the law, neither the Publisher nor the Editors assume any liability for any injury and/or damage to persons or property arising out of or related to any use of the material contained in this book.

The Publisher

Previous editions copyrighted 2010, 2005

VP Global Medical Education Content: Madelene Hyde
Senior Manager, Content Development: Rebecca Grulio
Publishing Services Manager: Patricia Tannian
Senior Project Manager: John Casey
Design and Art Direction: Lou Forgione

Printed in China

Last digit is the print number: 9 8 7 6 5 4 3 2 1

Copyright 2015, Elsevier Inc. All rights reserved.

تأهیر - UnitedVRG
no.persians.ir



CONTENTS

1	Overview	1-8
2	Back	9-34
3	Thorax	35-74
4	Abdomen	75-113
5	Pelvis and Perineum	114-133
6	Lower Limb	134-191
7	Upper Limb	192-258
8	Head and Neck	259-349
9	Surface Anatomy	350-369
10	Nervous System	370-377
11	Imaging	378-391





PREFACE

Gray's Anatomy for Students Flash Cards have proven to be a valuable learning aid for students hoping to enhance their understanding of human anatomy, and the 3rd edition continues this tradition. The question-and-answer format stimulates learning, and pertinent clinical information on most cards provides relevance. Each collection contains:

- Introductory overview cards with information about the skeletal, muscular, and cardiovascular systems in general, and surface features of the body
- Regionally organized cards demonstrating basic anatomy
- Surface anatomy cards showing important anatomical landmarks related to surface structures and clinical points
- Nervous system cards containing information about specific parts of the nervous system
- **New to this edition**—Imaging cards with common CT and MRI views of the body

In addition, a number of illustrations throughout the regional cards have been revised to correlate with changes made in the 3rd edition of *Gray's Anatomy for Students*.

It is our hope that the 3rd edition of the *Gray's Anatomy for Students Flash Cards* will make your learning more efficient and productive.






SECTION 1: OVERVIEW



1. Surface Anatomy: Male Anterior View
2. Surface Anatomy: Female Posterior View
3. Skeleton: Anterior View
4. Skeleton: Posterior View
5. Muscles: Anterior View
6. Muscles: Posterior View
7. Vascular System: Arteries
8. Vascular System: Veins

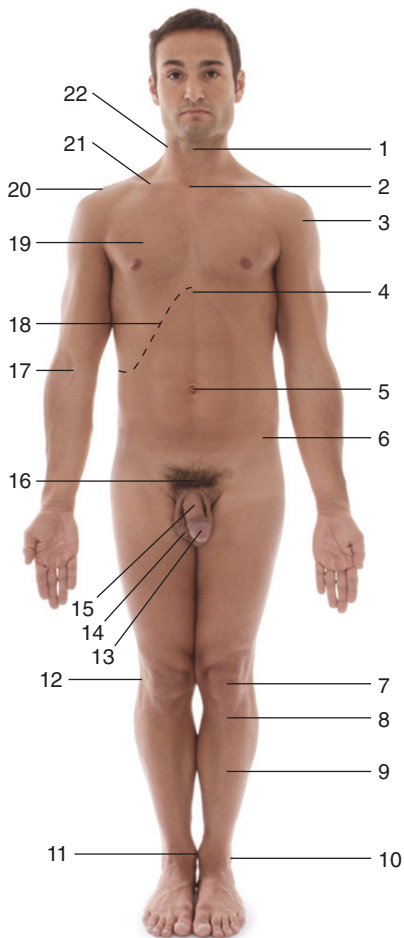




SURFACE ANATOMY: MALE ANTERIOR VIEW



Identify the indicated structures.





SURFACE ANATOMY: MALE ANTERIOR VIEW

1. Larynx
2. Jugular notch
3. Deltoid
4. Xiphoid process
5. Umbilicus
6. Anterior superior iliac spine
7. Patella
8. Tibial tuberosity
9. Tibia
10. Lateral malleolus
11. Medial malleolus
12. Head of fibula
13. Glans penis
14. Scrotum
15. Body of penis
16. Pubic symphysis
17. Cubital fossa
18. Costal margin
19. Pectoralis major
20. Acromion
21. Clavicle
22. Sternocleidomastoid

Figure from Gray's Atlas of Anatomy, 2nd edition, p. 4.

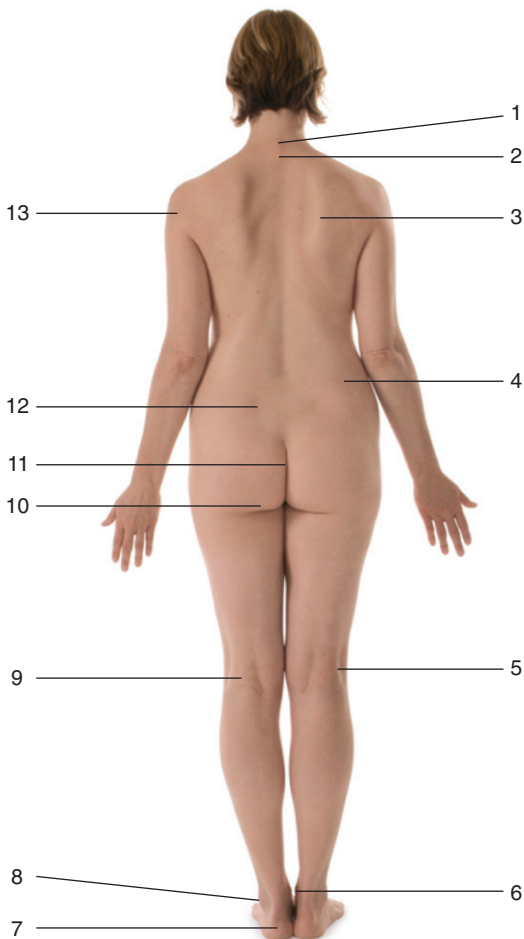


SURFACE ANATOMY: FEMALE POSTERIOR VIEW



2

Identify the indicated structures.





SURFACE ANATOMY: FEMALE POSTERIOR VIEW

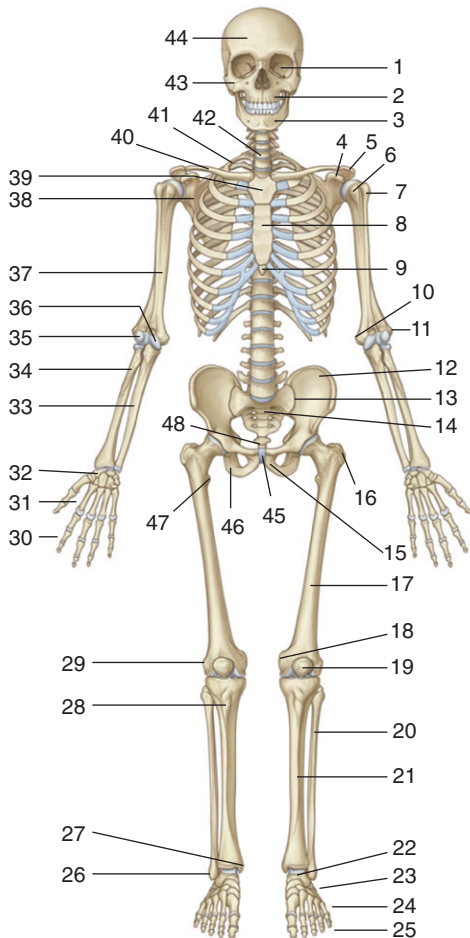
1. Vertebra prominens (spinous process of CVII)
2. Spinous process of T1
3. Medial border of scapula
4. Iliac crest
5. Biceps femoris tendon
6. Medial malleolus
7. Calcaneal tuberosity
8. Lateral malleolus
9. Popliteal fossa
10. Gluteal fold
11. Intergluteal cleft
12. Sacral dimple at posterior superior iliac spine
13. Deltoid

Figure from Gray's Atlas of Anatomy, 2nd edition, p. 5.

SKELETON: ANTERIOR VIEW

3

Identify the indicated structures.





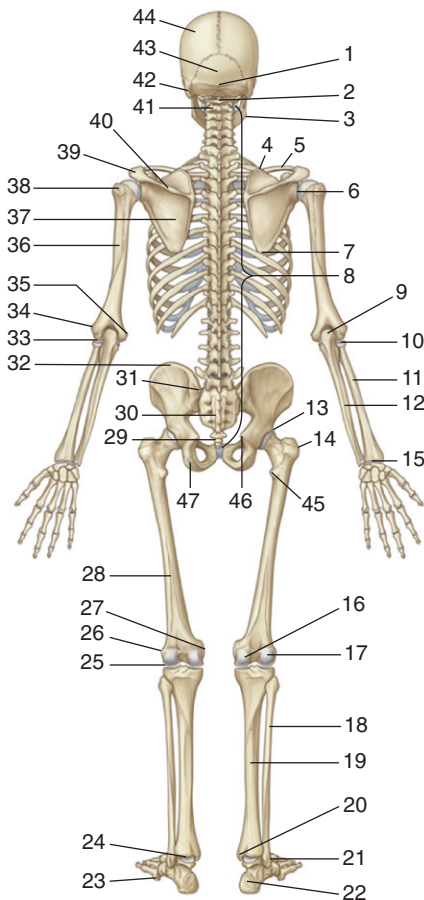
SKELETON: ANTERIOR VIEW

- | | |
|--|-----------------------------------|
| 1. Orbit | 24. Metatarsals |
| 2. Maxilla | 25. Phalanges |
| 3. Mandible | 26. Lateral malleolus |
| 4. Coracoid process | 27. Medial malleolus |
| 5. Acromion | 28. Tibial tuberosity |
| 6. Lesser tubercle | 29. Lateral epicondyle (of femur) |
| 7. Greater tubercle | 30. Phalanges |
| 8. Body of sternum | 31. Metacarpals |
| 9. Xiphoid process of sternum | 32. Carpal bones |
| 10. Medial epicondyle
(of humerus) | 33. Ulna |
| 11. Lateral epicondyle
(of humerus) | 34. Radius |
| 12. Ilium | 35. Capitulum |
| 13. Sacroiliac joint | 36. Trochlea |
| 14. Sacrum | 37. Humerus |
| 15. Pubis | 38. Scapula |
| 16. Greater trochanter | 39. Manubrium of sternum |
| 17. Femur | 40. Clavicle |
| 18. Medial epicondyle (of femur) | 41. Rib I |
| 19. Patella | 42. CVII |
| 20. Fibula | 43. Zygomatic bone |
| 21. Tibia | 44. Frontal bone |
| 22. Talus | 45. Pubic symphysis |
| 23. Tarsal bones | 46. Ischium |
| | 47. Lesser trochanter |
| | 48. Coccyx |

Figure from Gray's Atlas of Anatomy, 2nd edition, p. 6.

SKELETON: POSTERIOR VIEW

Identify the indicated structures.





SKELETON: POSTERIOR VIEW



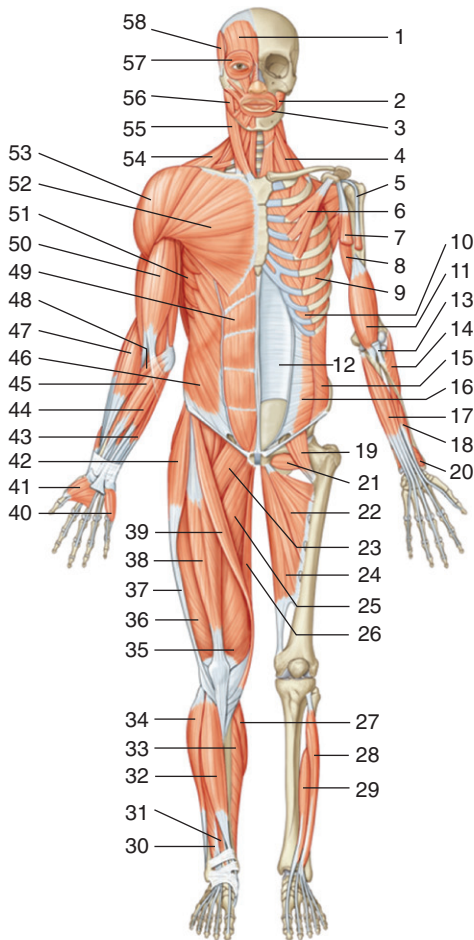
1. External occipital protuberance
2. CI (atlas)
3. Angle of mandible
4. Superior angle of scapula
5. Clavicle
6. Shoulder joint
7. Inferior angle of scapula
8. Vertebral column
9. Olecranon
10. Head of radius
11. Radius
12. Ulna
13. Hip joint
14. Greater trochanter
15. Wrist joint
16. Medial condyle (of femur)
17. Lateral condyle (of femur)
18. Fibula
19. Tibia
20. Medial malleolus
21. Lateral malleolus
22. Calcaneus
23. Tuberosity of fifth metatarsal
24. Ankle joint
25. Knee joint
26. Lateral epicondyle (of femur)
27. Medial epicondyle (of femur)
28. Femur
29. Coccyx
30. Sacrum
31. Posterior superior iliac spine
32. Iliac crest
33. Elbow joint
34. Lateral epicondyle (of humerus)
35. Medial epicondyle (of humerus)
36. Humerus
37. Scapula
38. Greater tubercle
39. Acromion
40. Spine of scapula
41. CII (axis)
42. Mastoid process
43. Occipital bone
44. Parietal bone
45. Lesser trochanter
46. Ischial spine
47. Ischial tuberosity

Figure from Gray's Atlas of Anatomy, 2nd edition, p. 7.

MUSCLES: ANTERIOR VIEW

5

Identify the indicated structures.





MUSCLES: ANTERIOR VIEW



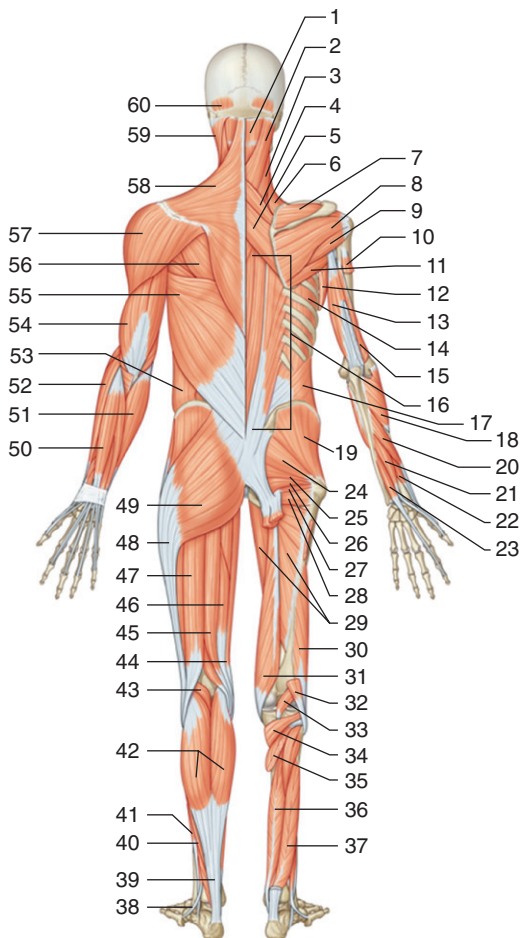
1. Frontalis
2. Buccinator
3. Orbicularis oris
4. Scalenes
5. Long head of biceps brachii (cut)
6. Pectoralis minor
7. Short head of biceps brachii (cut)
8. Coracobrachialis
9. External intercostal
10. Internal intercostal
11. Brachialis
12. Posterior wall of rectus sheath
13. Biceps brachii tendon (cut)
14. Supinator (superficial head)
15. Internal oblique (cut)
16. Transversus abdominis
17. Flexor digitorum profundus
18. Flexor pollicis longus
19. Iliopsoas
20. Pronator quadratus
21. Obturator externus
22. Adductor brevis
23. Pectineus
24. Adductor magnus
25. Adductor longus
26. Gracilis
27. Gastrocnemius
28. Extensor digitorum longus
29. Extensor hallucis longus
30. Extensor digitorum longus
31. Extensor hallucis longus
32. Tibialis anterior
33. Soleus
34. Fibularis longus
35. Vastus medialis
36. Vastus lateralis
37. Iliotibial tract
38. Rectus femoris
39. Sartorius
40. Hypothenar
41. Thenar
42. Tensor fasciae latae
43. Flexor carpi ulnaris
44. Palmaris longus
45. Flexor carpi radialis
46. External oblique
47. Brachioradialis
48. Pronator teres
49. Rectus abdominis
50. Biceps brachii
51. Serratus anterior
52. Pectoralis major
53. Deltoid
54. Trapezius
55. Sternocleidomastoid
56. Masseter
57. Orbicularis oculi
58. Temporalis

Figure from Gray's Atlas of Anatomy, 2nd edition, p. 8.

MUSCLES: POSTERIOR VIEW

6

Identify the indicated structures.

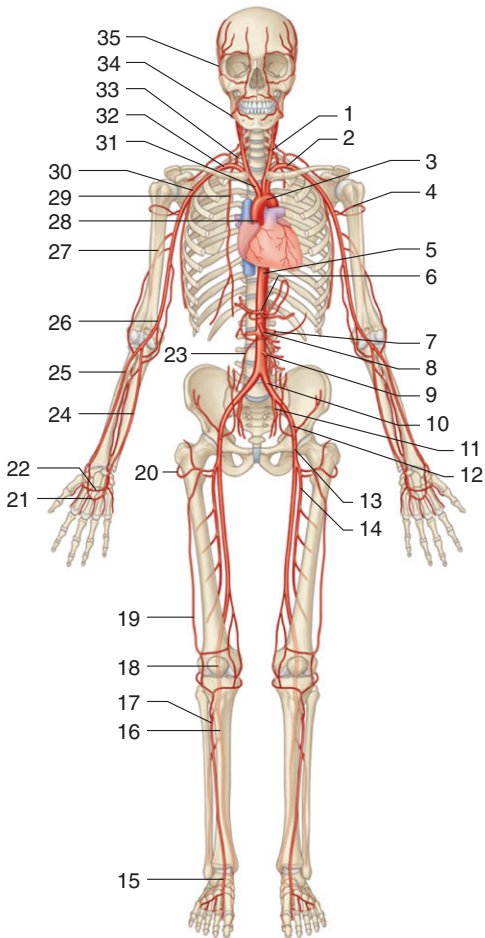


MUSCLES: POSTERIOR VIEW

1. Semispinalis capitis
2. Splenius capitis
3. Splenius cervicis
4. Rhomboid minor
5. Rhomboid major
6. Levator scapulae
7. Supraspinatus
8. Infraspinatus
9. Teres minor
10. Lateral head of triceps brachii (cut)
11. Teres major
12. Latissimus dorsi (cut)
13. Long head of triceps brachii
14. External intercostal
15. Medial head of triceps brachii
16. Erector spinae
17. Internal oblique
18. Supinator (deep head)
19. Gluteus medius
20. Abductor pollicis longus
21. Extensor pollicis longus
22. Extensor pollicis brevis
23. Extensor indicis
24. Piriformis
25. Gemellus superior
26. Obturator internus
27. Gemellus inferior
28. Quadratus femoris
29. Adductor magnus
30. Short head of biceps femoris
31. Semimembranosus
32. Long head of biceps femoris (cut)
33. Plantaris (cut)
34. Popliteus
35. Soleus (cut)
36. Flexor digitorum longus
37. Flexor hallucis longus
38. Fibularis brevis (tendon)
39. Calcaneal tendon
40. Soleus
41. Fibularis longus
42. Gastrocnemius
43. Plantaris
44. Gracilis
45. Semimembranosus
46. Semitendinosus
47. Long head of biceps femoris
48. Iliotibial tract
49. Gluteus maximus
50. Extensor digitorum
51. Flexor carpi ulnaris
52. Extensor carpi radialis longus
53. External oblique
54. Triceps brachii
55. Latissimus dorsi
56. Infraspinatus
57. Deltoid
58. Trapezius
59. Sternocleidomastoid
60. Occipitalis

Figure from Gray's Atlas of Anatomy, 2nd edition, p. 9.

Identify the indicated arteries.





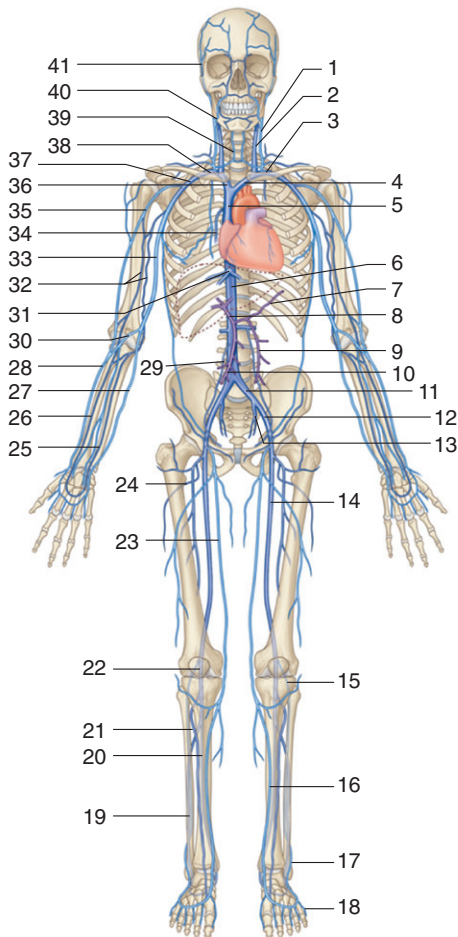
VASCULAR SYSTEM: ARTERIES



1. Left common carotid artery
2. Left subclavian artery
3. Arch of aorta
4. Anterior circumflex humeral artery
5. Thoracic aorta
6. Celiac trunk
7. Left renal artery
8. Superior mesenteric artery
9. Inferior mesenteric artery
10. Left common iliac artery
11. Left internal iliac artery
12. Left external iliac artery
13. Femoral artery
14. Deep artery of thigh
15. Dorsalis pedis artery
16. Posterior tibial artery
17. Anterior tibial artery
18. Popliteal artery
19. Descending branch of lateral circumflex femoral artery
20. Transverse branch of lateral circumflex femoral artery
21. Superficial palmar arch
22. Deep palmar arch
23. Testicular/ovarian artery
24. Ulnar artery
25. Radial artery
26. Brachial artery
27. Profunda brachii artery
28. Ascending aorta
29. Internal thoracic artery
30. Axillary artery
31. Brachiocephalic trunk
32. Right subclavian artery
33. Vertebral artery
34. Facial artery
35. Superficial temporal artery

Figure from Gray's Atlas of Anatomy, 2nd edition, p. 10.

Identify the indicated veins.





VASCULAR SYSTEM: VEINS



1. Left external jugular vein
2. Left internal jugular vein
3. Left subclavian vein
4. Left brachiocephalic vein
5. Superior vena cava
6. Inferior vena cava
7. Splenic vein
8. Portal vein
9. Inferior mesenteric vein
10. Superior mesenteric vein
11. Left common iliac vein
12. Left external iliac vein
13. Left internal iliac vein
14. Femoral vein
15. Small saphenous vein
16. Great saphenous vein
17. Small saphenous vein
18. Dorsal venous arch
19. Posterior fibular vein
20. Posterior tibial vein
21. Anterior tibial vein
22. Popliteal vein
23. Great saphenous vein
24. Deep vein of thigh
25. Ulnar vein
26. Radial vein
27. Basilic vein
28. Cephalic vein
29. Testicular/ovarian vein
30. Median cubital vein
31. Hepatic vein
32. Brachial veins
33. Basilic vein
34. Azygos vein
35. Cephalic vein
36. Right brachiocephalic vein
37. Axillary vein
38. Right subclavian vein
39. Anterior jugular vein
40. Facial vein
41. Superficial temporal vein

Figure from Gray's Atlas of Anatomy, 2nd edition, p. 11.



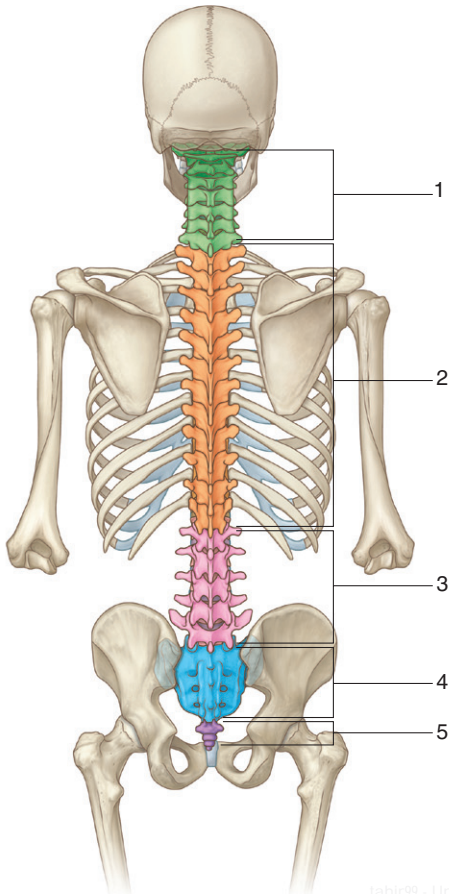
SECTION 2: BACK

9. Skeletal Framework: Vertebral Column
10. Skeletal Framework: Typical Vertebra
11. Skeletal Framework: Vertebra 1
12. Skeletal Framework: Atlas, Axis, and Ligaments
13. Skeletal Framework: Vertebra 2
14. Skeletal Framework: Vertebra 3
15. Skeletal Framework: Sacrum and Coccyx
16. Skeletal Framework: Vertebra Radiograph I
17. Skeletal Framework: Vertebra Radiograph II
18. Skeletal Framework: Vertebra Radiograph III
19. Skeletal Framework: Intervertebral Joints
20. Skeletal Framework: Intervertebral Foramen
21. Skeletal Framework: Vertebral Ligaments
22. Skeletal Framework: Intervertebral Disc Protrusion
23. Muscles: Superficial Group
24. Muscles: Trapezius Innervation and Blood Supply
25. Muscles: Intermediate Group
26. Muscles: Erector Spinae
27. Muscles: Transversospinalis and Segmentals
28. Muscles: Suboccipital Region
29. Spinal Cord
30. Spinal Cord Details
31. Spinal Nerves
32. Spinal Cord Arteries
33. Spinal Cord Arteries Detail
34. Spinal Cord Meninges



SKELETAL FRAMEWORK: VERTEBRAL COLUMN

*Identify the indicated vertebral regions.
How many vertebrae are in each region?*



SKELETAL FRAMEWORK: VERTEBRAL COLUMN



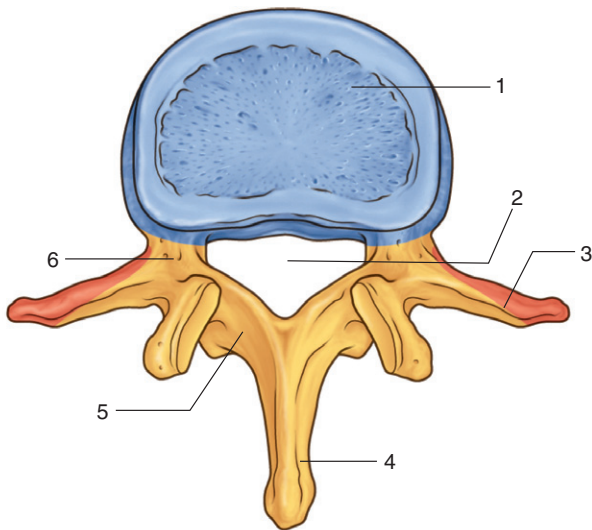
1. Cervical (7 vertebrae; C1-CVII)
2. Thoracic (12 vertebrae; T1-TXII)
3. Lumbar (5 vertebrae; L1-LV)
4. Sacral (5 fused vertebrae I-V; sacrum)
5. Coccygeal (3 or 4 coccygeal vertebrae; coccyx)

IN THE CLINIC:

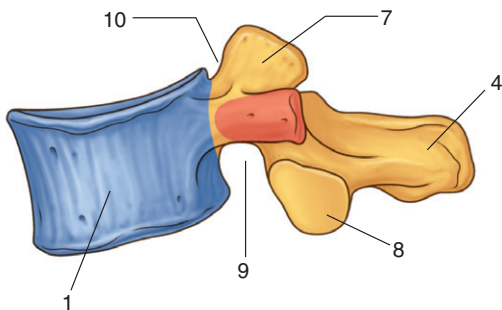
- **Vertebral fractures can result in damage to the spinal cord or to spinal nerves.**

Figure from Gray's Anatomy for Students, 3rd edition, p. 56.

Identify the indicated parts of the vertebra.



Superior view



Lateral view

SKELETAL FRAMEWORK: TYPICAL VERTEBRA



1. Vertebral body
2. Vertebral foramen
3. Transverse process
4. Spinous process
5. Lamina
6. Pedicle
7. Superior articular process
8. Inferior articular process
9. Inferior vertebral notch
10. Superior vertebral notch

IN THE CLINIC:

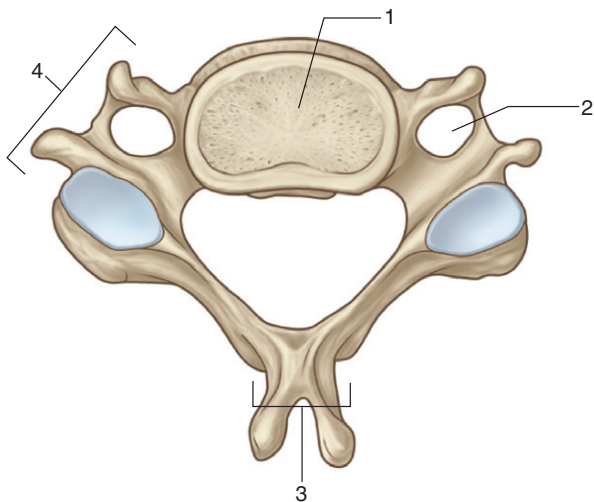
- During surgery, a laminectomy (removal of the laminae) is used to access the vertebral canal.

Figure from Gray's Anatomy for Students, 3rd edition, p. 57.

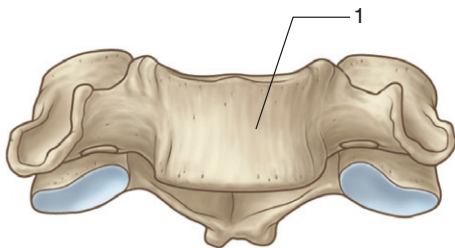
SKELETAL FRAMEWORK: VERTEBRA 1

11

From which region of the vertebral column is this vertebra? Identify the indicated structures.



Superior view



Anterior view

SKELETAL FRAMEWORK: VERTEBRA 1



This vertebra is from the cervical region.

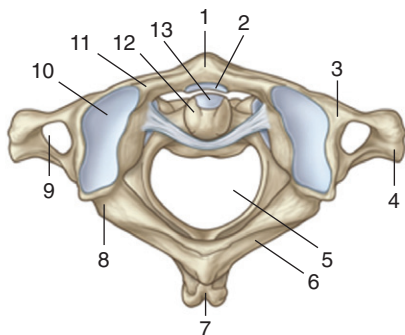
1. Vertebral body
2. Foramen transversarium
3. Spinous process
4. Transverse process

IN THE CLINIC:

- **The vertebral artery and associated veins pass through the foramen transversarium and can be damaged in this location.**

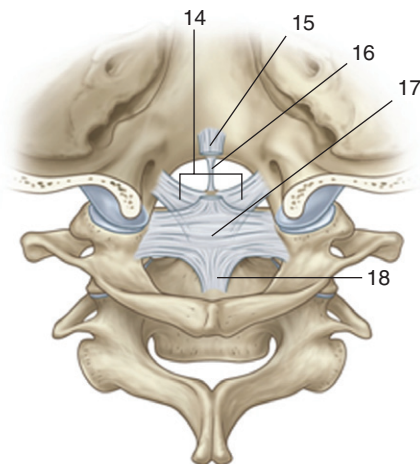
Figure from Gray's Anatomy for Students, 3rd edition, p. 69.

Identify these two vertebrae. Identify the indicated structures.



A

Superior view



B

Posterior view

SKELETAL FRAMEWORK: ATLAS, AXIS, AND LIGAMENTS



A. Atlas and Axis (superior view)

1. Anterior tubercle
2. Articular facet for dens
3. Lateral mass
4. Transverse process
5. Vertebral foramen
6. Posterior arch
7. Posterior tubercle
8. Groove for vertebral artery
9. Foramen transversarium
10. Superior articular facet
11. Anterior arch
12. Dens
13. Anterior articular facet

B. Ligaments (posterior view)

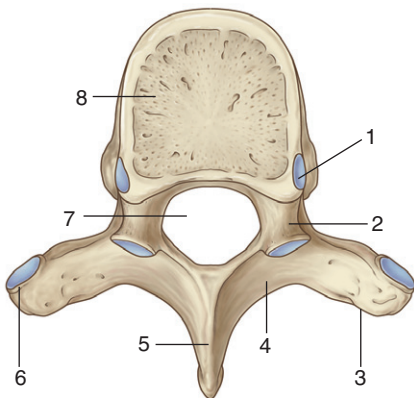
14. Alar ligaments
15. Superior longitudinal band of cruciform ligament
16. Apical ligament of dens
17. Transverse ligament of atlas
18. Inferior longitudinal band of cruciform ligament

Figure from Gray's Atlas of Anatomy, 2nd edition, p. 537.

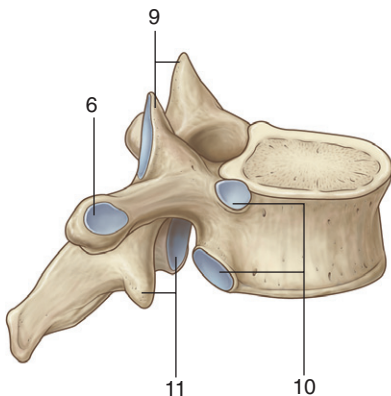
SKELETAL FRAMEWORK: VERTEBRA 2

13

From which region of the vertebral column is this vertebra? Identify the indicated structures.



Superior view



Lateral view

SKELETAL FRAMEWORK: VERTEBRA 2



This vertebra is from the thoracic region.

1. Superior demifacet for articulation with head of rib above
2. Pedicle
3. Transverse process
4. Lamina
5. Spinous process
6. Facet for articulation with tubercle of rib
7. Vertebral foramen
8. Vertebral body
9. Superior articular processes
10. Demifacets for articulation with head of ribs
11. Inferior articular processes

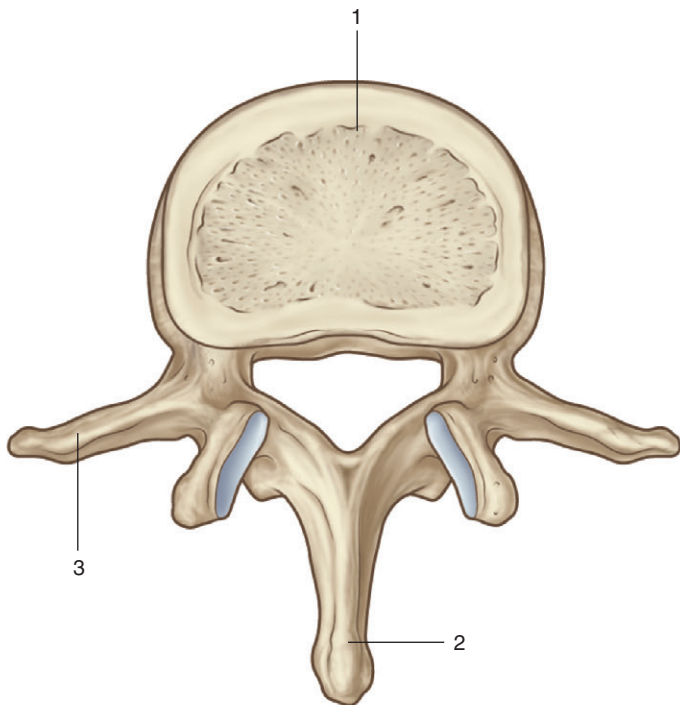
IN THE CLINIC:

- **Osteoporosis can result in collapse of the vertebral body.**

Figure from Gray's Anatomy for Students, 3rd edition, p. 143.

**SKELETAL FRAMEWORK:
VERTEBRA 3**

From which region of the vertebral column is this vertebra? Identify the indicated structures.



Superior view

SKELETAL FRAMEWORK: VERTEBRA 3



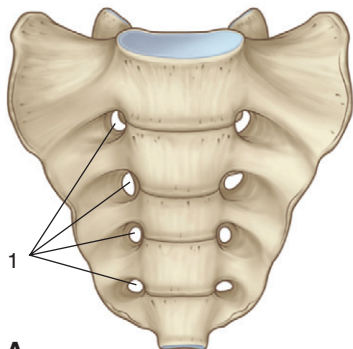
This vertebra is from the lumbar region.

1. Vertebral body
2. Spinous process
3. Transverse process

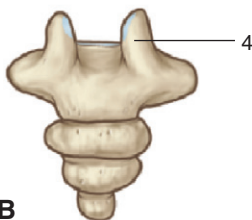
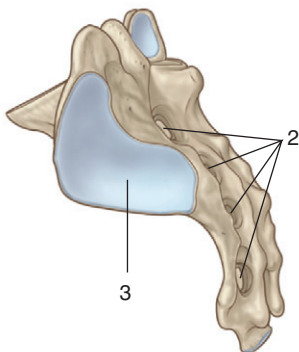
Figure from Gray's Anatomy for Students, 3rd edition, p. 70.



Identify A and B. Identify the indicated structures.



A



B

SKELETAL FRAMEWORK: SACRUM AND COCCYX



A. Sacrum

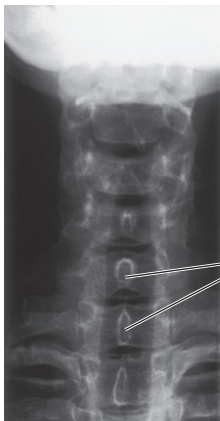
1. Anterior sacral foramina
2. Posterior sacral foramina
3. Facet for articulation with pelvic bone

B. Coccyx

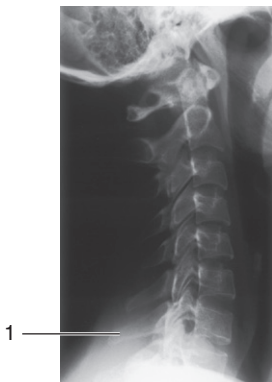4. Coccygeal cornu

Figure from Gray's Anatomy for Students, 3rd edition, p. 71.

Which region of the vertebral column is imaged in these radiographs? Identify the indicated structures.



Anterior-posterior view



Lateral view

SKELETAL FRAMEWORK: VERTEBRA RADIOGRAPH I

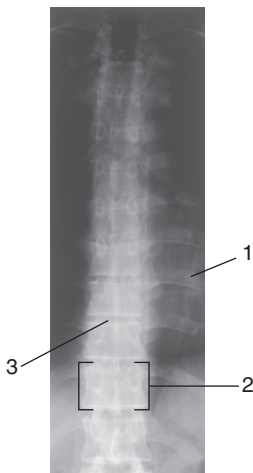


These radiographs show the cervical region.

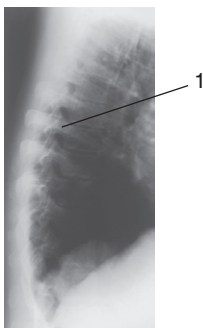
1. Spinous processes

Figure from Gray's Anatomy for Students, 3rd edition, p. 65.

Which region of the vertebral column is imaged in these radiographs? Identify the indicated structures.



Anterior-posterior view



Lateral view

SKELETAL FRAMEWORK: VERTEBRA RADIOGRAPH II

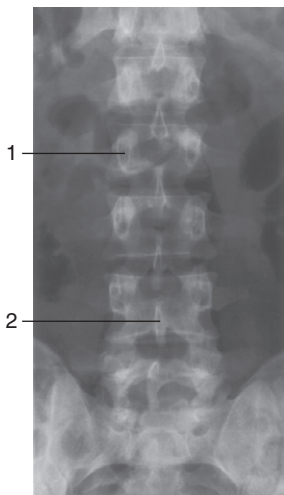


These radiographs show the thoracic region.

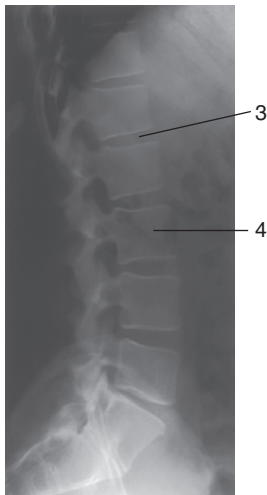
1. Rib
2. Body of thoracic vertebra
3. Location of intervertebral disc

Figure from Gray's Anatomy for Students, 3rd edition, p. 66.

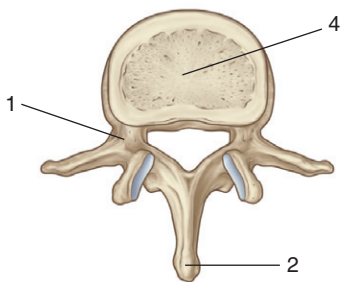
Which region of the vertebral column is imaged in these radiographs? Identify the indicated structures.



Anterior-posterior view



Lateral view



Superior view



SKELETAL FRAMEWORK: VERTEBRA RADIOGRAPH III

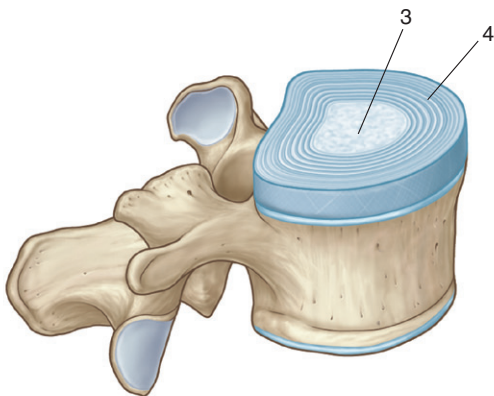
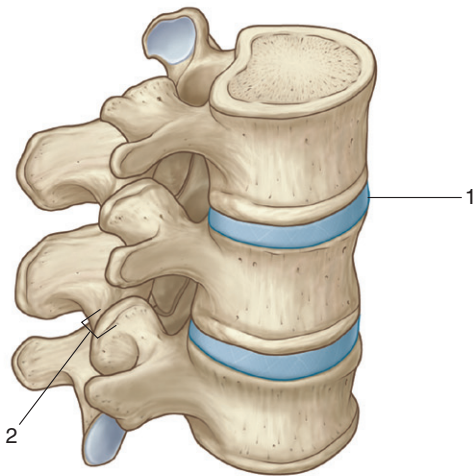


These radiographs show the lumbar region.

1. Pedicle
2. Spinous process
3. Intervertebral disc
4. Vertebral body

Figure from Gray's Anatomy for Students, 3rd edition, pp. 67-68.

Identify the indicated structures.



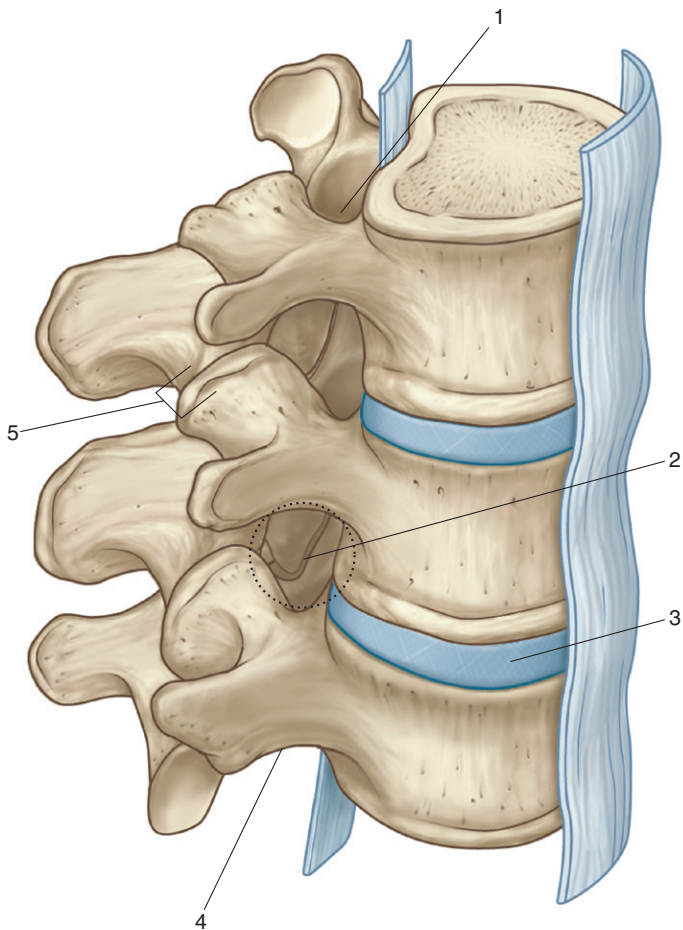
SKELETAL FRAMEWORK: INTERVERTEBRAL JOINTS



1. Intervertebral disc
2. Zygapophysial joint
3. Nucleus pulposus
4. Anulus fibrosus

Figure from Gray's Anatomy for Students, 3rd edition, p. 77 and 79.

Identify the indicated structures.





SKELETAL FRAMEWORK: INTERVERTEBRAL FORAMEN



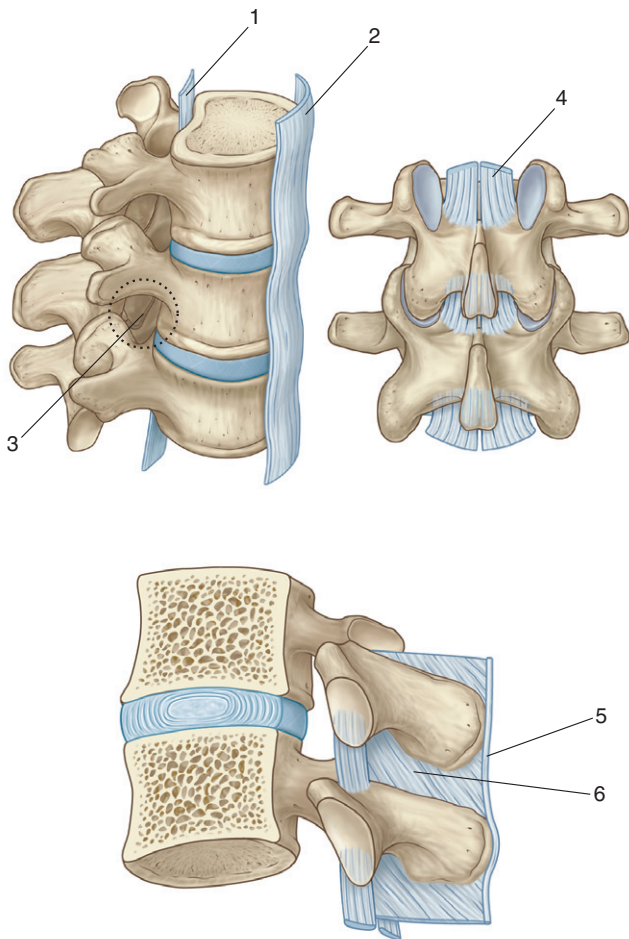
1. Superior vertebral notch
2. Intervertebral foramen
3. Intervertebral disc
4. Inferior vertebral notch
5. Zygapophysial joint

IN THE CLINIC:

- **The intervertebral foramen is surrounded by bone and joints. Passing through the foramen is a spinal nerve and vessels. Any pathology in structures forming the boundaries of the foramen can affect the spinal nerve.**

Figure from Gray's Anatomy for Students, 3rd edition, p. 80.

Identify the indicated structures.



SKELETAL FRAMEWORK: VERTEBRAL LIGAMENTS



1. Posterior longitudinal ligament
2. Anterior longitudinal ligament
3. Intervertebral foramen
4. Ligamentum flavum
5. Supraspinous ligament
6. Interspinous ligament

IN THE CLINIC:

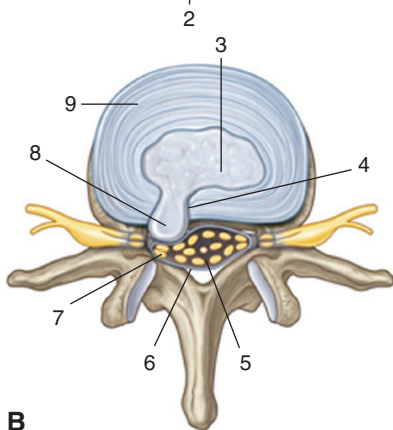
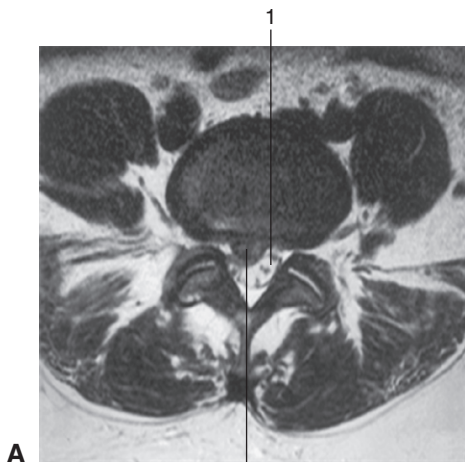
- **When doing a lumbar puncture in the midline, a needle passes through the supraspinous and interspinous ligaments into the vertebral canal.**
- **Spinal nerves pass through the intervertebral foramen. Any pathology that reduces the dimensions of the foramen can compress the nerve, causing motor and sensory deficits and pain.**

Figure from Gray's Anatomy for Students, 3rd edition, pp. 80-82.

**SKELETAL FRAMEWORK:
INTERVERTEBRAL DISC PROTRUSION**

22

Identify A and B. Identify the indicated structures.





SKELETAL FRAMEWORK: INTERVERTEBRAL DISC PROTRUSION



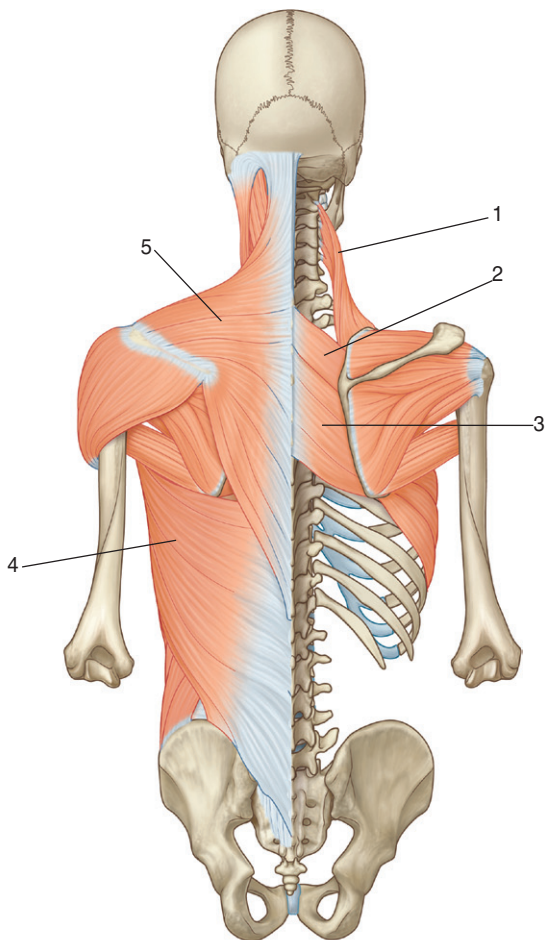
- A. Intervertebral disc protrusion in lower lumbar region of vertebral column
 - 1. Vertebral canal containing cerebrospinal fluid (CSF) and cauda equina
 - 2. Disc protrusion (herniated disc)
- B. Intervertebral disc protrusion (superior view)
 - 3. Nucleus pulposus
 - 4. Defect in anulus fibrosus
 - 5. Cauda equina
 - 6. Dura
 - 7. Compression of spinal nerve roots
 - 8. Herniation of nucleus pulposus
 - 9. Anulus fibrosus

IN THE CLINIC:

- **Herniation of the nucleus pulposus through a weakened anulus fibrosus can impinge on the spinal cord or spinal nerve.**

Figure from Gray's Atlas of Anatomy, 2nd edition, p. 33.

Identify the indicated muscles.



MUSCLES: SUPERFICIAL GROUP



1. Levator scapulae
2. Rhomboid minor
3. Rhomboid major
4. Latissimus dorsi
5. Trapezius

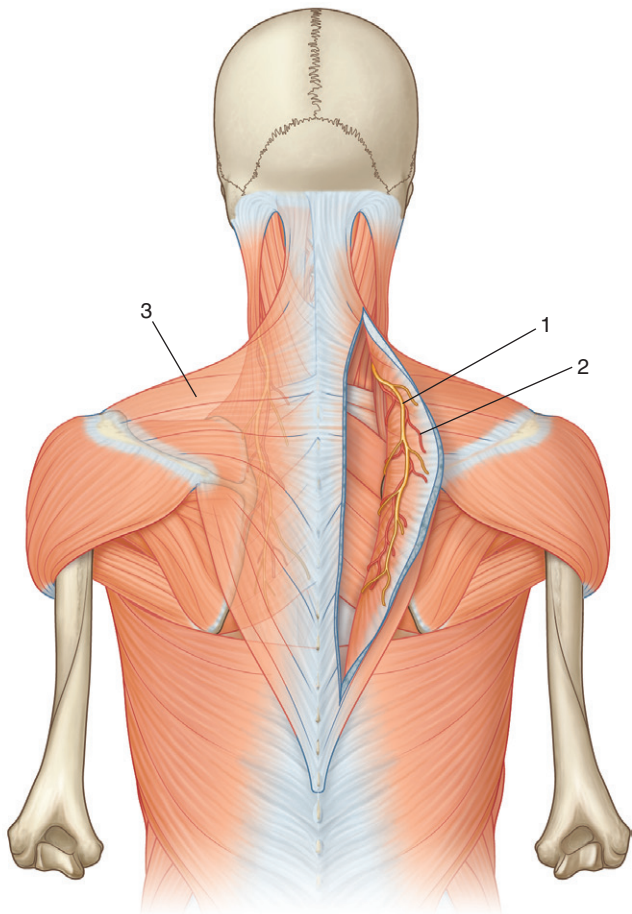
IN THE CLINIC:

- **The function of the trapezius muscle can be used to test cranial nerve XI (accessory nerve).**
- **The function of the levator scapulae, rhomboid major, and rhomboid minor muscles can be used to assess the status of the anterior rami of spinal nerves C3-C5 (levator scapulae, C3-C5; rhomboids, C4-C5).**

Figure from Gray's Anatomy for Students, 3rd edition, p. 86.

MUSCLES: TRAPEZIUS INNERVATION AND BLOOD SUPPLY

Identify the indicated structures.





MUSCLES: TRAPEZIUS INNERVATION AND BLOOD SUPPLY



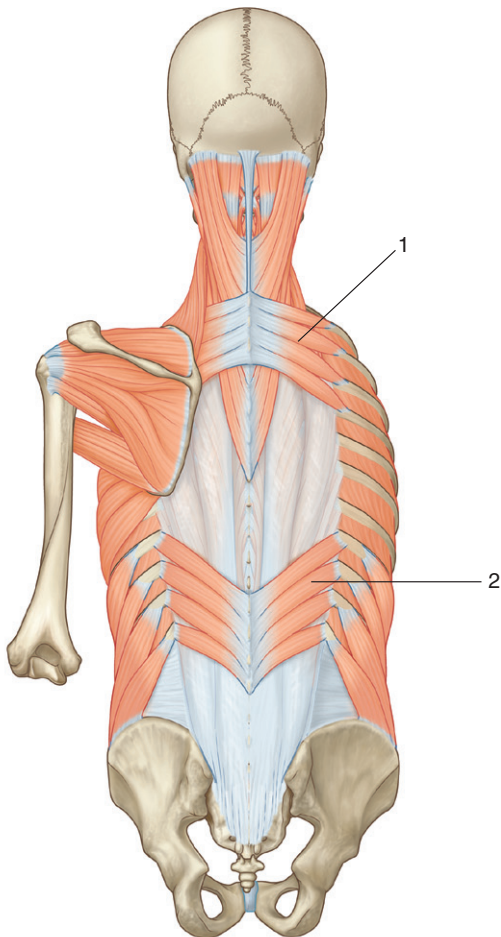
1. Accessory nerve (XI)
2. Superficial branch of transverse cervical artery
3. Trapezius muscle

IN THE CLINIC:

- **Loss of accessory nerve (XI) function results in loss of the ability to elevate the shoulder against resistance.**

Figure from Gray's Anatomy for Students, 3rd edition, p. 87.

Identify the indicated muscles.





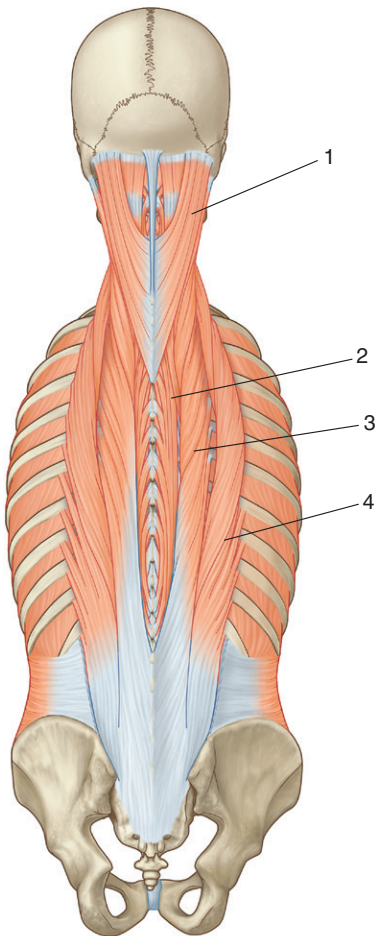
MUSCLES: INTERMEDIATE GROUP



1. Serratus posterior superior
2. Serratus posterior inferior

Figure from Gray's Anatomy for Students, 3rd edition, p. 91.

Identify the indicated muscles.



MUSCLES: ERECTOR SPINAE



1. Splenius capitis
2. Spinalis
3. Longissimus
4. Iliocostalis

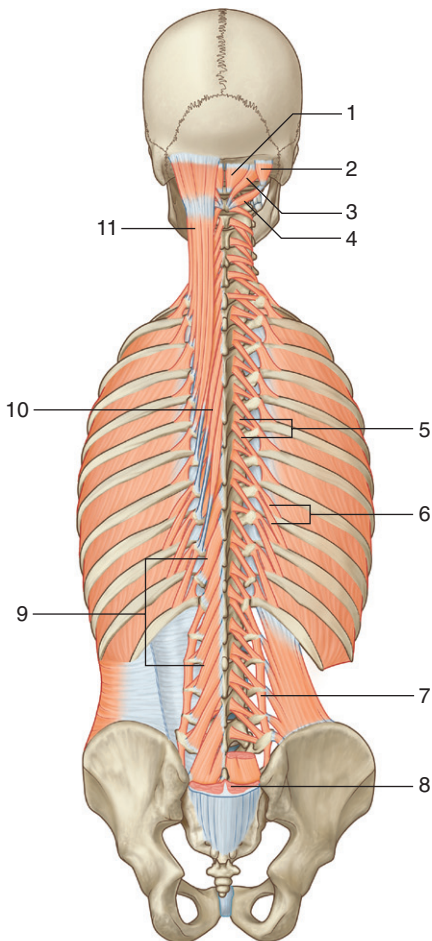
IN THE CLINIC:

- **The erector spinae muscles are postural muscles innervated by the posterior rami of spinal nerves. Pathology of function can lead to back pain and abnormal posture.**

Figure from Gray's Anatomy for Students, 3rd edition, p. 94.

MUSCLES: TRANSVERSOSPINALIS AND SEGMENTALS

Identify the indicated muscles.



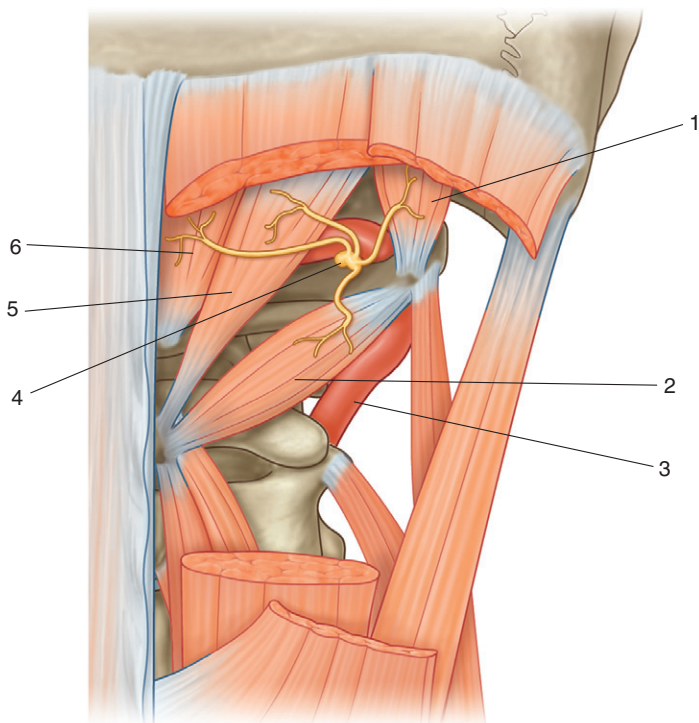
MUSCLES: TRANSVERSOSPINALIS AND SEGMENTALS



1. Rectus capitis posterior minor
2. Obliquus capitis superior
3. Rectus capitis posterior major
4. Obliquus capitis inferior
5. Rotatores thoracis (short, long)
6. Levatores costarum (short, long)
7. Intertransversarius
8. Erector spinae (cut)
9. Multifidus
10. Semispinalis thoracis
11. Semispinalis capitis

Figure from Gray's Anatomy for Students, 3rd edition, p. 96.

Identify the indicated structures.



MUSCLES: SUBOCCIPITAL REGION

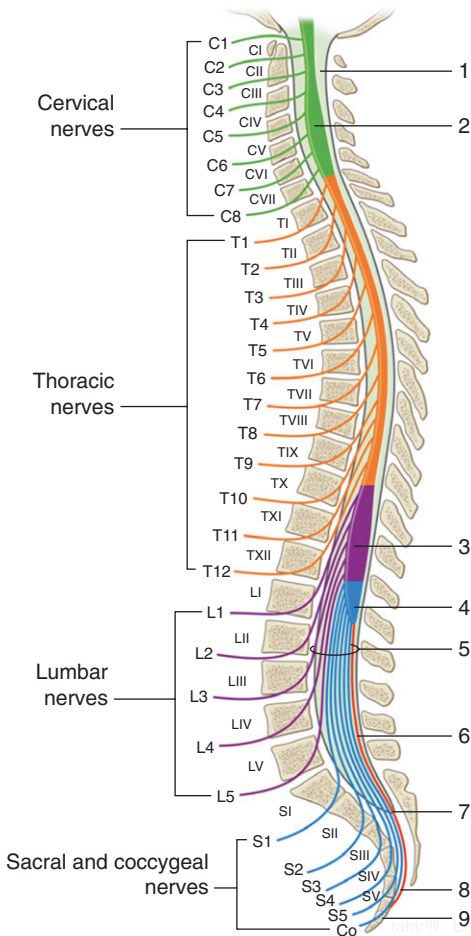
1. Obliquus capitis superior muscle
2. Obliquus capitis inferior muscle
3. Vertebral artery
4. Posterior ramus of C1
5. Rectus capitis posterior major muscle
6. Rectus capitis posterior minor muscle

IN THE CLINIC:

- The vertebral artery and the posterior ramus of C1 are located in the suboccipital triangle formed by the obliquus capitis superior muscle, rectus capitis posterior major muscle, and obliquus capitis inferior muscle. The suboccipital triangle can be used to access the vertebral artery.

Figure from Gray's Anatomy for Students, 3rd edition, p. 98.

Identify the indicated structures.



SPINAL CORD



Relation of spinal nerve roots to vertebrae.

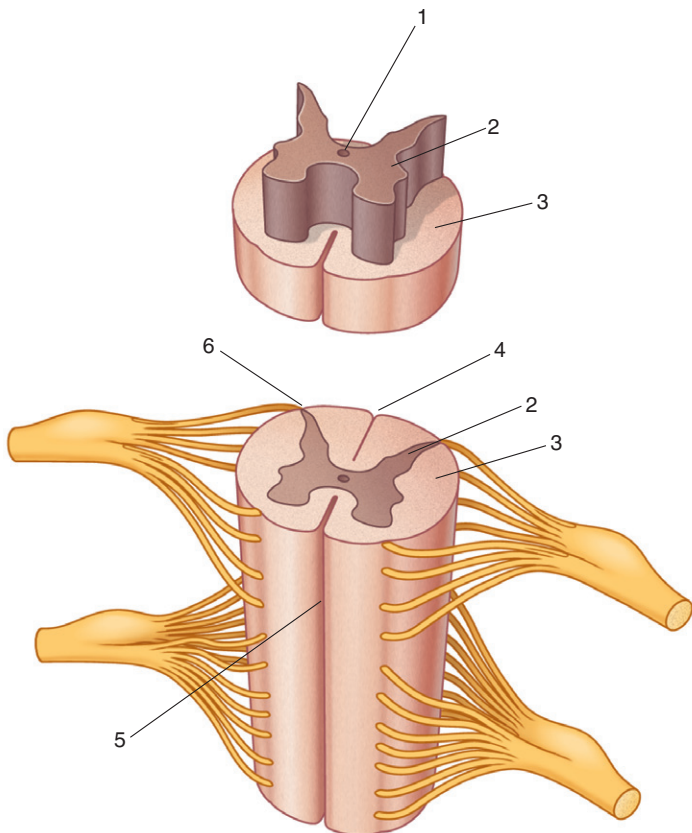
1. Subarachnoid space
2. Cervical enlargement (of spinal cord)
3. Lumbosacral enlargement (of spinal cord)
4. Conus medullaris
5. Cauda equina
6. Filum terminale (pial part)
7. End of dural/arachnoid sac
8. Filum terminale (dural part)
9. Coccyx

IN THE CLINIC:

- **The subarachnoid space can safely be accessed with a needle below the end of the spinal cord. This is normally done in the lower lumbar region.**

Figure from Gray's Atlas of Anatomy, 2nd edition, p. 44.

Identify the indicated structures or regions.



SPINAL CORD DETAILS

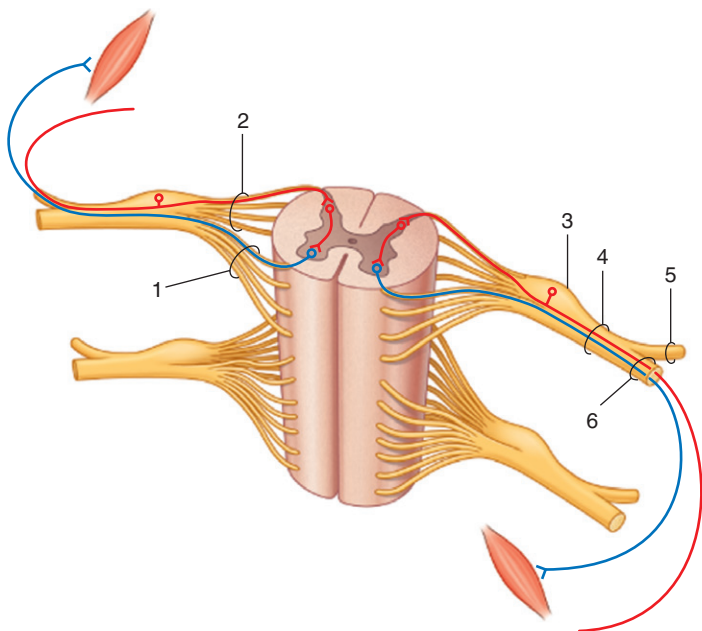
1. Central canal
2. Gray matter
3. White matter
4. Posterior median sulcus
5. Anterior median fissure
6. Posterolateral sulcus

IN THE CLINIC:

- **Lesions in either the white or gray matter of the spinal cord can result in neurological deficits.**

Figure from Gray's Anatomy for Students, 3rd edition, p. 100.

Identify the indicated structures.



SPINAL NERVES



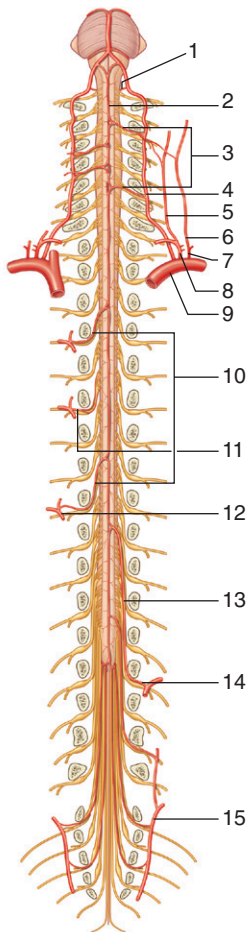
1. Anterior root
2. Posterior root
3. Spinal ganglion
4. Spinal nerve
5. Posterior ramus
6. Anterior ramus

IN THE CLINIC:

- A lesion in the posterior root of a spinal nerve results in loss of all sensory input to that spinal level from the spinal nerve. A lesion in the anterior root of a spinal nerve results in loss of all motor output from the spinal cord in that spinal nerve.
- Sensory fibers enter the spinal cord posteriorly. Motor fibers leave the spinal cord anteriorly.
- All somatic plexuses in the body are formed by anterior rami of spinal nerves.

Figure from Gray's Anatomy for Students, 3rd edition, p. 107.

Identify the indicated arteries.



SPINAL CORD ARTERIES



Arteries that supply the spinal cord (anterior view).

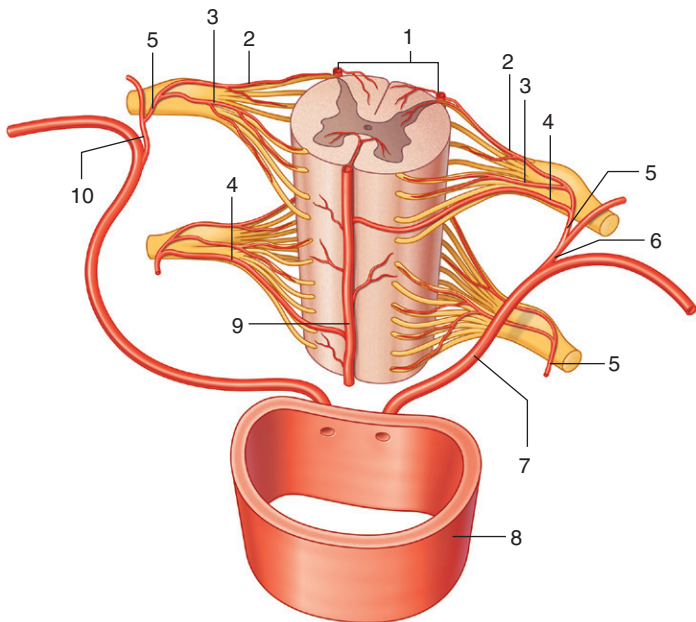
1. Posterior spinal artery
2. Anterior spinal artery
3. Segmental medullary arteries
4. Vertebral artery
5. Ascending cervical artery
6. Deep cervical artery
7. Costocervical trunk
8. Thyrocervical trunk
9. Subclavian artery
10. Segmental medullary arteries (branch from segmental spinal artery)
11. Segmental spinal artery
12. Posterior intercostal artery
13. Artery of Adamkiewicz (branch from segmental spinal artery)
14. Segmental spinal artery
15. Lateral sacral artery

IN THE CLINIC:

- **Loss of function of the artery of Adamkiewicz can lead to loss of function of the inferior aspect of the spinal cord.**

Figure from Gray's Atlas of Anatomy, 2nd edition, p. 46.

Identify the indicated arteries.





SPINAL CORD ARTERIES DETAIL



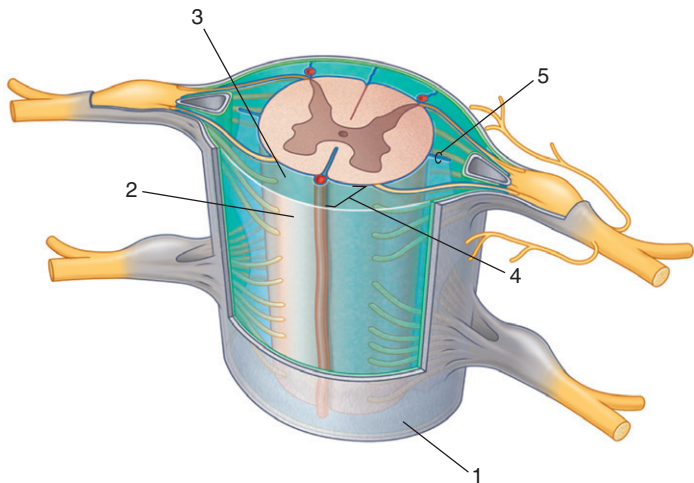
1. Posterior spinal arteries
2. Posterior radicular artery
3. Anterior radicular artery
4. Segmental medullary artery
5. Segmental spinal artery
6. Posterior branch of left posterior intercostal artery
7. Left posterior intercostal artery
8. Aorta
9. Anterior spinal artery
10. Posterior branch of right posterior intercostal artery

IN THE CLINIC:

- **Loss of segmental blood supply to the spinal cord can result in neurological deficit.**

Figure from Gray's Anatomy for Students, 3rd edition, p. 101.

Identify the indicated structures.



SPINAL CORD MENINGES



1. Dura mater
2. Arachnoid mater
3. Pia mater
4. Subarachnoid space
5. Denticulate ligament

IN THE CLINIC:



- **Cerebrospinal fluid (CSF) is located in and can be extracted from the subarachnoid space.**

Figure from Gray's Anatomy for Students, 3rd edition, p. 103.

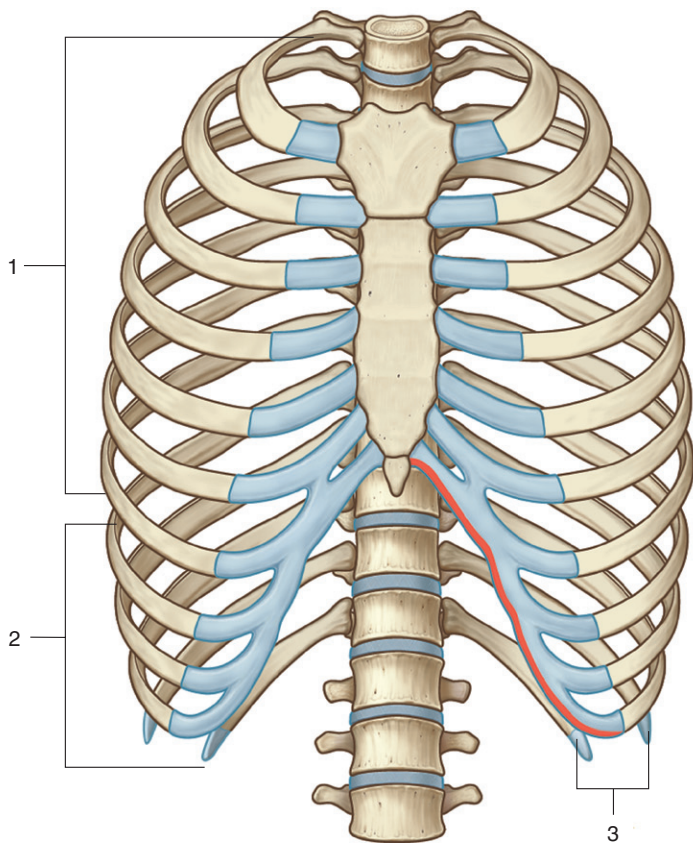


SECTION 3: THORAX

35. Thoracic Skeleton
36. Typical Rib
37. Rib I Superior Surface
38. Sternum
39. Vertebra, Ribs, and Sternum
40. Thoracic Wall
41. Thoracic Cavity
42. Intercostal Space with Nerves and Vessels
43. Pleural Cavity
44. Pleura
45. Parietal Pleura
46. Right Lung
47. Left Lung
48. CT: Left Pulmonary Artery
49. CT: Right Pulmonary Artery
50. Mediastinum: Subdivisions
51. Pericardium
52. Pericardial Sinuses
53. Anterior Surface of the Heart
54. Diaphragmatic Surface and Base of the Heart
55. Right Atrium
56. Right Ventricle
57. Left Atrium
58. Left Ventricle
59. Plain Chest Radiograph
60. MRI: Chambers of the Heart
61. Coronary Arteries
62. Coronary Veins
63. Conduction System
64. Superior Mediastinum
65. Superior Mediastinum: Cross Section
66. Superior Mediastinum: Great Vessels

- 
- 
67. Superior Mediastinum: Trachea and Esophagus
 68. Mediastinum: Right Lateral View
 69. Mediastinum: Left Lateral View
 70. Posterior Mediastinum
 71. Normal Esophageal Constrictions and Esophageal Plexus
 72. Thoracic Aorta and Branches
 73. Azygos System of Veins and Thoracic Duct
 74. Thoracic Sympathetic Trunks and Splanchnic Nerves

Identify the types of ribs.



THORACIC SKELETON



1. True ribs I to VII
2. False ribs VIII to XII
3. Floating ribs XI and XII

IN THE CLINIC:

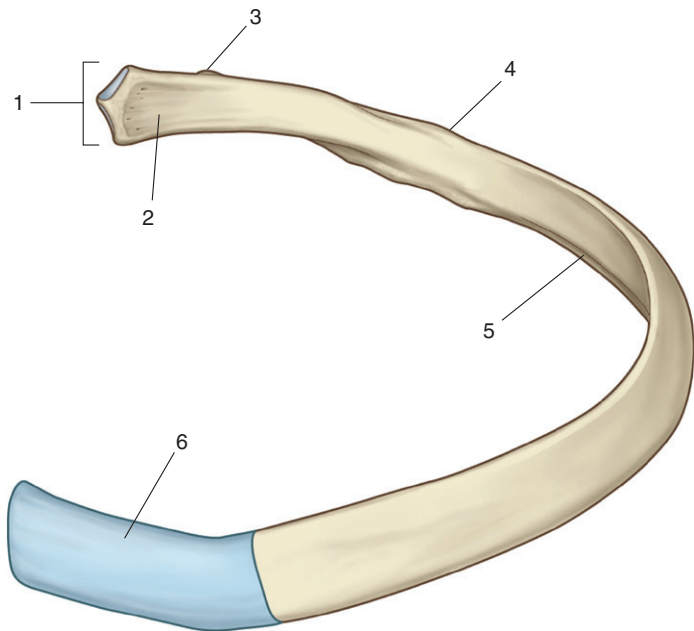
- The upper seven pairs of ribs are the true ribs because their costal cartilages articulate directly with the sternum. The remaining ribs are false ribs because they either articulate anteriorly with the costal cartilages of the ribs above, or do not articulate anteriorly at all. The latter two pairs of false ribs (ribs XI and XII) are often called floating ribs.

Figure from Gray's Anatomy for Students, 3rd edition, p. 145.



TYPICAL RIB

Identify the indicated parts of a rib.



TYPICAL RIB



1. Head
2. Neck
3. Tubercle
4. Angle
5. Costal groove
6. Costal cartilage

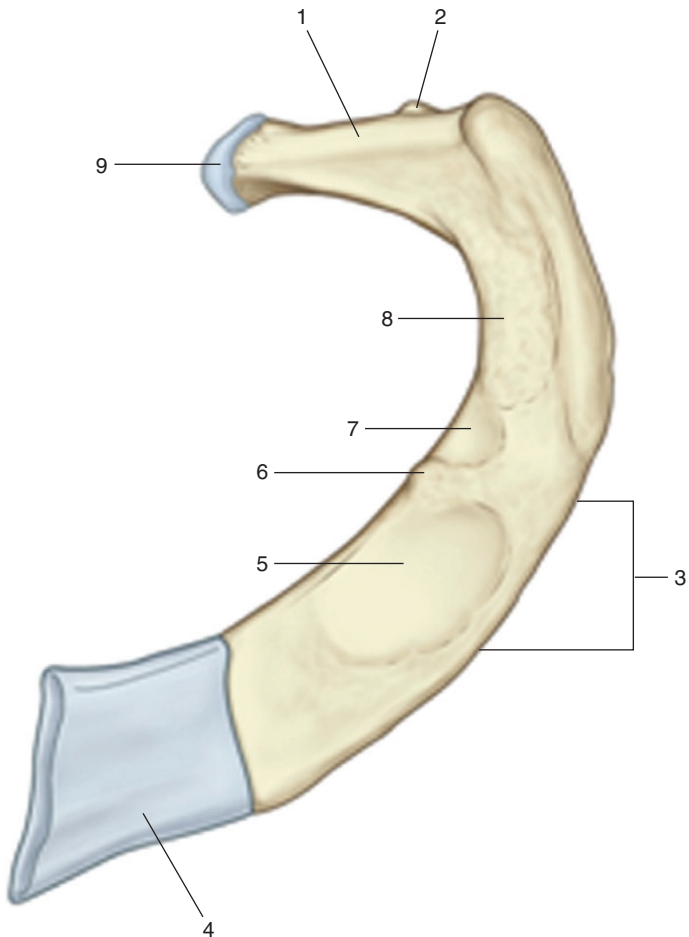
IN THE CLINIC:

- **A rib fracture can tear the underlying parietal pleura. This could allow air to enter the pleural cavity, causing a pneumothorax. When this occurs, the lung collapses as a result of its own elastic recoil.**

Figure from Gray's Anatomy for Students, 3rd edition, p. 145.



Identify the indicated parts of Rib I.



RIB I SUPERIOR SURFACE



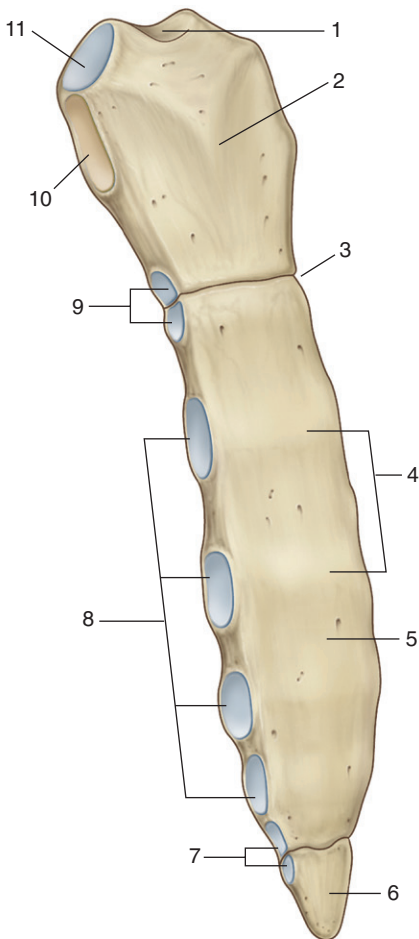
1. Neck
2. Tubercle
3. Area for attachment of serratus anterior
4. Costal cartilage
5. Groove for subclavian vein
6. Scalene tubercle (attachment of anterior scalene)
7. Groove for subclavian artery
8. Area for attachment of middle scalene
9. Head with articular facet

Figure from Gray's Atlas of Anatomy, 2nd edition, p. 65.



STERNUM

Identify the indicated parts of the sternum.



STERNUM



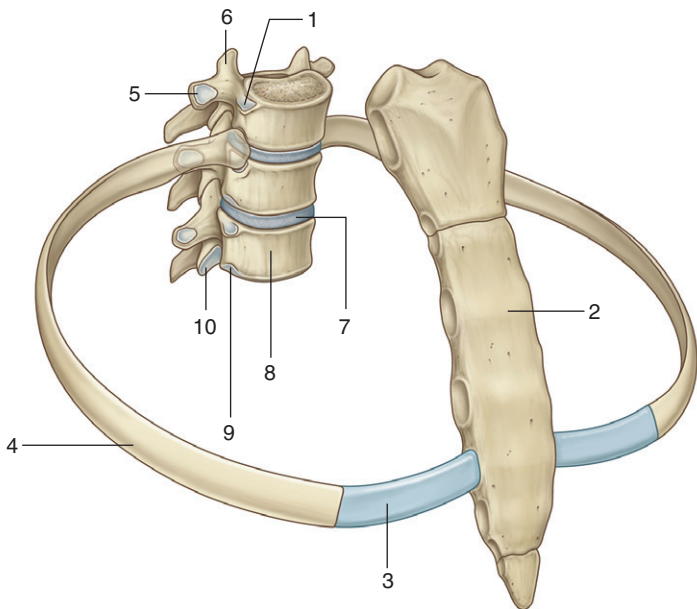
1. Jugular notch
2. Manubrium of sternum
3. Sternal angle (manubriosternal joint)
4. Transverse ridges
5. Body of sternum
6. Xiphoid process
7. Articular facets for rib VII
8. Articular facets for ribs III-VI
9. Articular demifacets for rib II
10. Attachment site for rib I
11. Articular site for clavicle

IN THE CLINIC:

- **The manubriosternal joint can be easily palpated because the manubrium normally angles posteriorly on the body of the sternum, forming a raised feature, the sternal angle. This elevation marks the articulation of rib II with the sternum. This is used as a reference point for counting ribs.**

Figure from Gray's Anatomy for Students, 3rd edition, p. 147.

Identify the indicated structures.



VERTEBRA, RIBS, AND STERNUM



1. Superior costal facet
2. Body of sternum
3. Costal cartilage
4. Rib V
5. Costal facet on transverse process
6. Superior articular process
7. Intervertebral disc
8. Vertebral body
9. Inferior costal facet
10. Inferior articular process

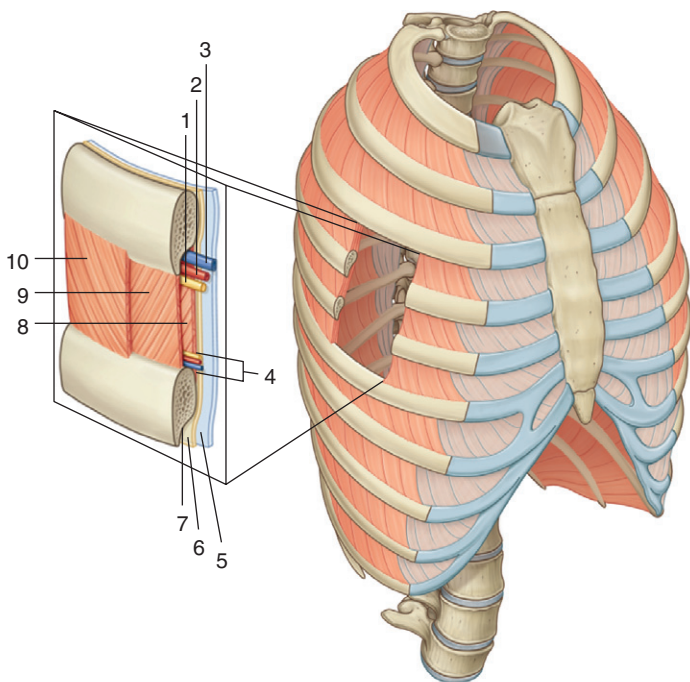
IN THE CLINIC:

- **Because of the unique articulations between the ribs, vertebrae, and sternum, elevation and depression of the ribs changes the anteroposterior and lateral dimensions of the thorax. The anterior ends of the ribs are inferior to the posterior ends. When the ribs are elevated, they move the sternum upward and forward. When the ribs are depressed, the sternum moves downward and backward. This pump-handle type of movement changes the anteroposterior dimensions of the thorax. Because the midshaft of each rib tends to be lower than the two ends, when the shafts are elevated the middle portion moves laterally. This bucket-handle movement changes the lateral dimensions of the thorax.**

Figure from Gray's Anatomy for Students, 3rd edition, p. 125.



Identify the indicated structures in an intercostal space.



THORACIC WALL



1. Intercostal nerve
2. Intercostal artery
3. Intercostal vein
4. Collateral branches
5. Parietal pleura
6. Endothoracic fascia
7. Costal groove
8. Innermost intercostal muscle
9. Internal intercostal muscle
10. External intercostal muscle

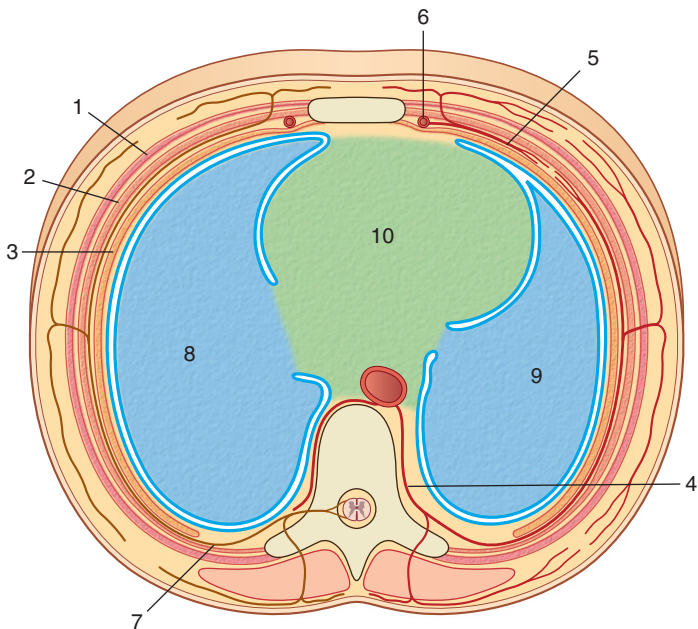
IN THE CLINIC:

- **The muscles in the thoracic wall alter the position of the ribs and sternum, changing the thoracic volume during breathing. They also provide structural support to the thoracic wall during breathing.**

Figure from Gray's Atlas of Anatomy, 2nd edition, p. 72.



Identify the indicated structures.



THORACIC CAVITY



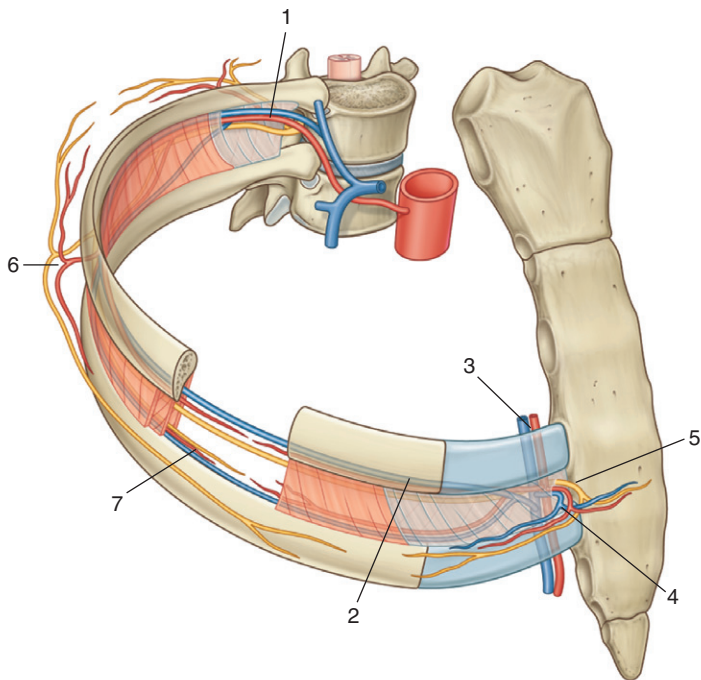
1. External intercostal muscle
2. Internal intercostal muscle
3. Innermost intercostal muscle
4. Posterior intercostal artery
5. Anterior intercostal artery
6. Internal thoracic artery
7. Anterior ramus of spinal nerve (intercostal nerve)
8. Right lung
9. Left lung
10. Mediastinum

IN THE CLINIC:

- The thoracic cavity is subdivided into left and right pleural cavities, each surrounding a lung, and the mediastinum. Therefore, problems in one pleural cavity do not necessarily affect the other cavity. Also, the mediastinum can be entered surgically without opening the pleural cavities.

Figure from Gray's Anatomy for Students, 3rd edition, p. 152.

*Identify the indicated structures
in an intercostal space.*



INTERCOSTAL SPACE WITH NERVES AND VESSELS



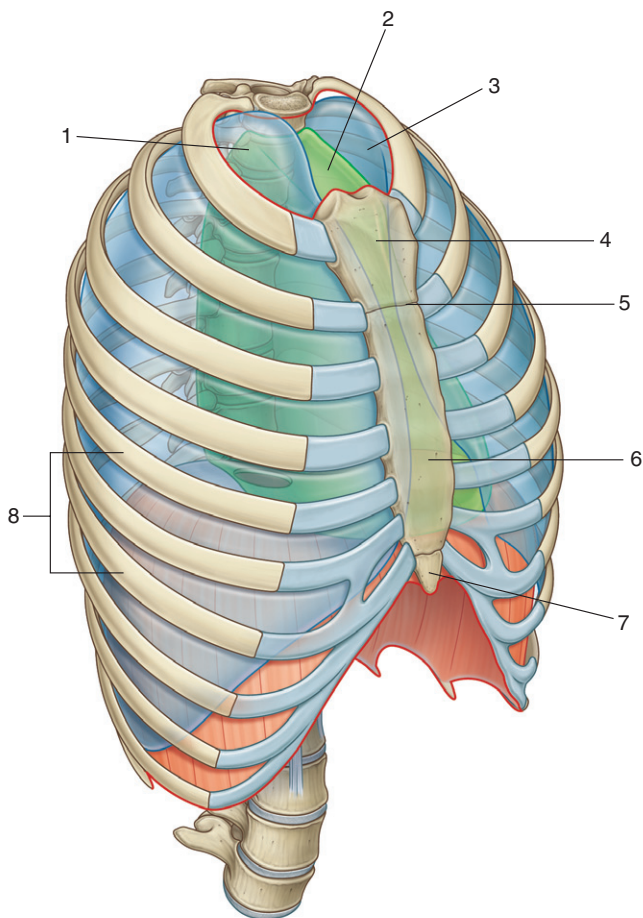
1. Posterior intercostal artery and vein
2. Anterior intercostal artery and vein
3. Internal thoracic artery and vein
4. Anterior perforating branches of intercostal vessels
5. Anterior cutaneous branch of intercostal nerve
6. Lateral branches of intercostal nerve and vessels
7. Collateral branches of intercostal nerve and vessels

IN THE CLINIC:

- **To remove air from the pleural cavity a tube must be inserted. The tube is inserted over the superior aspect of the rib because insertion at the inferior border of the rib could injure the intercostal vein, artery, and nerve lying in the costal groove.**

Figure from Gray's Anatomy for Students, 3rd edition, p. 151.

Identify the labeled parts of the thoracic wall and cavity.



PLEURAL CAVITY



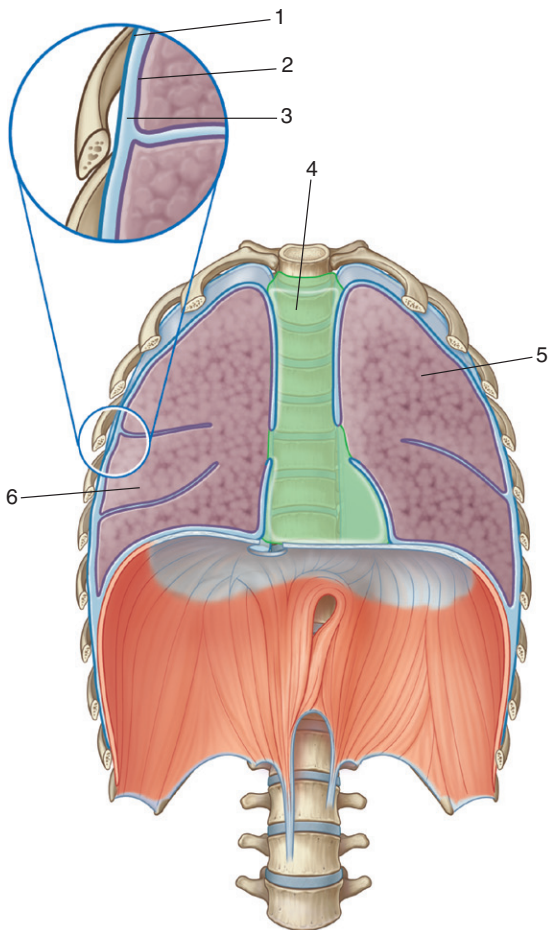
1. Right pleural cavity
2. Mediastinum
3. Left pleural cavity
4. Manubrium of sternum
5. Sternal angle
6. Body of sternum
7. Xiphoid process
8. Ribs

IN THE CLINIC:

- **The pleural cavities extend above rib I into the root of the neck. Trauma or injury to the root of the neck can involve the superior extension of the pleura. Conversely, pathologic processes in the superior extension of the pleura can involve the root of the neck.**

Figure from Gray's Anatomy for Students, 3rd edition, p. 123.

Identify the indicated structures.





1. Parietal pleura
2. Visceral pleura
3. Pleural cavity
4. Mediastinum
5. Left lung
6. Right lung

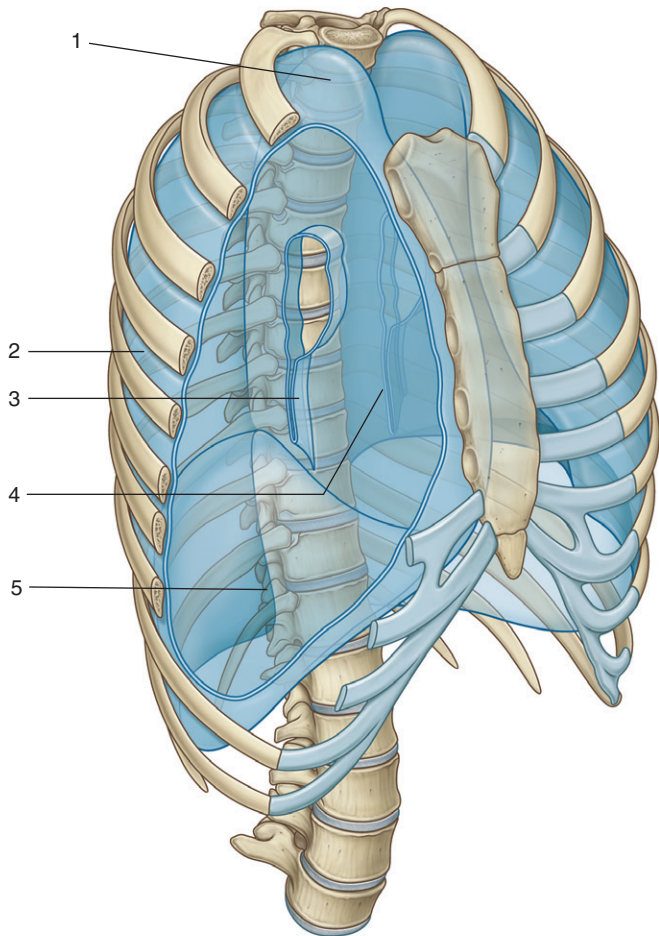
IN THE CLINIC:

- Each pleural cavity is a potential space enclosed between the visceral and parietal pleurae. They normally contain only a very thin layer of serous fluid (approximately 15 mL). The surface of the lung is covered by visceral pleura, which directly opposes and freely slides over the parietal pleura attached to the thoracic wall.

Figure from Gray's Anatomy for Students, 3rd edition, p. 163.



Identify the indicated parts of the parietal pleura.



PARIETAL PLEURA



1. Cervical pleura
2. Costal part
3. Pulmonary ligament
4. Mediastinal part
5. Diaphragmatic part

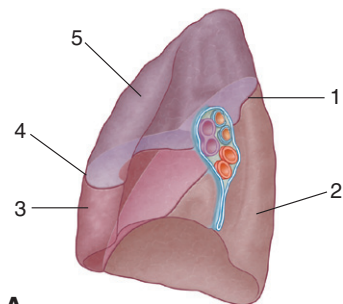
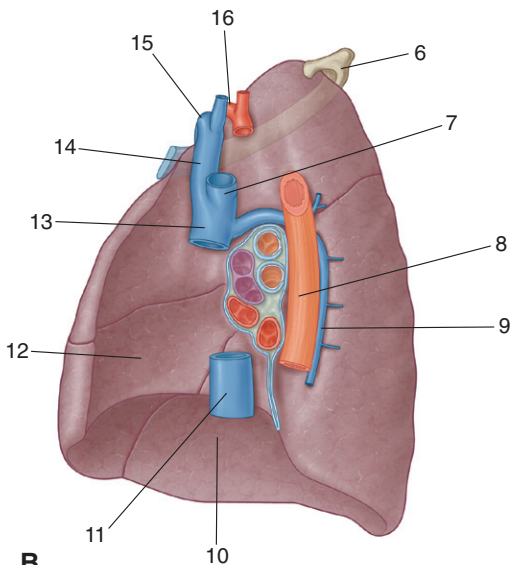
IN THE CLINIC:

- **The parietal pleura is innervated by general somatic afferent (GSA) fibers and is very sensitive to painful stimuli, such as the insertion of a chest tube. The visceral pleura is innervated by general visceral afferent (GVA) fibers and is relatively insensitive to painful stimuli.**

Figure from Gray's Anatomy for Students, 3rd edition, p. 164.



Identify the indicated parts of the right lung in A and structures related to the right lung in B.

**A****B**

RIGHT LUNG



1. Oblique fissure
2. Inferior lobe
3. Middle lobe
4. Horizontal fissure
5. Superior lobe
6. Rib I
7. Left brachiocephalic vein
8. Esophagus
9. Azygos vein
10. Diaphragm
11. Inferior vena cava
12. Heart
13. Superior vena cava
14. Right brachiocephalic vein
15. Subclavian vein
16. Subclavian artery

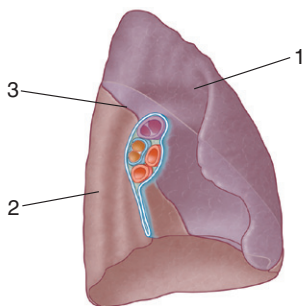
IN THE CLINIC:

- The largest surface of the superior lobe is in contact with the upper part of the anterolateral wall, and its apex projects into the root of the neck. The surface of the middle lobe lies mainly adjacent to the lower anterior and lateral walls. The costal surface of the inferior lobe is in contact with the posterior and inferior walls. When listening to breath sounds from each of the lobes, the stethoscope must be positioned on the areas of the thoracic wall related to the specific underlying lobe.

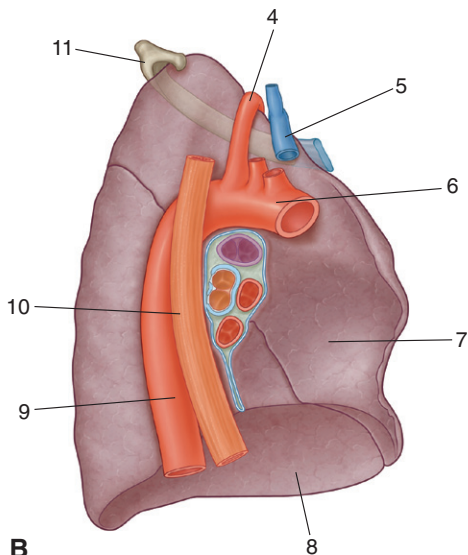
Figure from Gray's Anatomy for Students, 3rd edition, p. 170.



Identify the indicated parts of the left lung in A and structures related to the left lung in B.



A



B

LEFT LUNG



1. Superior lobe
2. Inferior lobe
3. Oblique fissure
4. Left subclavian artery
5. Left brachiocephalic vein
6. Aortic arch
7. Heart
8. Diaphragm
9. Thoracic aorta
10. Esophagus
11. Rib I

IN THE CLINIC:

- **The largest surface of the superior lobe is in contact with the upper part of the anterolateral wall, and the apex of this lobe projects into the root of the neck. The costal surface of the inferior lobe is in contact with the posterior and inferior walls. When listening to breath sounds from each of the lobes, the stethoscope must be positioned on the areas of the thoracic wall related to the specific underlying lobe.**

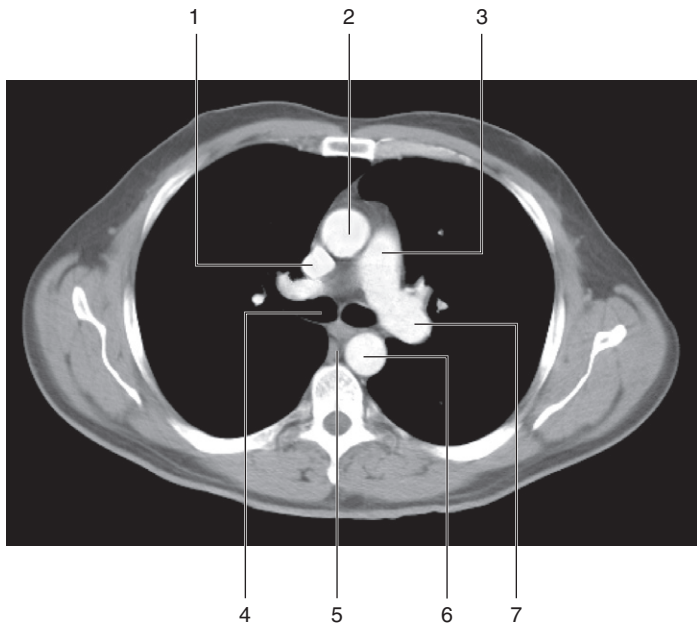
Figure from Gray's Anatomy for Students, 3rd edition, p. 171.



CT: LEFT PULMONARY ARTERY

48

Identify the indicated structures.



CT: LEFT PULMONARY ARTERY



1. Superior vena cava
2. Ascending aorta
3. Pulmonary trunk
4. Right main bronchus
5. Esophagus
6. Thoracic aorta
7. Left pulmonary artery

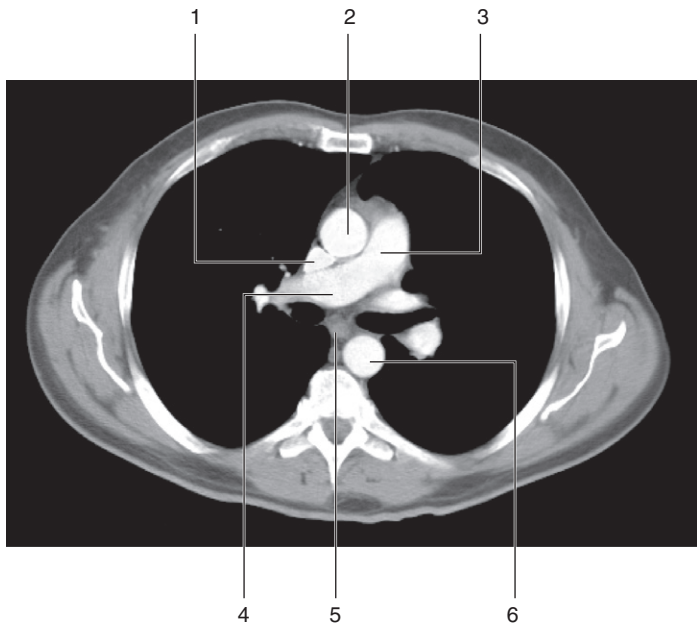
Figure from Gray's Basic Anatomy, p. 88.



CT: RIGHT PULMONARY ARTERY

49

Identify the indicated structures.



CT: RIGHT PULMONARY ARTERY

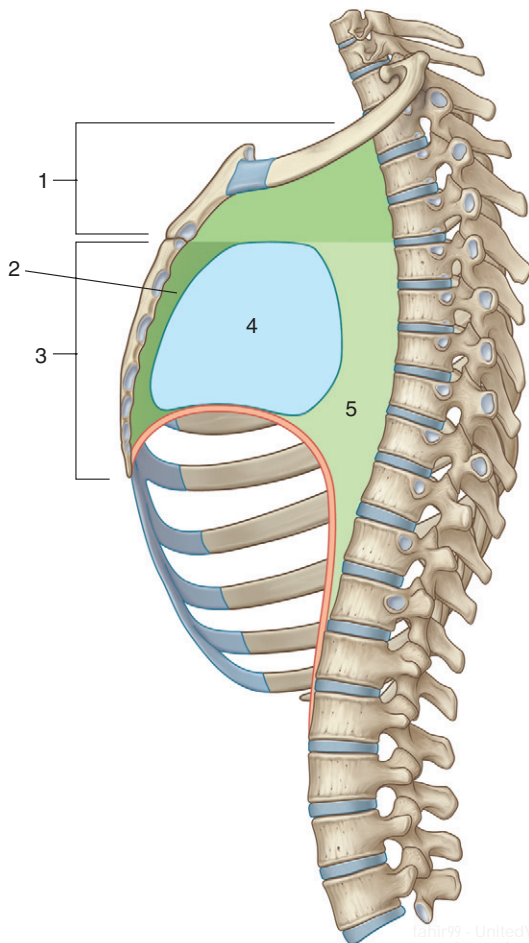


1. Superior vena cava
2. Ascending aorta
3. Pulmonary trunk
4. Right pulmonary artery
5. Esophagus
6. Thoracic aorta

Figure from Gray's Basic Anatomy, p. 88.



Identify the indicated parts of the mediastinum.



MEDIASTINUM: SUBDIVISIONS



1. Superior mediastinum
2. Anterior mediastinum
3. Inferior mediastinum
4. Middle mediastinum
5. Posterior mediastinum

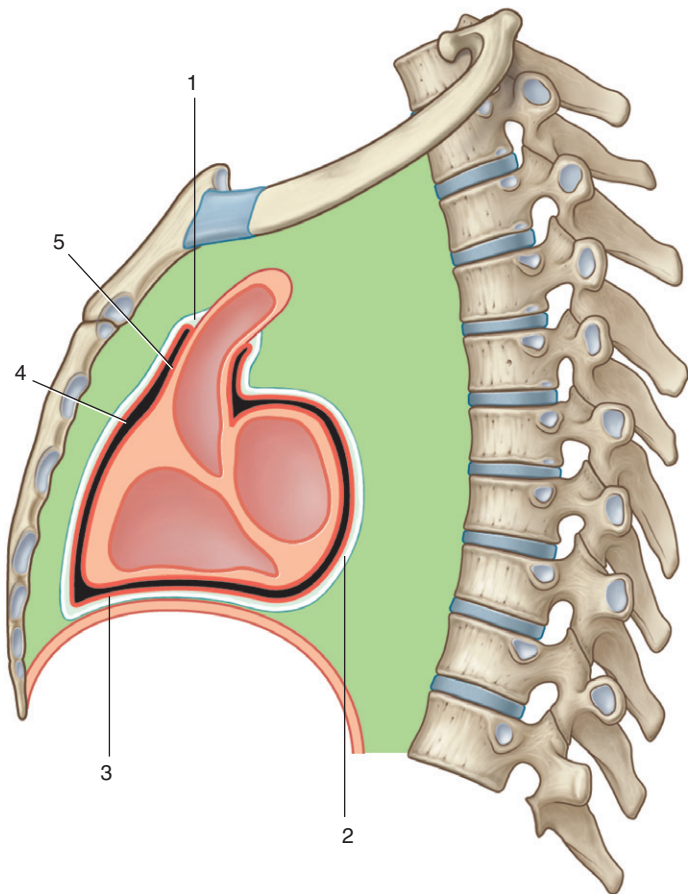
IN THE CLINIC:

- The mediastinum is subdivided into several smaller regions. A transverse plane extending from the sternal angle (the junction between the manubrium and the body of the sternum) to the intervertebral disc between vertebrae TIV and TV separates the mediastinum into the superior mediastinum and the inferior mediastinum, which is further partitioned into the anterior, middle, and posterior mediastinum by the pericardial sac.

Figure from Gray's Anatomy for Students, 3rd edition, p. 181.



Identify the indicated components of the pericardium.



PERICARDIUM



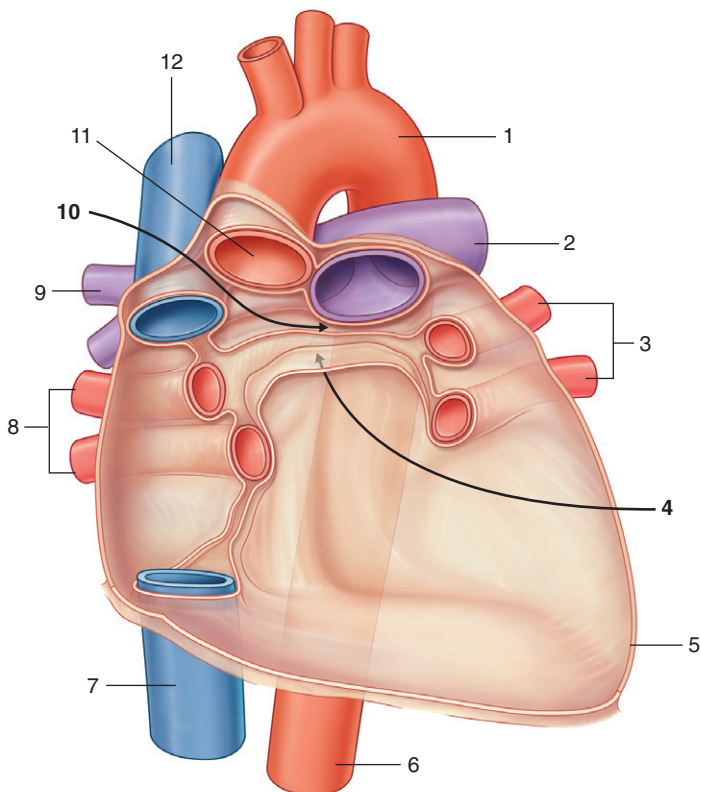
1. Junction between fibrous pericardium and adventitia of great vessels
2. Fibrous pericardium
3. Parietal layer of serous pericardium
4. Pericardial cavity
5. Visceral layer of serous pericardium (epicardium)

IN THE CLINIC:

- **The fibrous pericardium is a relatively fixed structure that cannot expand easily. A rapid accumulation of excess fluid within the pericardial sac can compress the heart and is known as cardiac tamponade.**

Figure from Gray's Anatomy for Students, 3rd edition, p. 181.

Identify the indicated pericardial sinuses and associated structures.



PERICARDIAL SINUSES



1. Arch of aorta
2. Left pulmonary artery
3. Left pulmonary veins
4. Oblique pericardial sinus (formed by reflection onto the pulmonary veins of heart)
5. Cut edge of pericardium
6. Thoracic aorta
7. Inferior vena cava
8. Right pulmonary veins
9. Branch of right pulmonary artery
10. Transverse pericardial sinus (separates arteries from veins)
11. Ascending aorta
12. Superior vena cava

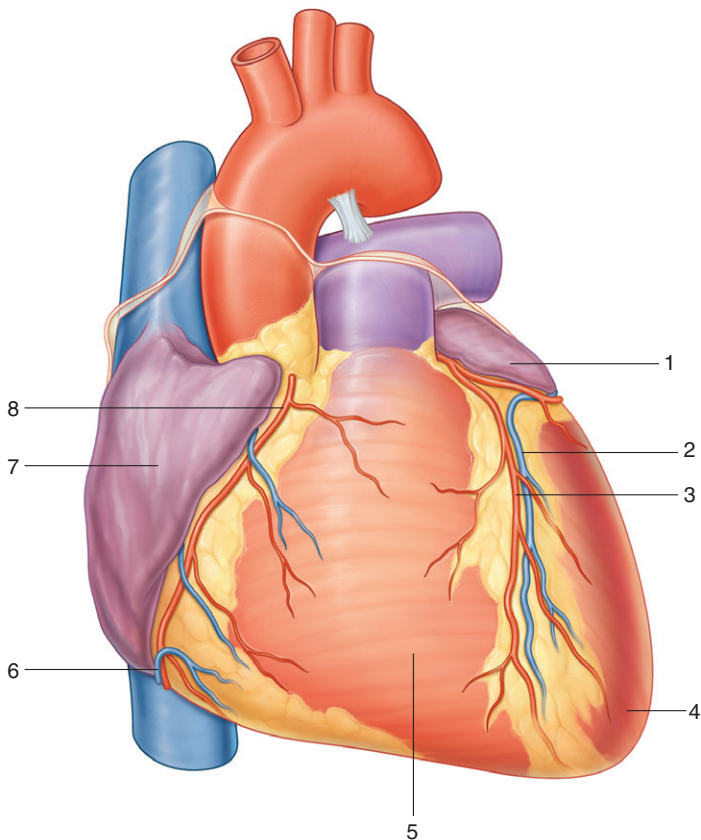
IN THE CLINIC:

- **Pericarditis is an inflammatory condition of the pericardium. Common causes are viral and bacterial infections and systemic illnesses, and it may occur after myocardial infarction. Abnormal thickening of the pericardial sac (constrictive pericarditis) can compress the heart, impairing heart function and resulting in heart failure.**

Figure from Gray's Anatomy for Students, 3rd edition, p. 183.



Identify the indicated structures on the anterior surface of the heart.





ANTERIOR SURFACE OF THE HEART



1. Left auricle
2. Great cardiac vein
3. Anterior interventricular branch of left coronary artery
4. Left ventricle
5. Right ventricle
6. Small cardiac vein
7. Right atrium
8. Right coronary artery

IN THE CLINIC:

- **The anterior cardiac surface lies posterior to the sternum and consists mostly of the right ventricle with some of the right atrium on the right and some of the left ventricle on the left.**

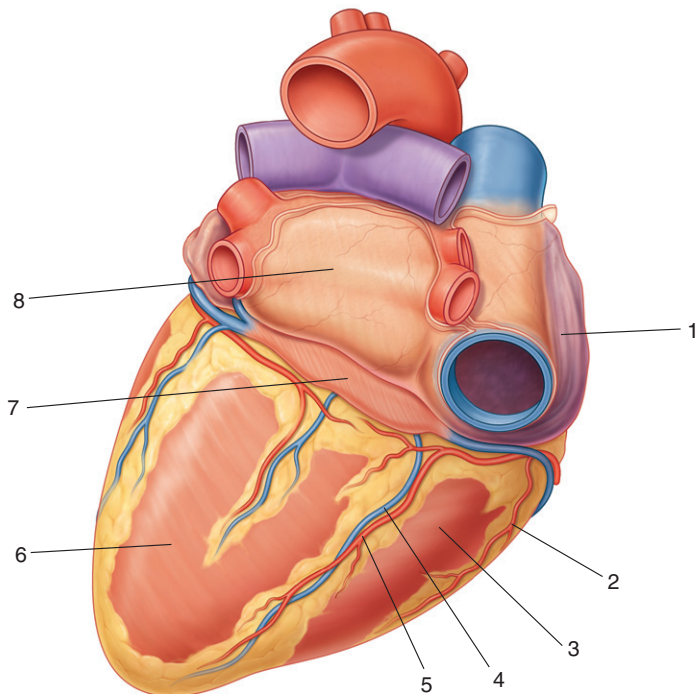
Figure from Gray's Anatomy for Students, 3rd edition, p. 186.



DIAPHRAGMATIC SURFACE AND BASE OF THE HEART

54

Identify the indicated structures on the diaphragmatic surface and base of the heart.



DIAPHRAGMATIC SURFACE AND BASE OF THE HEART



1. Right atrium
2. Marginal branch of right coronary artery
3. Right ventricle
4. Middle cardiac vein
5. Posterior interventricular branch of right coronary artery
6. Left ventricle
7. Coronary sinus
8. Left atrium

IN THE CLINIC:

- **The diaphragmatic surface faces inferiorly, rests on the diaphragm, and consists of the left ventricle and a small portion of the right ventricle separated by the posterior interventricular groove. It does not include the base of the heart, which consists of the left atrium, a small portion of the right atrium, and the proximal parts of the superior and inferior venae cavae and the pulmonary veins.**

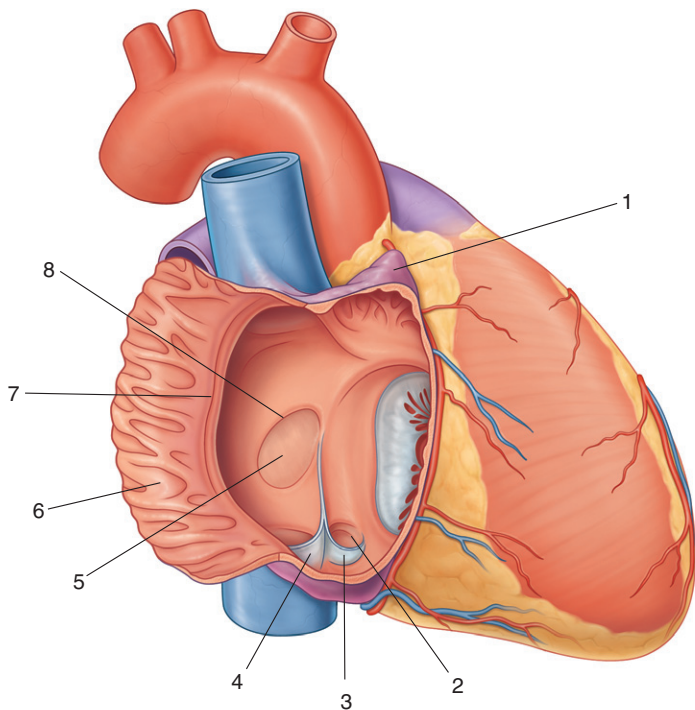
Figure from Gray's Anatomy for Students, 3rd edition, p. 187.



RIGHT ATRIUM

55

Identify the indicated structures in the right atrium.



RIGHT ATRIUM



1. Right auricle
2. Opening of coronary sinus
3. Valve of coronary sinus
4. Valve of inferior vena cava
5. Fossa ovalis
6. Musculi pectinati
7. Crista terminalis
8. Limbus of fossa ovalis

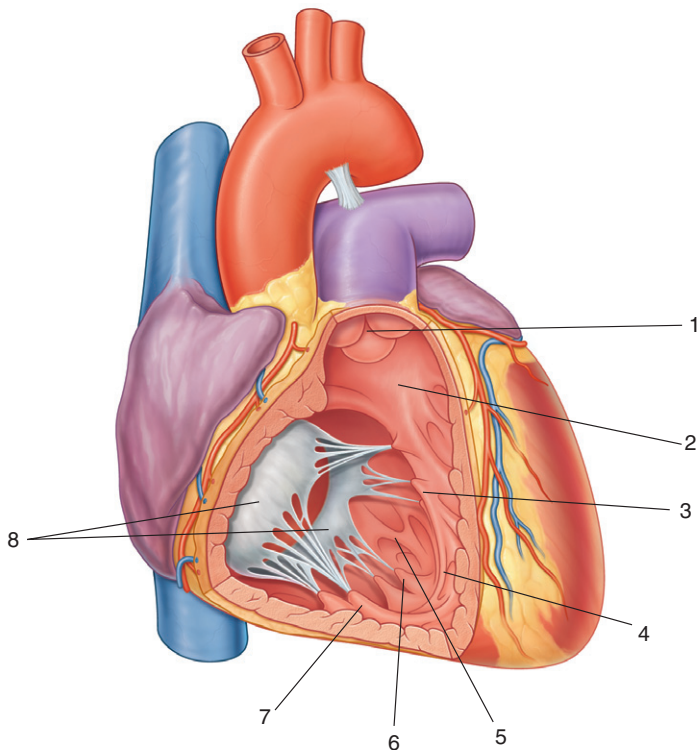
IN THE CLINIC:

- **The fossa ovalis marks the location of the embryonic foramen ovale, which is an important part of fetal circulation. The foramen ovale allows oxygenated blood entering the right atrium to pass directly to the left atrium and bypass the lungs, which are nonfunctional before birth.**

Figure from Gray's Anatomy for Students, 3rd edition, p. 191.



Identify the indicated structures in the right ventricle.



RIGHT VENTRICLE



1. Pulmonary valve
2. Conus arteriosus
3. Septal papillary muscle
4. Septomarginal trabecula
5. Trabeculae carneae
6. Posterior papillary muscle
7. Anterior papillary muscle
8. Tricuspid valve

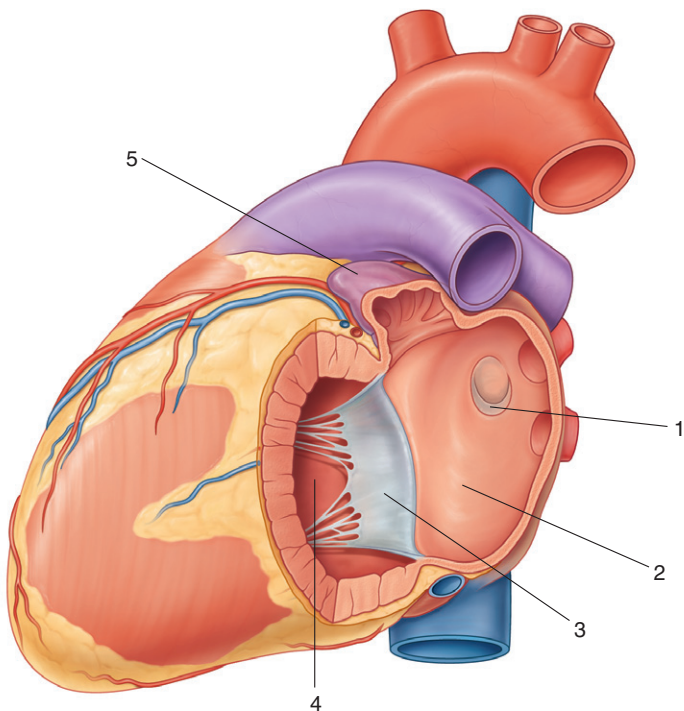
IN THE CLINIC:

- **Valve disease in the right side of the heart affecting the tricuspid or pulmonary valve commonly is caused by infection. The resulting valve dysfunction produces abnormal pressure changes in the right atrium and right ventricle.**

Figure from Gray's Anatomy for Students, 3rd edition, p. 193.



Identify the indicated structures in the left atrium.



LEFT ATRIUM



1. Valve of foramen ovale
2. Left atrium
3. Mitral valve
4. Left ventricle
5. Left auricle

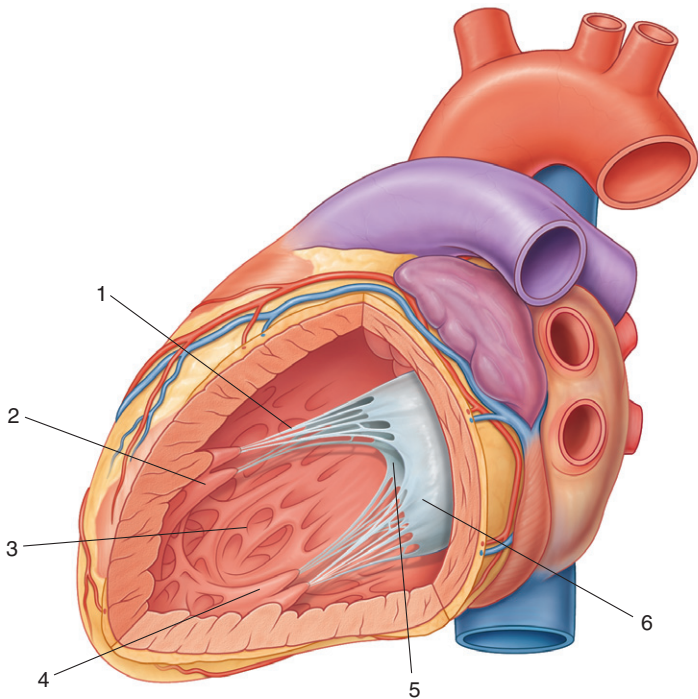
IN THE CLINIC:

- **Mitral valve disease is frequently a mixed pattern of stenosis and incompetence, one of which usually predominates. Both stenosis and incompetence lead to a poorly functioning valve and subsequent heart changes, including left ventricular hypertrophy, increased pulmonary venous pressure, pulmonary edema, and enlargement of the left atrium.**

Figure from Gray's Anatomy for Students, 3rd edition, p. 195.



Identify the indicated structures in the left ventricle.



LEFT VENTRICLE



1. Chordae tendineae
2. Anterior papillary muscle
3. Trabeculae carneae
4. Posterior papillary muscle
5. Mitral valve anterior cusp
6. Mitral valve posterior cusp

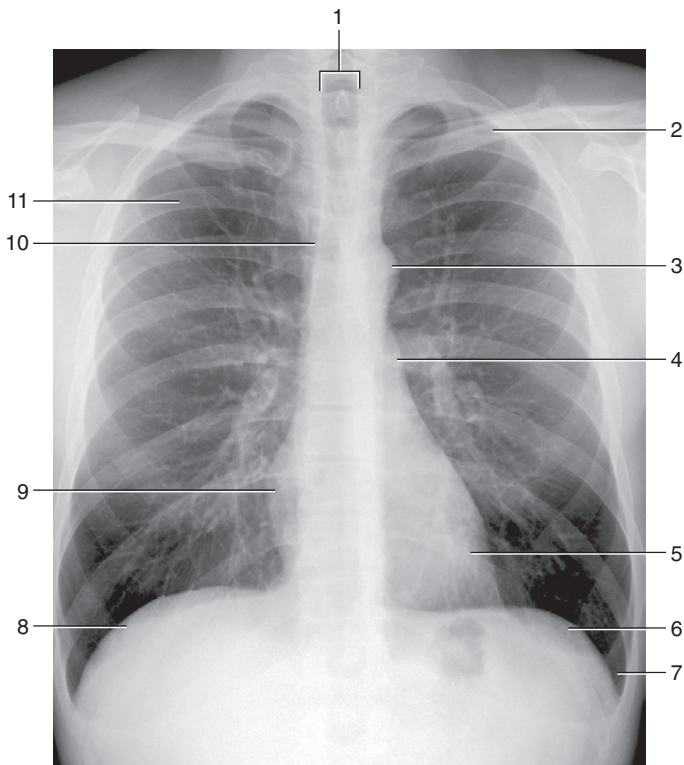
IN THE CLINIC:

- The most common congenital heart defects are those that involve the ventricular septum—ventriculoseptal defects (VSDs). They occur frequently in the membranous portion of the septum and allow blood to move from the high-pressure left ventricle to the lower-pressure right ventricle, producing a left-to-right shunt. This leads to right ventricular hypertrophy and possible pulmonary arterial hypertension.

Figure from Gray's Anatomy for Students, 3rd edition, p. 196.



Identify the indicated structures.



PLAIN CHEST RADIOGRAPH

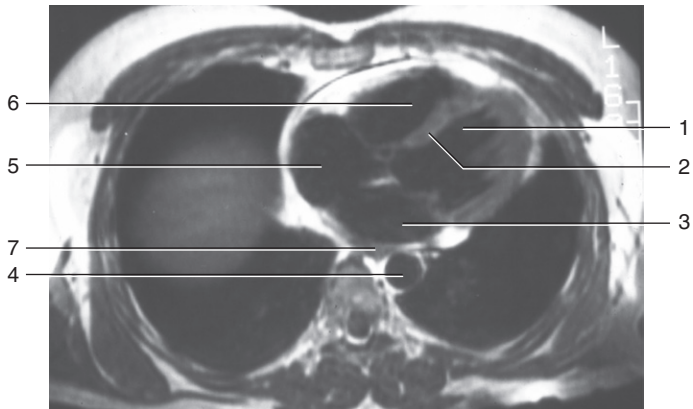


1. Trachea
2. Clavicle
3. Aortic arch
4. Pulmonary trunk
5. Left ventricle
6. Left dome of diaphragm
7. Costodiaphragmatic recess
8. Right dome of diaphragm
9. Right atrium
10. Superior vena cava
11. Rib

Figure from Gray's Basic Anatomy, p. 92.



Identify the indicated structures.



MRI: CHAMBERS OF THE HEART

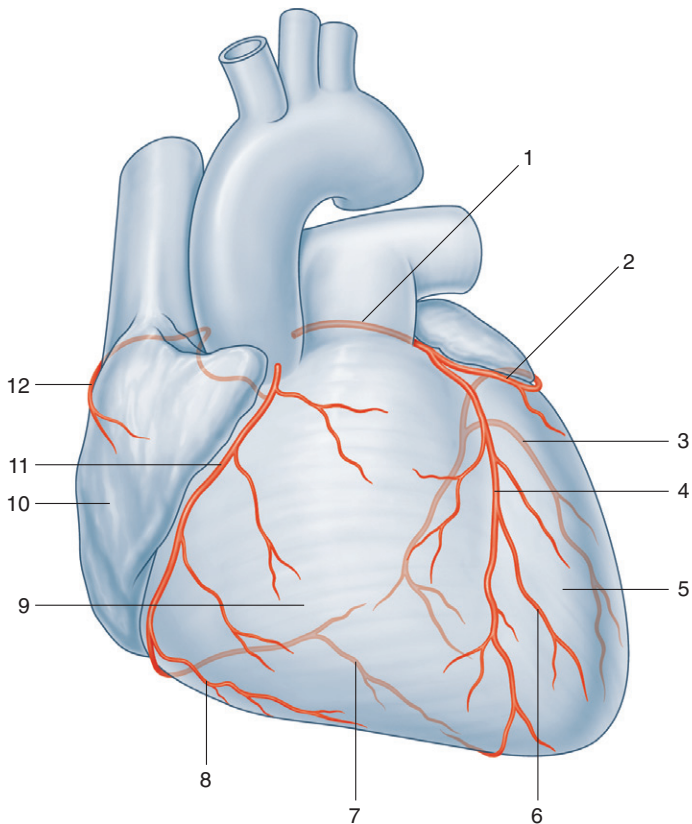


1. Left ventricle
2. Interventricular septum
3. Left atrium
4. Thoracic aorta
5. Right atrium
6. Right ventricle
7. Esophagus

Figure from Gray's Basic Anatomy, p. 100.



Identify the indicated coronary arteries and branches.



CORONARY ARTERIES



1. Left coronary artery
2. Circumflex branch
3. Left marginal branch
4. Anterior interventricular branch
5. Left ventricle
6. Diagonal branch
7. Posterior interventricular branch
8. Marginal branch
9. Right ventricle
10. Right atrium
11. Right coronary artery
12. Sinu-atrial nodal branch

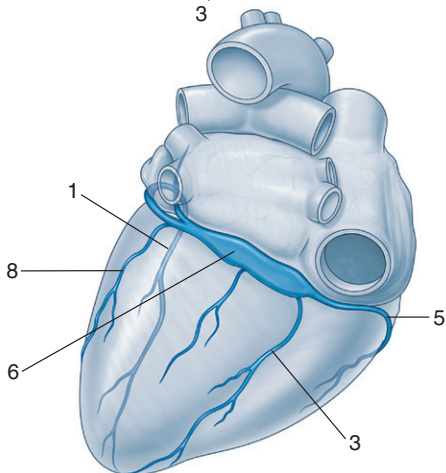
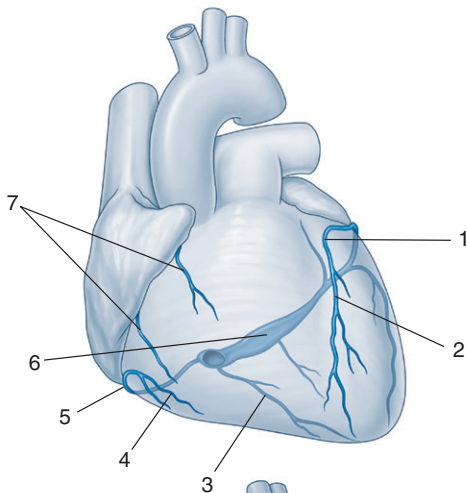
IN THE CLINIC:

- **Occlusion of a major coronary artery leads to inadequate oxygenation of an area of myocardium and cell death (myocardial infarction). Several procedures are available to improve blood flow in partially or completely occluded coronary arteries, including coronary angioplasty and coronary artery bypass grafting.**

Figure from Gray's Anatomy for Students, 3rd edition, p. 199.



Identify the indicated cardiac veins.



CORONARY VEINS

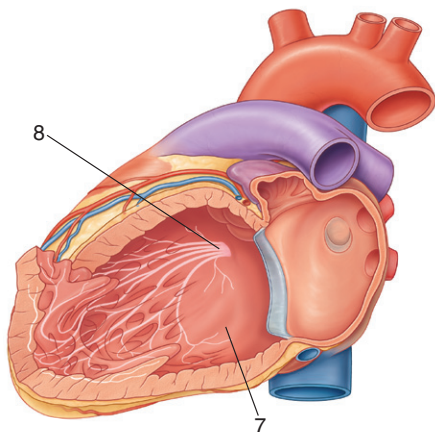
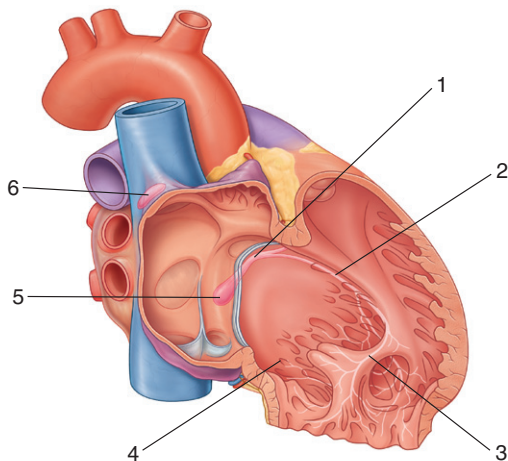


1. Great cardiac vein
2. Anterior interventricular vein
3. Middle cardiac vein
4. Right marginal vein
5. Small cardiac vein
6. Coronary sinus
7. Anterior cardiac veins of right ventricle
8. Posterior cardiac vein

Figure from Gray's Anatomy for Students, 3rd edition, p. 205.



Identify the indicated parts of the conduction system.



CONDUCTION SYSTEM



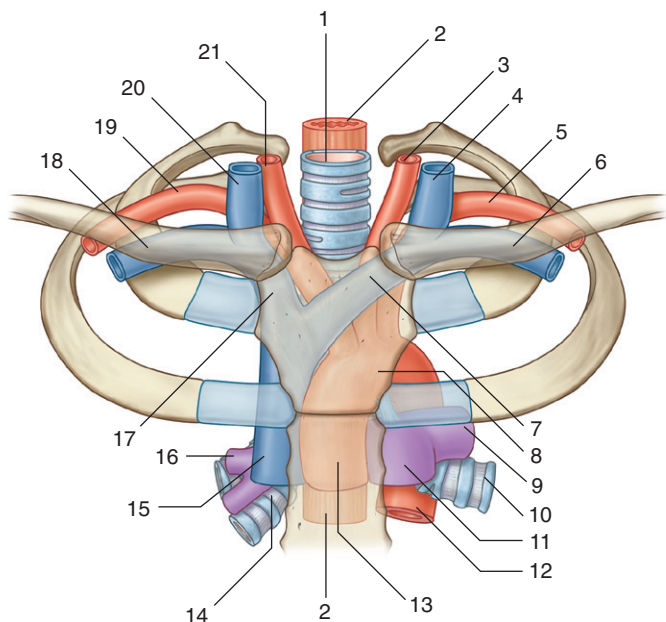
1. Atrioventricular bundle
2. Right bundle branch
3. Septomarginal trabecula
4. Right ventricle
5. Atrioventricular node
6. Sinu-atrial node
7. Left ventricle
8. Left bundle branch

IN THE CLINIC:

- **The musculature of the atria and ventricles is capable of contracting spontaneously. The cardiac conduction system coordinates contractions. Its unique distribution pattern establishes an important unidirectional wave of excitation/contraction that moves from the papillary muscles and apex of the ventricles to the outflow tracts.**

Figure from Gray's Anatomy for Students, 3rd edition, p. 207.

Identify the indicated structures in the superior mediastinum.



SUPERIOR MEDIASTINUM



1. Trachea
2. Esophagus
3. Left common carotid artery
4. Left internal jugular vein
5. Left subclavian artery
6. Left subclavian vein
7. Left brachiocephalic vein
8. Arch of aorta
9. Left pulmonary artery
10. Left main bronchus
11. Pulmonary trunk
12. Thoracic aorta
13. Ascending aorta
14. Right main bronchus
15. Superior vena cava
16. Right pulmonary artery
17. Right brachiocephalic vein
18. Right subclavian vein
19. Right subclavian artery
20. Right internal jugular vein
21. Right common carotid artery

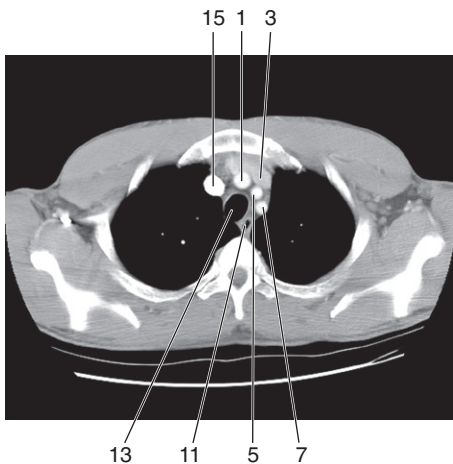
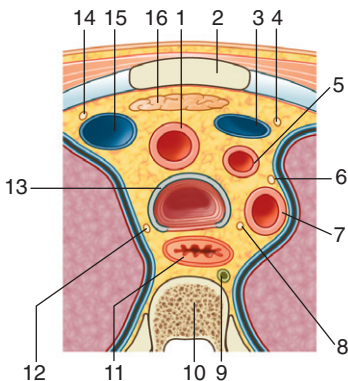
IN THE CLINIC:

- **The superior mediastinum is posterior to the manubrium of the sternum and anterior to the bodies of the first four thoracic vertebrae. Superiorly, an oblique plane passes from the jugular notch upward and posteriorly to the superior border of T1. Inferiorly, a transverse plane passes from the sternal angle to the intervertebral disc between T10 and T11. Laterally, it is bordered by the mediastinal part of the parietal pleura on either side.**

Figure from Gray's Anatomy for Students, 3rd edition, p. 211.

SUPERIOR MEDIASTINUM: CROSS SECTION

Identify the indicated structures in cross sections through the superior mediastinum at vertebral level TIII.



SUPERIOR MEDIASTINUM: CROSS SECTION



1. Brachiocephalic trunk
2. Manubrium of sternum
3. Left brachiocephalic vein
4. Left phrenic nerve
5. Left common carotid artery
6. Left vagus nerve
7. Left subclavian artery
8. Left recurrent laryngeal nerve
9. Thoracic duct
10. TIII
11. Esophagus
12. Right vagus nerve
13. Trachea
14. Right phrenic nerve
15. Right brachiocephalic vein
16. Thymus

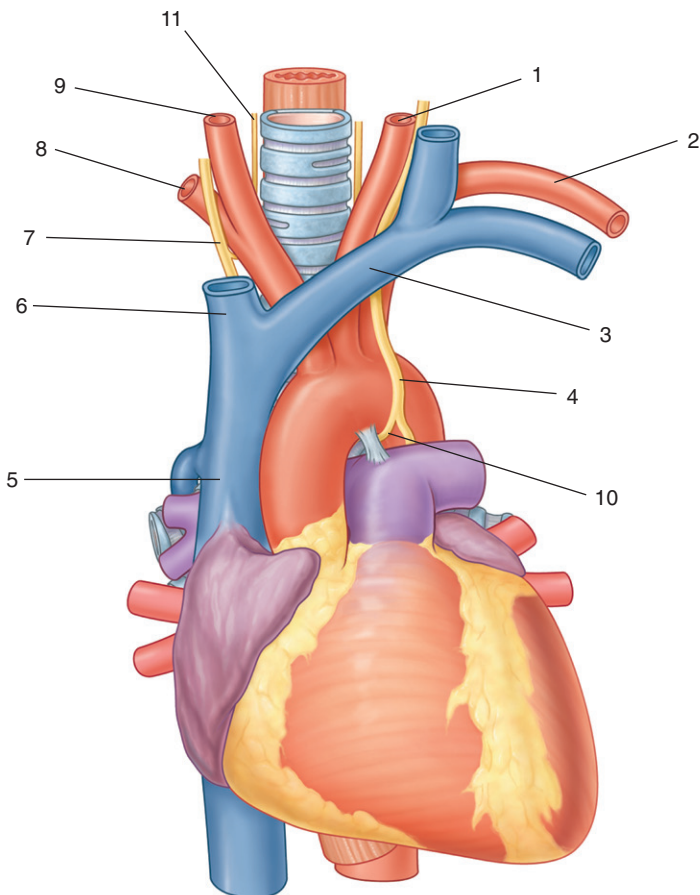
IN THE CLINIC:

- **Axial diagrams and CT images demonstrate the unique relationships of the various structures in the superior mediastinum. CT enables any abnormal structures (e.g., lymph nodes or tumors) to be demonstrated and also allows assessment of their relationship to other local structures.**

Figure from Gray's Anatomy for Students, 3rd edition, p. 211.

SUPERIOR MEDIASTINUM: GREAT VESSELS

Identify indicated vessels and nerves in superior mediastinum.



SUPERIOR MEDIASTINUM: GREAT VESSELS



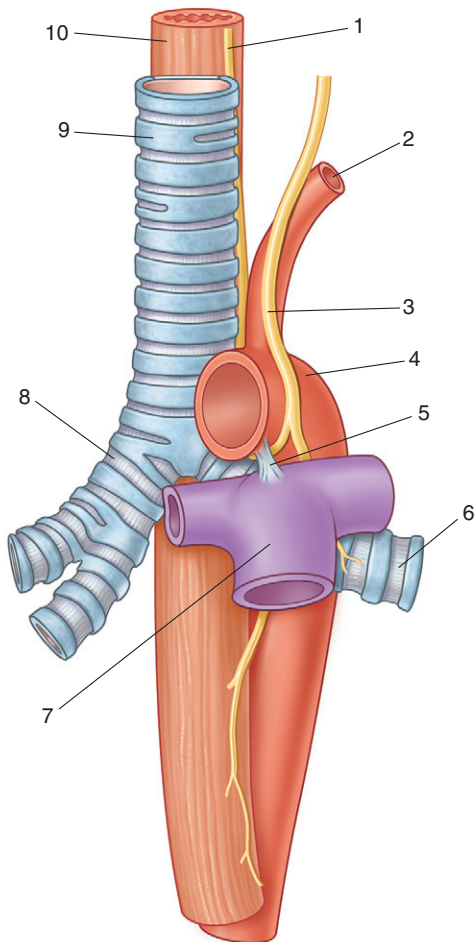
1. Left common carotid artery
2. Left subclavian artery
3. Left brachiocephalic vein
4. Left vagus nerve
5. Superior vena cava
6. Right brachiocephalic vein
7. Right vagus nerve
8. Right subclavian artery
9. Right common carotid artery
10. Left recurrent laryngeal nerve
11. Right recurrent laryngeal nerve

IN THE CLINIC:

- **An aortic dissection occurs when the wall of the aorta splits longitudinally, creating a false channel, which may or may not rejoin the true lumen distally. The splitting occurs between the intima and media anywhere along its length. If it occurs in the ascending aorta or arch, blood flow in the coronary and cerebral arteries may be disrupted.**

Figure from Gray's Anatomy for Students, 3rd edition, p. 213.

Identify the indicated structures.



SUPERIOR MEDIASTINUM: TRACHEA AND ESOPHAGUS



1. Left recurrent laryngeal nerve
2. Left subclavian artery
3. Left vagus nerve
4. Arch of aorta
5. Ligamentum arteriosum
6. Left main bronchus
7. Pulmonary trunk
8. Right main bronchus
9. Trachea
10. Esophagus

IN THE CLINIC:

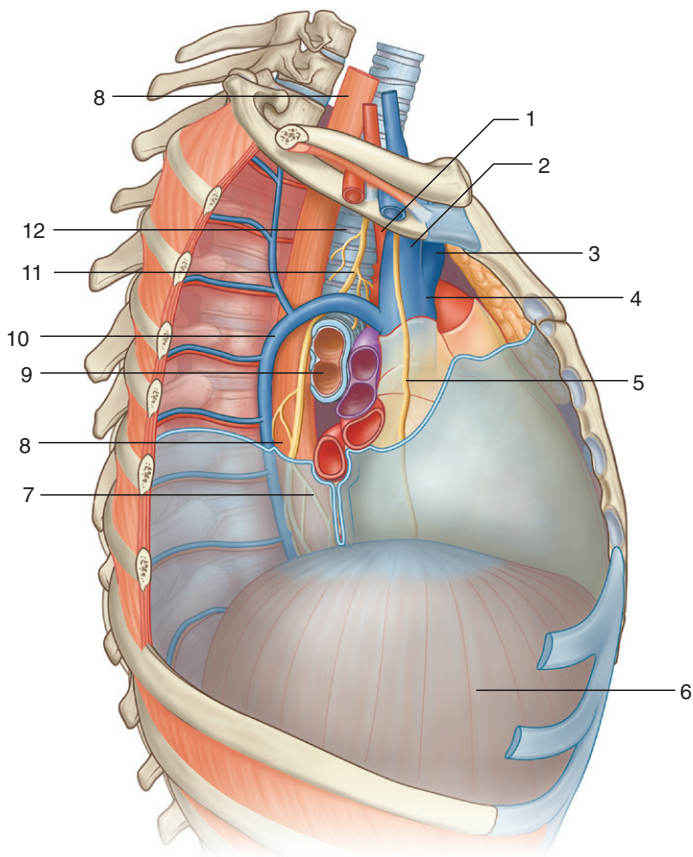
- The trachea is a midline structure that is palpable above the jugular notch as it enters the superior mediastinum. Significant mobility exists in the vertical positioning of this structure as it passes through the superior mediastinum. Breathing and pathologic processes can cause positional shifts in the trachea.

Figure from Gray's Anatomy for Students, 3rd edition, p. 221.

MEDIASTINUM: RIGHT LATERAL VIEW

68

Identify indicated structures in this right lateral view of the mediastinum.



MEDIASTINUM: RIGHT LATERAL VIEW



1. Brachiocephalic trunk
2. Right brachiocephalic vein
3. Left brachiocephalic vein
4. Superior vena cava
5. Right phrenic nerve
6. Diaphragm
7. Esophageal plexus
8. Esophagus
9. Bronchus
10. Azygos vein
11. Right vagus nerve
12. Trachea

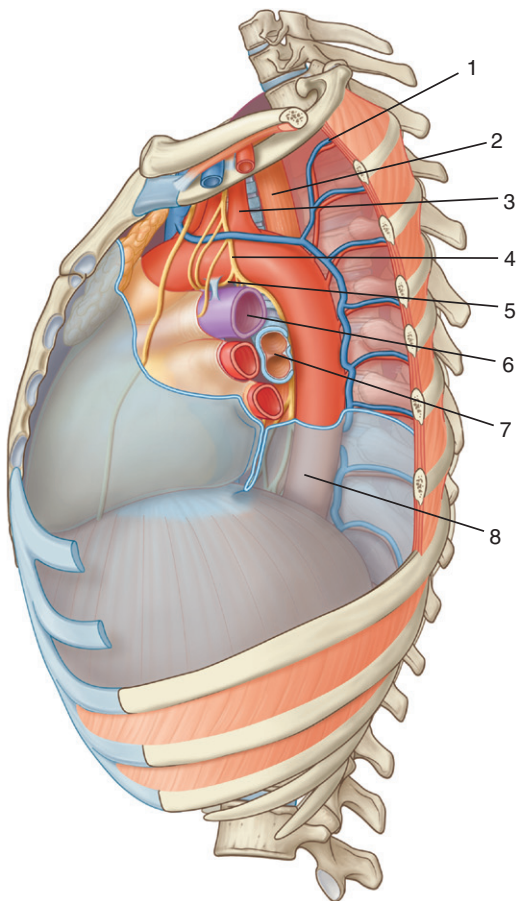
IN THE CLINIC:

- **A large tumor in the hilum of the right lung expanding anteriorly may compress and damage the right phrenic nerve. If this occurs, a chest radiograph may show an elevated diaphragm on the right side.**

Figure from Gray's Anatomy for Students, 3rd edition, p. 219.



Identify indicated structures in this left lateral view of the mediastinum.



MEDIASTINUM: LEFT LATERAL VIEW



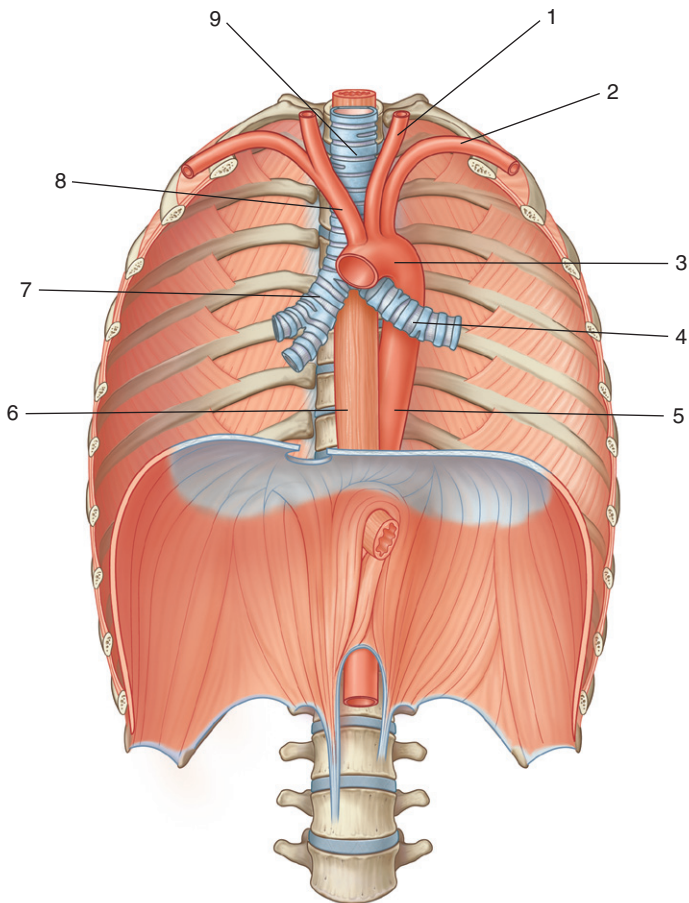
1. Left superior intercostal vein
2. Esophagus
3. Left subclavian artery
4. Left vagus nerve
5. Left recurrent laryngeal nerve
6. Left pulmonary artery
7. Bronchus
8. Thoracic aorta

IN THE CLINIC:

- **The left recurrent laryngeal nerve is a branch of the left vagus nerve. It passes between the pulmonary artery and the aorta and may be compressed by a mass in this region, enlarged lymph nodes, or bronchogenic carcinoma. This compression results in paralysis of the left vocal cord and hoarseness of the voice.**

Figure from Gray's Anatomy for Students, 3rd edition, p. 220.

Identify the indicated structures.



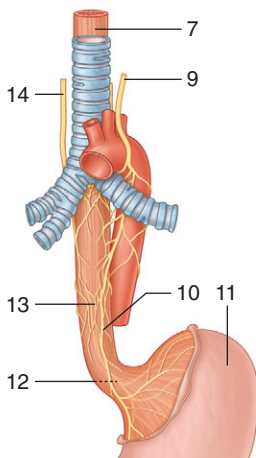
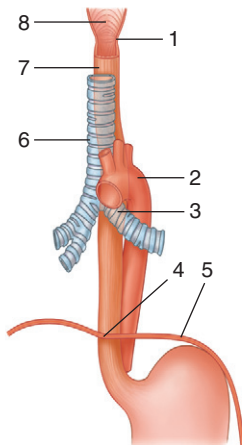
POSTERIOR MEDIASTINUM



1. Left common carotid artery
2. Left subclavian artery
3. Arch of aorta
4. Left main bronchus
5. Thoracic aorta
6. Esophagus
7. Right main bronchus
8. Brachiocephalic trunk
9. Trachea

Figure from Gray's Anatomy for Students, 3rd edition, p. 223.

Identify the indicated esophageal constrictions and structures.



NORMAL ESOPHAGEAL CONSTRICTIONS AND ESOPHAGEAL PLEXUS



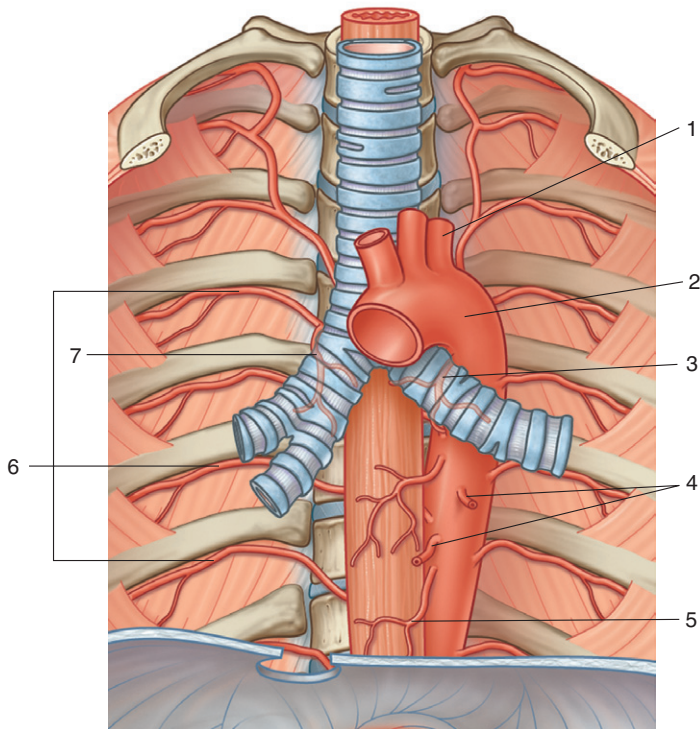
1. Junction of esophagus with pharynx (constriction)
2. Where esophagus is crossed by arch of aorta (constriction)
3. Where esophagus is crossed by left main bronchus (constriction)
4. At the esophageal hiatus in the diaphragm (constriction)
5. Diaphragm
6. Trachea
7. Esophagus
8. Pharynx
9. Left vagus nerve
10. Anterior vagal trunk
11. Stomach
12. Posterior vagal trunk
13. Esophageal plexus
14. Right vagus nerve

IN THE CLINIC:

- **Esophageal constrictions have important clinical consequences. A swallowed object may lodge at a potential constriction. Ingested corrosive substances may pass slowly through the narrowed region, producing a chemical stricture. Constrictions may present problems during the passage of instruments.**

Figure from Gray's Anatomy for Students, 3rd edition, p. 224.

Identify the indicated branches of the thoracic aorta.



THORACIC AORTA AND BRANCHES



1. Left subclavian artery
2. Arch of aorta
3. Superior left bronchial artery
4. Mediastinal branches
5. Esophageal branches
6. Posterior intercostal arteries
7. Right bronchial artery

IN THE CLINIC:

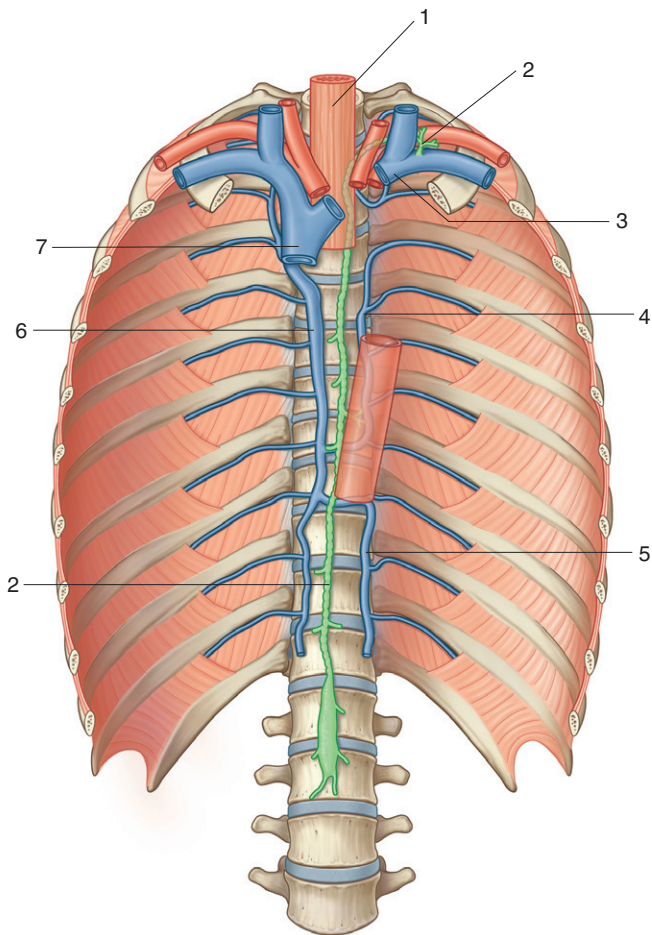
- **As the thoracic aorta passes through the posterior mediastinum, it is positioned to the left of the vertebral column superiorly and approaches the midline inferiorly, lying directly anterior to the lower thoracic vertebral bodies.**

Figure from Gray's Anatomy for Students, 3rd edition, p. 225.

AZYGOS SYSTEM OF VEINS AND THORACIC DUCT

73

Identify the indicated structures.



AZYGOS SYSTEM OF VEINS AND THORACIC DUCT



1. Esophagus
2. Thoracic duct
3. Left brachiocephalic vein
4. Accessory hemi-azygos vein
5. Hemi-azygos vein
6. Azygos vein
7. Superior vena cava

IN THE CLINIC:

- **The azygos system of veins serves as an important anastomotic pathway capable of returning venous blood from the lower part of the body to the heart if the inferior vena cava is blocked.**

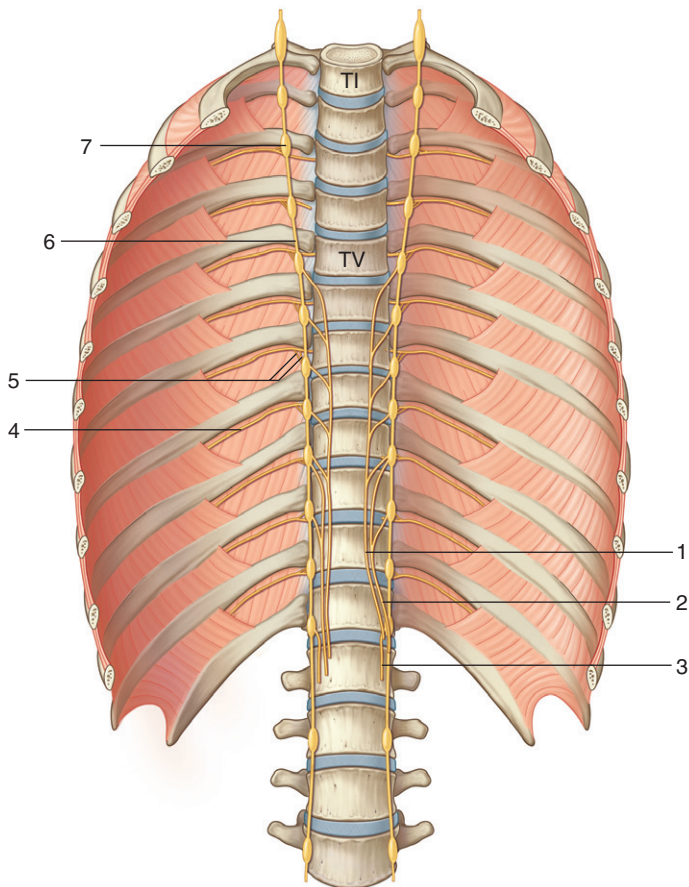
Figure from Gray's Anatomy for Students, 3rd edition, p. 228.



THORACIC SYMPATHETIC TRUNKS AND SPLANCHNIC NERVES

74

Identify the indicated structures.



THORACIC SYMPATHETIC TRUNKS AND SPLANCHNIC NERVES



1. Greater splanchnic nerve
2. Lesser splanchnic nerve
3. Least splanchnic nerve
4. Intercostal nerve (anterior ramus of a thoracic spinal nerve)
5. Gray and white rami communicantes
6. Sympathetic trunk
7. Sympathetic ganglion

IN THE CLINIC:

- **The visceral afferents from the vagus nerves are mainly involved in relaying information back to the central nervous system about normal physiologic processes and reflex activities. They are less involved in the relay of pain recognition. The visceral afferents that pass through the sympathetic trunks and the splanchnic nerves are the primary participants in the detection of pain from the viscera and the transmission of this information to the central nervous system.**

Figure from Gray's Anatomy for Students, 3rd edition, p. 229.



SECTION 4: ABDOMEN

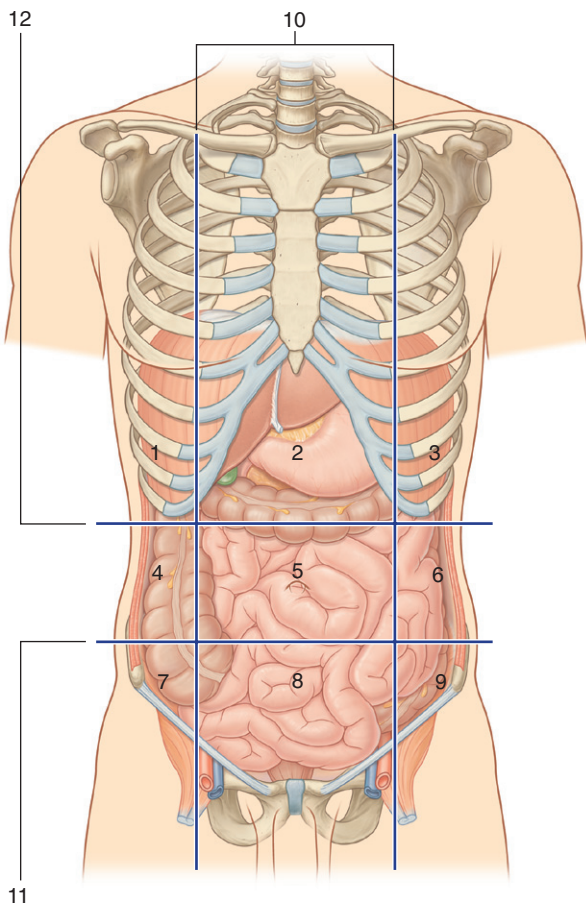
75. Abdominal Wall: Nine-Region Pattern
76. Abdominal Wall: Layers Overview
77. Abdominal Wall: Transverse Section
78. Rectus Abdominis
79. Rectus Sheath
80. Inguinal Canal
81. Spermatic Cord
82. Inguinal Region: Internal View
83. Viscera: Anterior View
84. Viscera: Anterior View, Small Bowel Removed
85. Stomach
86. Double-Contrast Radiograph: Stomach and Duodenum
87. Duodenum
88. Radiograph: Jejunum and Ileum
89. Large Intestine
90. Barium Radiograph: Large Intestine
91. Liver
92. CT: Liver
93. Pancreas
94. CT: Pancreas
95. Bile Drainage
96. Arteries: Arterial Supply of Viscera
97. Arteries: Celiac Trunk
98. Arteries: Superior Mesenteric
99. Arteries: Inferior Mesenteric
100. Veins: Portal System
101. Viscera: Innervation
102. Posterior Abdominal Region: Overview
103. Posterior Abdominal Region: Bones
104. Posterior Abdominal Region: Muscles
105. Diaphragm
106. Anterior Relationships of Kidneys
107. Internal Structure of the Kidney
108. CT: Renal Pelvis
109. Renal and Suprarenal Gland Vessels
110. Abdominal Aorta
111. Inferior Vena Cava
112. Urogram: Pathway of Ureter
113. Lumbar Plexus



ABDOMINAL WALL: NINE-REGION PATTERN

75

Identify the indicated abdominal regions and the planes that separate them.



ABDOMINAL WALL: NINE-REGION PATTERN



1. Right hypochondrium
2. Epigastric
3. Left hypochondrium
4. Right flank
5. Umbilical region
6. Left flank
7. Right groin
8. Pubic region
9. Left groin
10. Midclavicular planes
11. Intertubercular plane
12. Subcostal plane

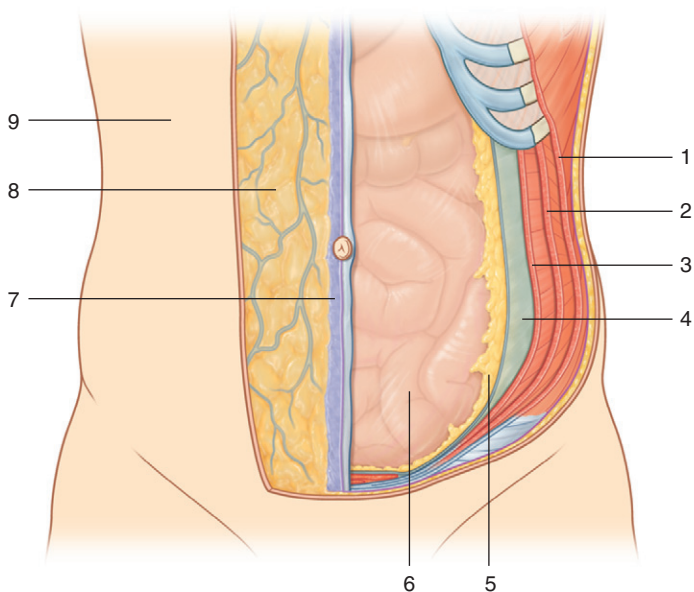
IN THE CLINIC:

- **Topographic divisions of the abdomen are used to describe the location of abdominal organs and the pain associated with abdominal problems. The two schemes most often used are a four-quadrant pattern (not illustrated on this card) and a nine-region organizational pattern.**

Figure from Gray's Anatomy for Students, 3rd edition, p. 278.



Identify the indicated layers of the abdominal wall.



ABDOMINAL WALL: LAYERS OVERVIEW



1. External oblique muscle
2. Internal oblique muscle
3. Transversus abdominis muscle
4. Transversalis fascia
5. Extraperitoneal fascia
6. Parietal peritoneum
7. Superficial fascia—membranous layer (Scarpa's fascia)
8. Superficial fascia—fatty layer (Camper's fascia)
9. Skin

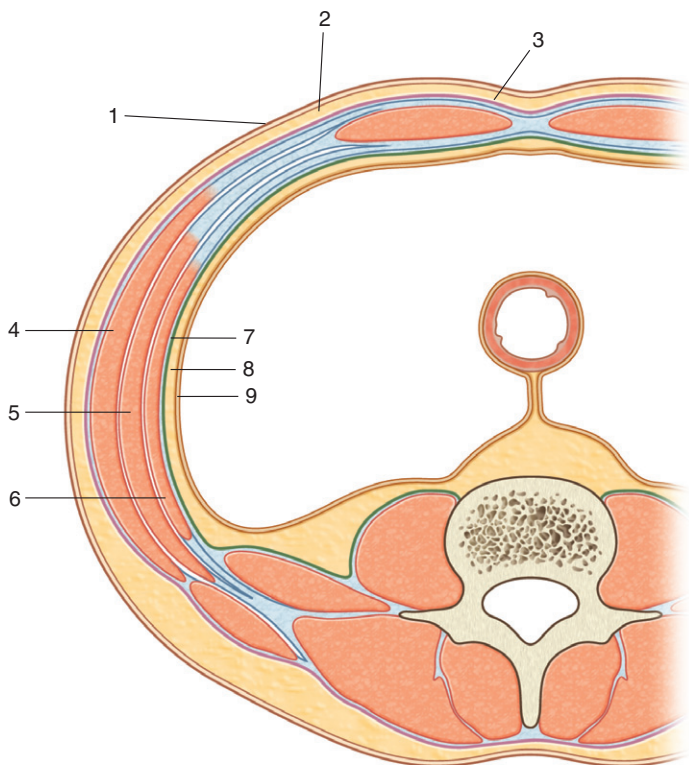
IN THE CLINIC:

- The abdominal wall is bounded superiorly by the xiphoid process and costal margins, posteriorly by the vertebral column, and inferiorly by the upper parts of the pelvic bones. Its layers consist of skin, superficial fascia (subcutaneous tissue), muscles and their associated deep fascias, extraperitoneal fascia, and parietal peritoneum.

Figure from Gray's Anatomy for Students, 3rd edition, p. 280.



Identify the indicated layers in this transverse section of the abdominal wall.



ABDOMINAL WALL: TRANSVERSE SECTION



1. Skin
2. Superficial fascia—fatty layer (Camper's fascia)
3. Superficial fascia—membranous layer (Scarpa's fascia)
4. External oblique muscle
5. Internal oblique muscle
6. Transversus abdominis muscle
7. Transversalis fascia
8. Extraperitoneal fascia
9. Parietal peritoneum

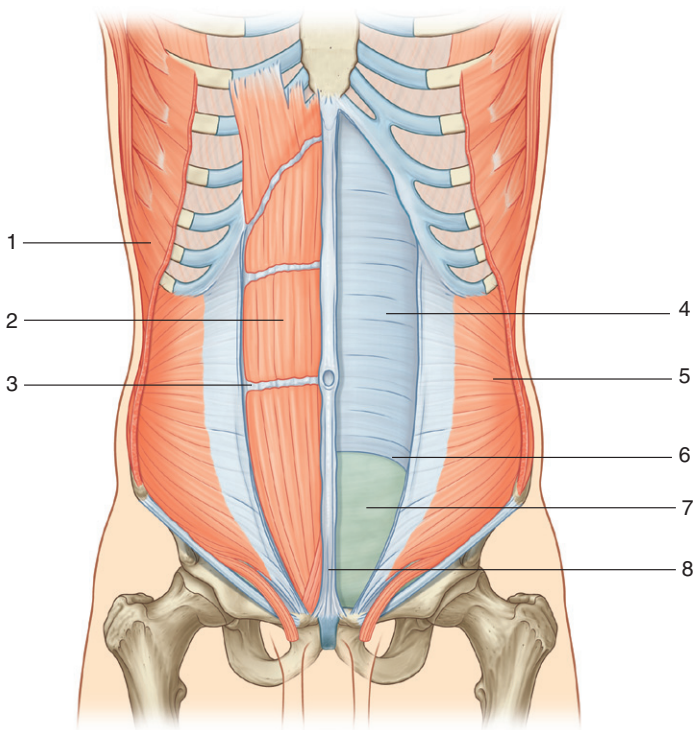
IN THE CLINIC:

- **The continuous lining of the abdominal walls by the parietal peritoneum forms a sac. This sac is closed in men but has two openings in women, where the uterine tubes provide a passage to the outside. The closed sac in men and the semi-closed sac in women is called the peritoneal cavity.**

Figure from Gray's Anatomy for Students, 3rd edition, p. 288.



Identify the indicated structures related to the rectus abdominis muscle and its sheath.



RECTUS ABDOMINIS



1. External oblique muscle
2. Rectus abdominis muscle
3. Tendinous intersection
4. Posterior wall of rectus sheath
5. Internal oblique muscle
6. Arcuate line
7. Transversalis fascia
8. Linea alba

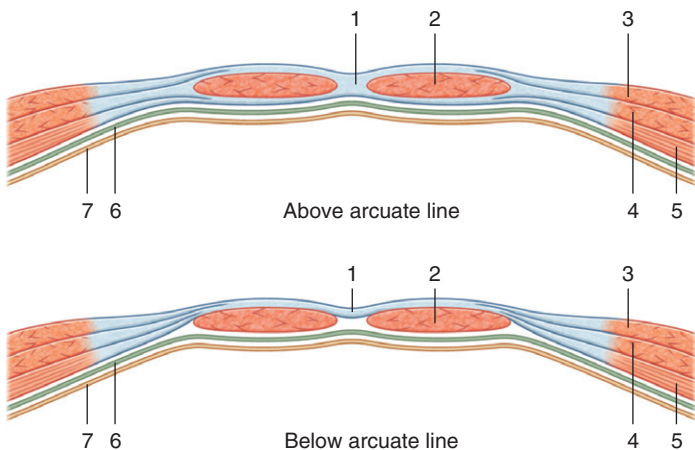
IN THE CLINIC:

- **Along the course of the rectus abdominis muscle it is intersected by three or four transverse fibrous bands, or tendinous intersections, clearly visible on individuals with a well-developed rectus abdominis.**

Figure from Gray's Anatomy for Students, 3rd edition, p. 282.



Identify the indicated structures related to the rectus sheath.



RECTUS SHEATH



1. Linea alba
2. Rectus abdominis muscle
3. External oblique muscle
4. Internal oblique muscle
5. Transversus abdominis muscle
6. Transversalis fascia
7. Parietal peritoneum

IN THE CLINIC:

- **The rectus sheath completely encloses the upper three fourths of the rectus abdominis muscle and covers the anterior surface of the lower one fourth of the muscle. Because no sheath covers the posterior surface of the lower quarter of the rectus abdominis muscle, the muscle at this point is in direct contact with the transversalis fascia.**

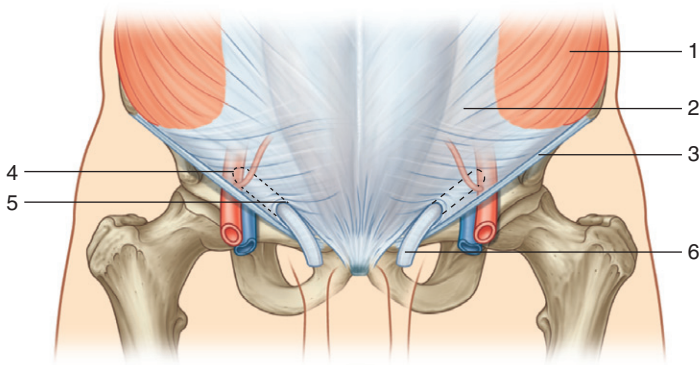
Figure from Gray's Anatomy for Students, 3rd edition, p. 287.



INGUINAL CANAL

80

Identify the indicated structures related to the inguinal canal.



INGUINAL CANAL



1. External oblique muscle
2. Aponeurosis of external oblique
3. Inguinal ligament
4. Position of deep inguinal ring
5. Superficial inguinal ring
6. Spermatic cord

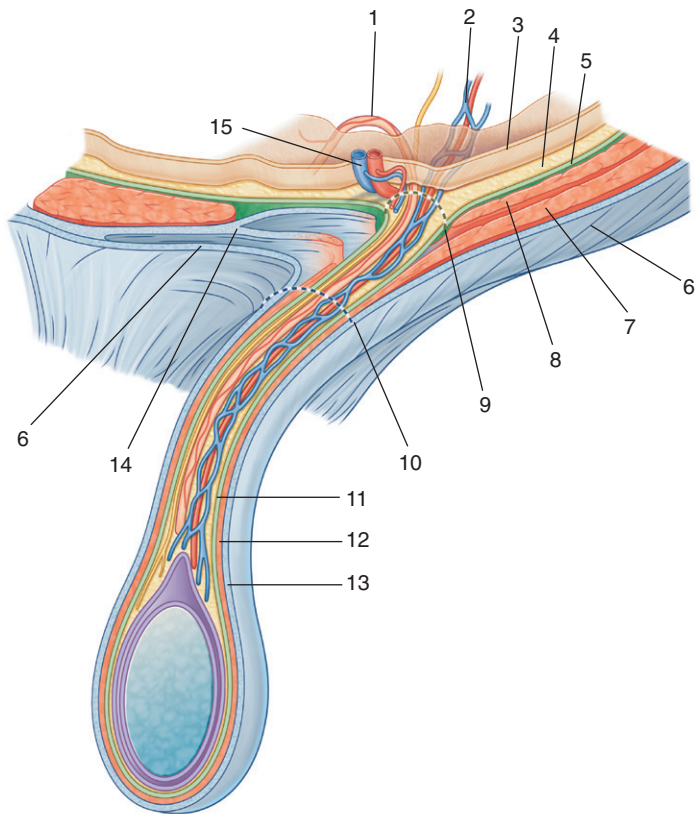
IN THE CLINIC:

- The groin, or inguinal region, is the area at the junction of the anterior abdominal wall and the thigh. The inguinal canal is situated in this area. Potential weaknesses in the abdominal wall may occur during development, permitting the peritoneal sac to protrude through it and producing an inguinal hernia. This sac may contain abdominal viscera. Inguinal hernias may occur in both sexes, although they are more common in males.

Figure from Gray's Anatomy for Students, 3rd edition, p. 294.



Identify the indicated structures.



SPERMATIC CORD



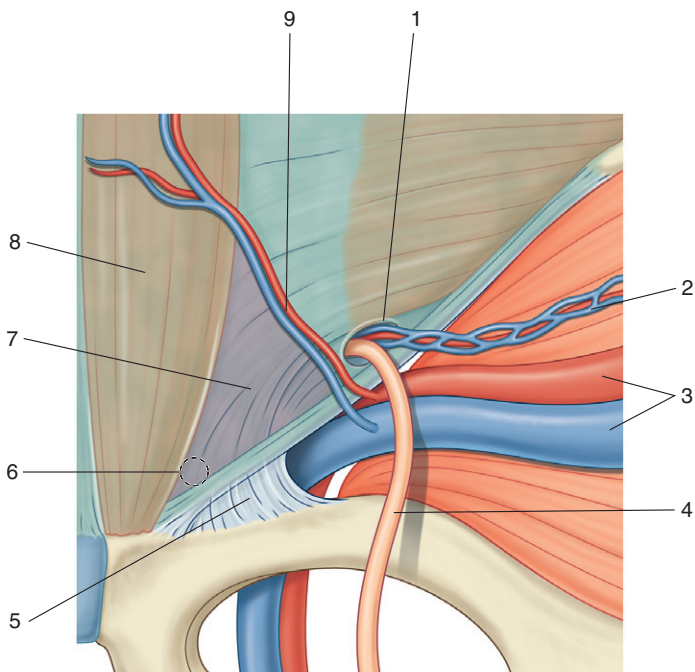
1. Ductus deferens
2. Testicular artery and pampiniform plexus of veins
3. Parietal peritoneum
4. Extraperitoneal fascia
5. Transversalis fascia
6. External oblique aponeurosis
7. Internal oblique muscle
8. Transversus abdominis muscle
9. Deep inguinal ring
10. Superficial inguinal ring
11. Internal spermatic fascia
12. Cremasteric fascia
13. External spermatic fascia
14. Conjoint tendon
15. Inferior epigastric vessels

IN THE CLINIC:

- The spermatic cord is formed from the structures passing between the abdominopelvic cavities and the testis and from the three fascial coverings that enclose these structures. The structures enter the deep inguinal ring and pass through the inguinal canal, exiting from the superficial inguinal ring having acquired the three fascial coverings. This collection of structures and fascias descends into the scrotum, where the structures connect with the testes and the fascias surround the testes.

Figure from Gray's Anatomy for Students, 3rd edition, p. 298.

Identify the indicated structures in an internal view of the inguinal region.



INGUINAL REGION: INTERNAL VIEW



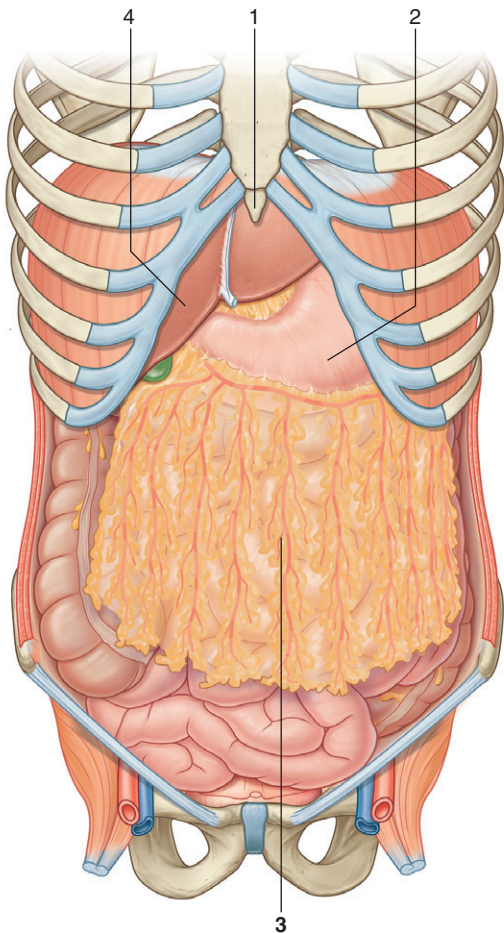
1. Deep inguinal ring
2. Testicular vessels
3. External iliac artery and vein
4. Ductus deferens
5. Lacunar ligament
6. Position of superficial inguinal ring
7. Inguinal triangle
8. Rectus abdominis muscle
9. Inferior epigastric vessels

IN THE CLINIC:

- **Indirect inguinal hernia:** A protruding peritoneal sac enters the deep inguinal ring, lateral to the inferior epigastric vessels, and passes through the inguinal canal. If the hernia is large enough, the sac may emerge through the superficial inguinal ring and, in men, enter the scrotum.
- **Direct inguinal hernia:** A protruding peritoneal sac pushes forward, medial to the inferior epigastric vessels, through the posterior wall of the inguinal canal. If the hernia is large enough, the sac may emerge through the superficial inguinal ring.

Figure from Gray's Anatomy for Students, 3rd edition, p. 300.

Identify the indicated structures.



VISCERA: ANTERIOR VIEW



1. Xiphoid process
2. Stomach
3. Greater omentum
4. Liver

IN THE CLINIC:

- **When a laparotomy (surgical incision through the abdominal wall) is performed and the peritoneal cavity is opened, the first structure usually encountered is the greater omentum. This fatty, double-layered vascular membrane hangs like an apron from the greater curvature of the stomach, drapes over the transverse colon, and lies freely suspended within the peritoneal cavity.**

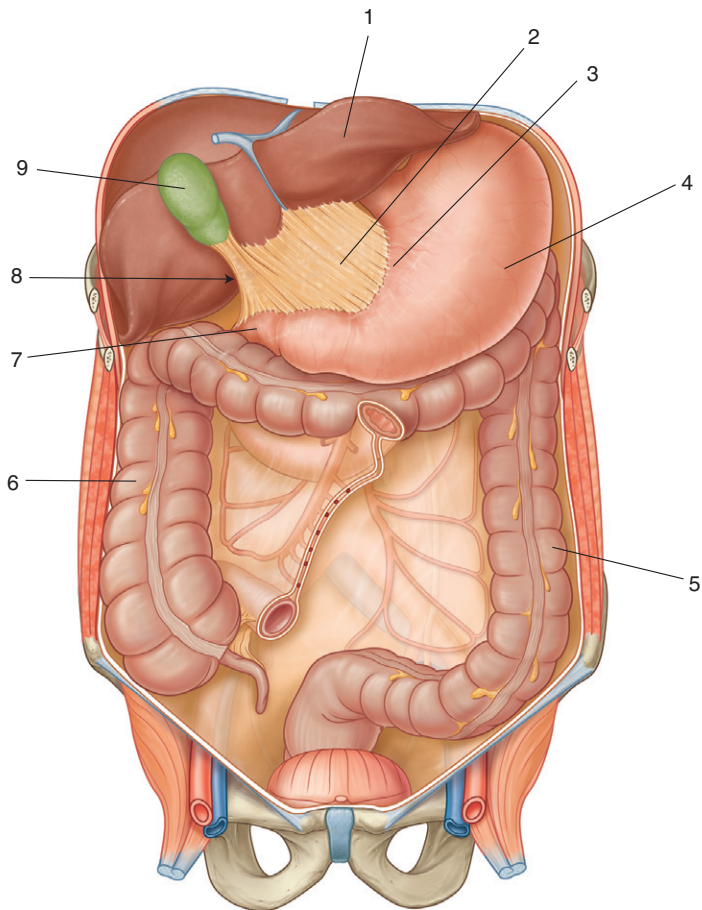
Figure from Gray's Anatomy for Students, 3rd edition, p. 307.



VISCERA: ANTERIOR VIEW, SMALL BOWEL REMOVED

84

Identify the indicated structures.



VISCERA: ANTERIOR VIEW, SMALL BOWEL REMOVED



1. Liver
2. Lesser omentum
3. Lesser curvature of the stomach
4. Stomach
5. Descending colon
6. Ascending colon
7. Duodenum
8. Omental foramen
9. Gallbladder

IN THE CLINIC:

- **Surrounding the omental foramen are numerous structures covered with peritoneum. They include the portal vein, the hepatic artery proper and bile duct anteriorly, the inferior vena cava posteriorly, the caudate lobe of the liver superiorly, and the first part of the duodenum inferiorly.**

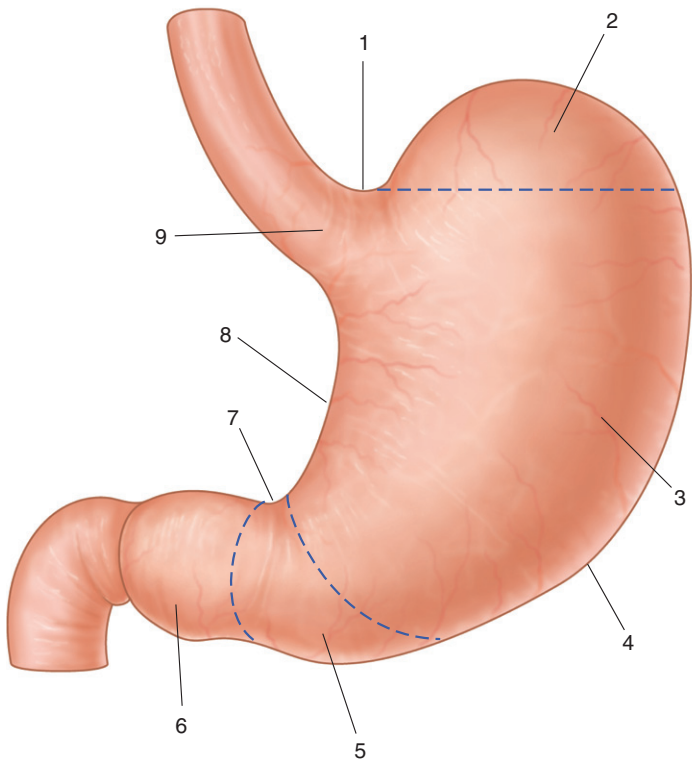
Figure from Gray's Anatomy for Students, 3rd edition, p. 308.



STOMACH

85

Identify the indicated parts of the stomach.



STOMACH



1. Cardiac notch
2. Fundus
3. Body
4. Greater curvature
5. Pyloric antrum
6. Pyloric canal
7. Angular incisure
8. Lesser curvature
9. Cardia

IN THE CLINIC:

- **At the level of the gastroesophageal junction, there is a physiologic sphincter, which is demarcated by a transition from one epithelial type to another epithelial type. In some people the histologic junction does not lie at the physiologic gastroesophageal junction but is in the lower third of the esophagus. This may predispose to esophageal ulceration and is also associated with an increased risk of carcinoma.**

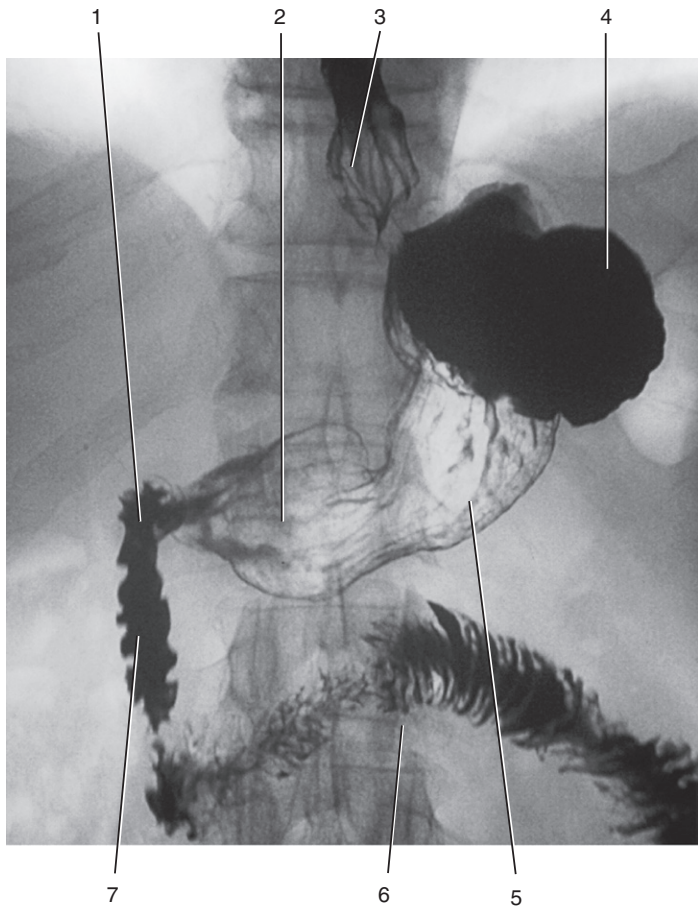
Figure from Gray's Anatomy for Students, 3rd edition, p. 311.



DOUBLE-CONTRAST RADIOGRAPH: STOMACH AND DUODENUM

86

Identify the indicated structures.



DOUBLE-CONTRAST RADIOGRAPH: STOMACH AND DUODENUM

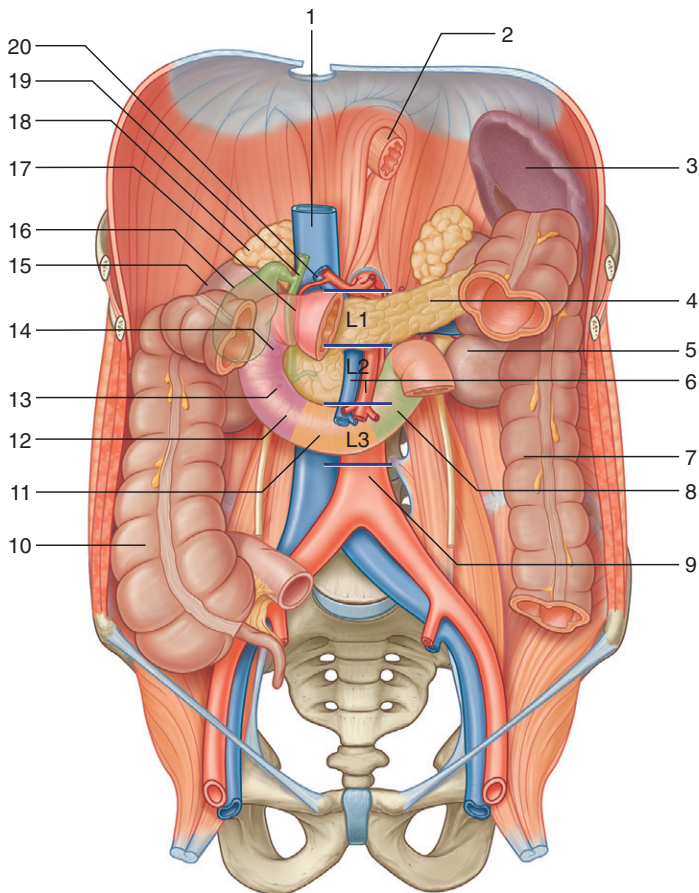


1. Superior part of duodenum
2. Pyloric antrum
3. Esophagus
4. Fundus of stomach
5. Body of stomach
6. Duodenal jejunal flexure
7. Descending part of duodenum

Figure from Gray's Basic Anatomy, p. 154.



Identify the indicated structures.



DUODENUM



1. Inferior vena cava
2. Esophagus
3. Spleen
4. Pancreas
5. Left kidney
6. Superior mesenteric vein and artery
7. Descending colon
8. Duodenum—ascending part
9. Abdominal aorta
10. Ascending colon
11. Duodenum—inferior part
12. Duodenum—descending part
13. Position of major duodenal papilla
14. Position of minor duodenal papilla
15. Right kidney
16. Gallbladder
17. Duodenum—superior part
18. Right suprarenal gland
19. Bile duct
20. Portal vein

IN THE CLINIC:

- **Duodenal ulcers tend to occur either anteriorly or posteriorly. Posterior duodenal ulcers erode either directly onto the gastroduodenal artery or, more commonly, onto the posterior superior pancreaticoduodenal artery. Anterior duodenal ulcers erode into the peritoneal cavity, causing peritonitis. This intense inflammatory reaction promotes adhesion of the greater omentum, which attempts to seal off the perforation.**

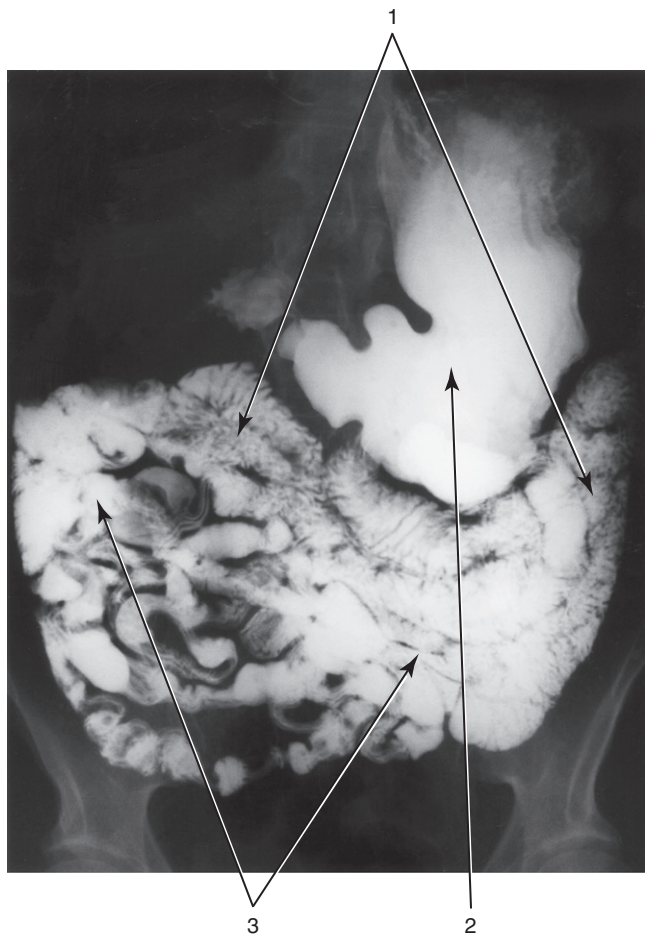
Figure from Gray's Anatomy for Students, 3rd edition, p. 312.



RADIOGRAPH: JEJUNUM AND ILEUM

88

Identify the indicated structures.



RADIOGRAPH: JEJUNUM AND ILEUM



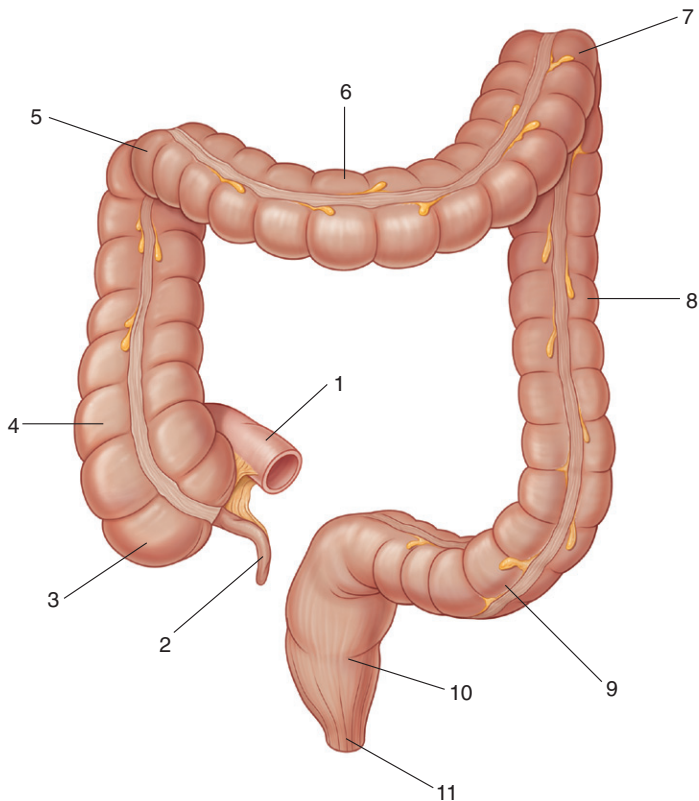
1. Jejunum
2. Stomach
3. Ileum

Figure from Gray's Basic Anatomy, p. 156.



LARGE INTESTINE

Identify the indicated parts of the large intestine.



LARGE INTESTINE



1. Ileum
2. Appendix
3. Cecum
4. Ascending colon
5. Right colic flexure
6. Transverse colon
7. Left colic flexure
8. Descending colon
9. Sigmoid colon
10. Rectum
11. Anal canal

IN THE CLINIC:

- Unique characteristics of most of the large intestine are peritoneal-covered accumulations of fat, the omental appendices, the segregation of longitudinal muscle in its walls into three narrow bands, the taeniae coli, and sacculations (the haustra).
- Major vessels and lymphatics are on the medial or posteromedial sides of the ascending and descending colon. A relatively blood-free mobilization of the ascending and descending colon is possible by cutting the peritoneum along the lateral paracolic gutters.

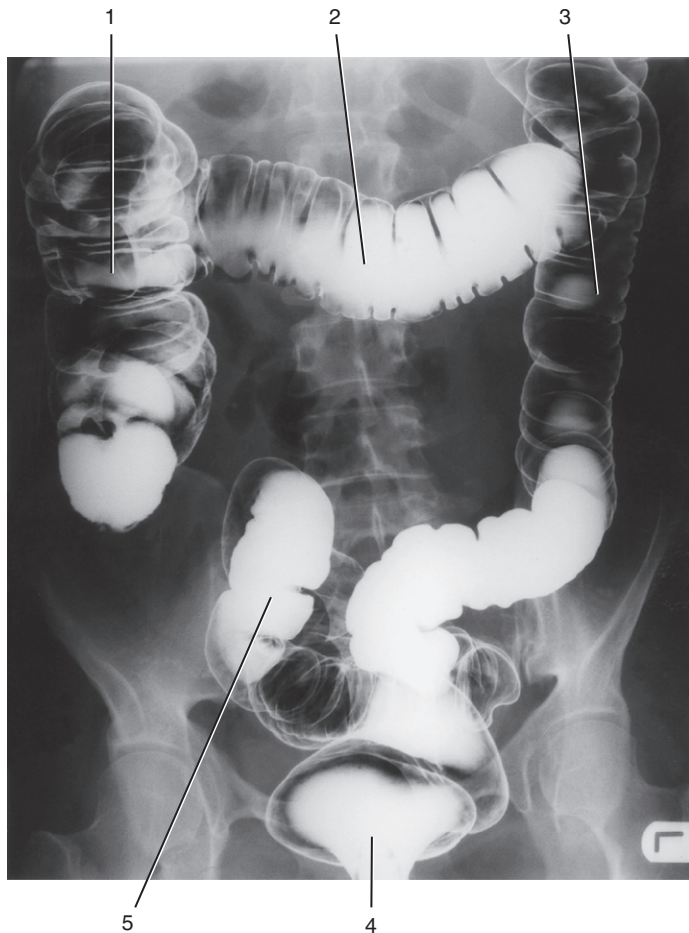
Figure from Gray's Anatomy for Students, 3rd edition, p. 319.



BARIUM RADIOGRAPH: LARGE INTESTINE

90

Identify the indicated structures.



BARIUM RADIOGRAPH: LARGE INTESTINE

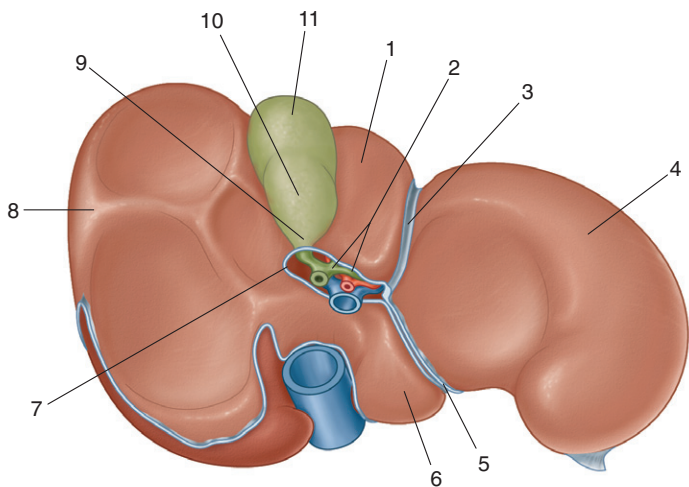


1. Ascending colon
2. Transverse colon
3. Descending colon
4. Rectum
5. Sigmoid colon

Figure from Gray's Basic Anatomy, p. 159.



Identify the indicated parts of the liver and gallbladder.





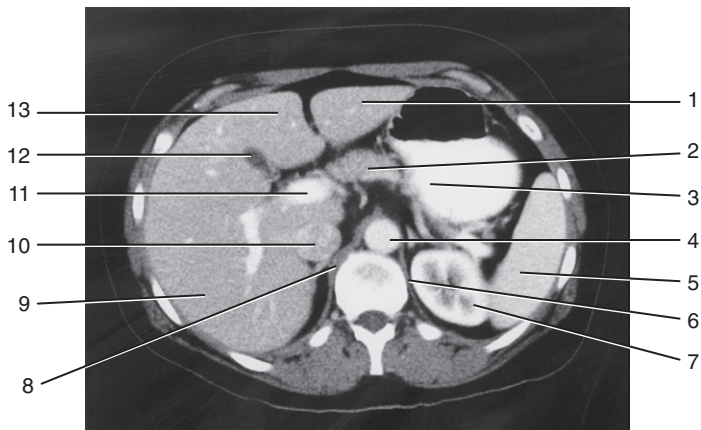
1. Quadrate lobe
2. Hepatic ducts
3. Fissure for ligamentum teres
4. Left lobe of liver
5. Fissure for ligamentum venosum
6. Caudate lobe
7. Porta hepatis
8. Right lobe of liver
9. Gallbladder—neck
10. Gallbladder—body
11. Gallbladder—fundus

IN THE CLINIC:

- The porta hepatis serves as the point of entry into the liver for the hepatic arteries and the portal vein and the exit point for the hepatic ducts.



Identify the indicated structures.



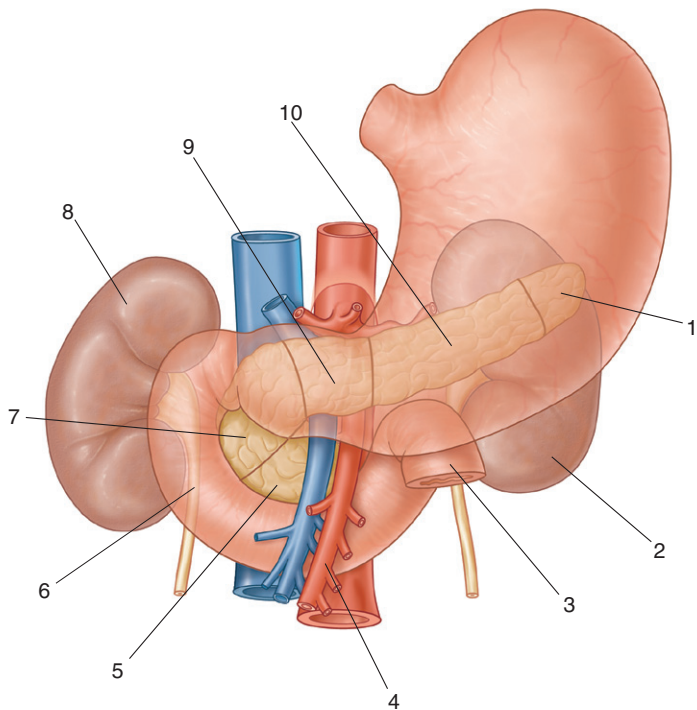


1. Left lobe of liver
2. Neck of pancreas
3. Stomach
4. Aorta
5. Spleen
6. Left crus
7. Left kidney
8. Right crus
9. Right lobe of liver
10. Inferior vena cava
11. Portal vein
12. Gallbladder
13. Quadrate lobe

Figure from Gray's Basic Anatomy, p. 166.



Identify the indicated structures.



PANCREAS



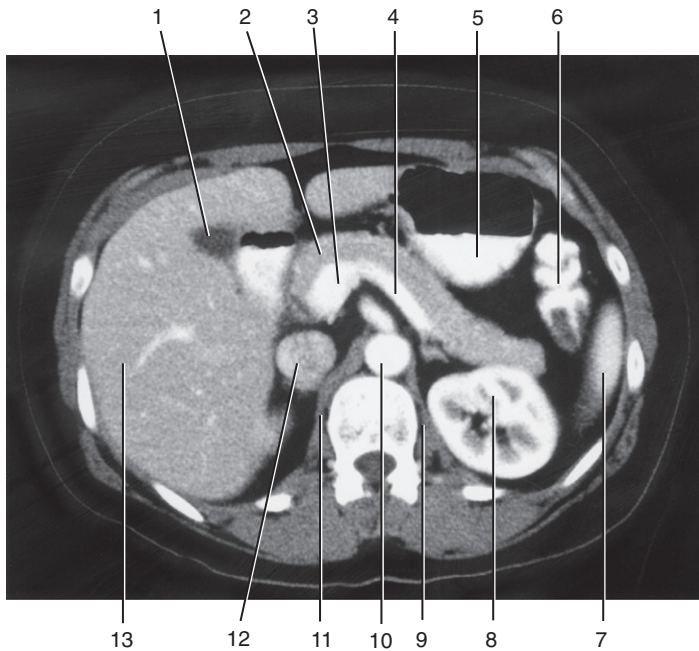
1. Pancreas—tail
2. Left kidney
3. Jejunum
4. Superior mesenteric artery
5. Uncinate process
6. Duodenum
7. Pancreas—head
8. Right kidney
9. Pancreas—neck
10. Pancreas—body

IN THE CLINIC:

- **The pancreas develops from ventral and dorsal diverticula from the foregut. The dorsal bud forms most of the head, neck, and body of the pancreas. If the ventral bud splits, the two segments may encircle and constrict the duodenum. This is referred to as an annular pancreas.**

Figure from Gray's Anatomy for Students, 3rd edition, p. 333.

Identify the indicated structures.



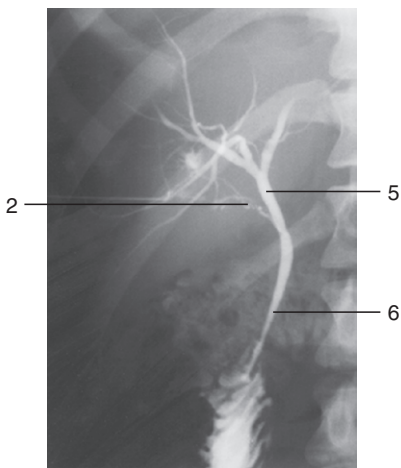
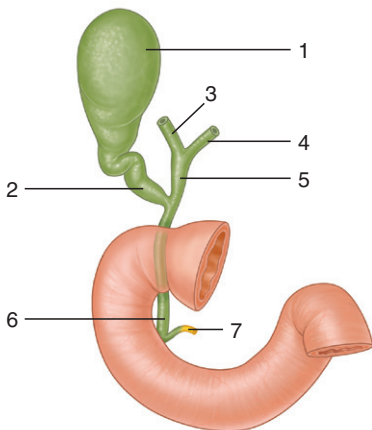


1. Gallbladder
2. Pancreas
3. Portal vein
4. Splenic vein
5. Stomach
6. Left colonic flexure
7. Spleen
8. Left kidney
9. Left crus
10. Aorta
11. Right crus
12. Inferior vena cava
13. Right lobe of liver

Figure from Gray's Basic Anatomy, p. 169.



Identify the indicated parts of the bile drainage system.



BILE DRAINAGE



1. Gallbladder
2. Cystic duct
3. Right hepatic duct
4. Left hepatic duct
5. Common hepatic duct
6. Bile duct
7. Main pancreatic duct

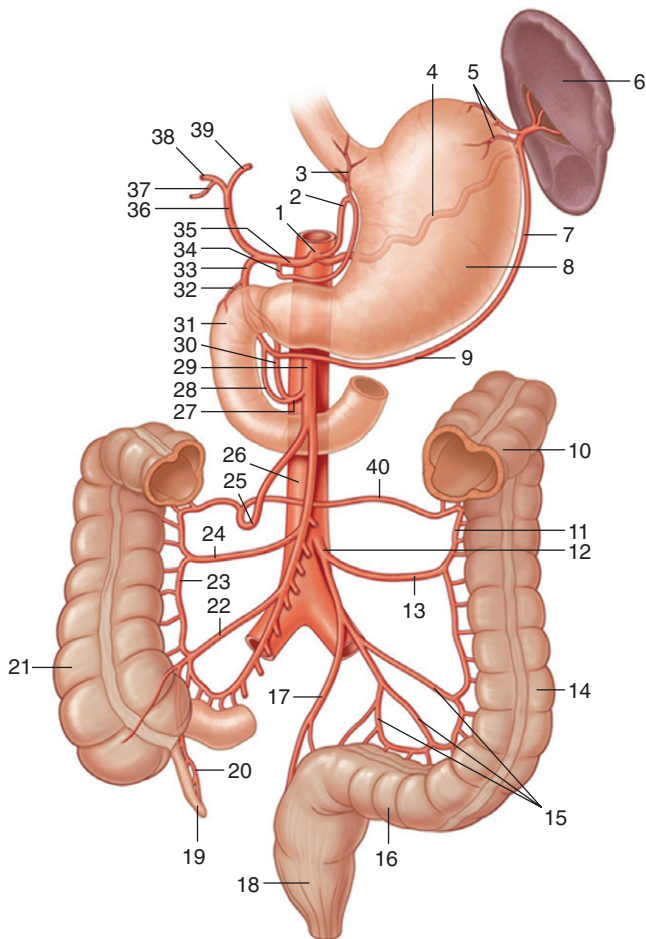
IN THE CLINIC:

- Occasionally, small gallstones pass into the bile duct and are trapped in the region of the sphincter of the ampulla, which obstructs the flow of bile into the duodenum. This produces jaundice. Gallstones may also lodge in the neck of the gallbladder. This prevents the gallbladder from emptying normally, and contractions of the gallbladder wall may produce severe pain.

Figure from Gray's Anatomy for Students, 3rd edition, p. 337.

ARTERIES:
ARTERIAL SUPPLY OF VISCERA

Identify the indicated arteries and structures.



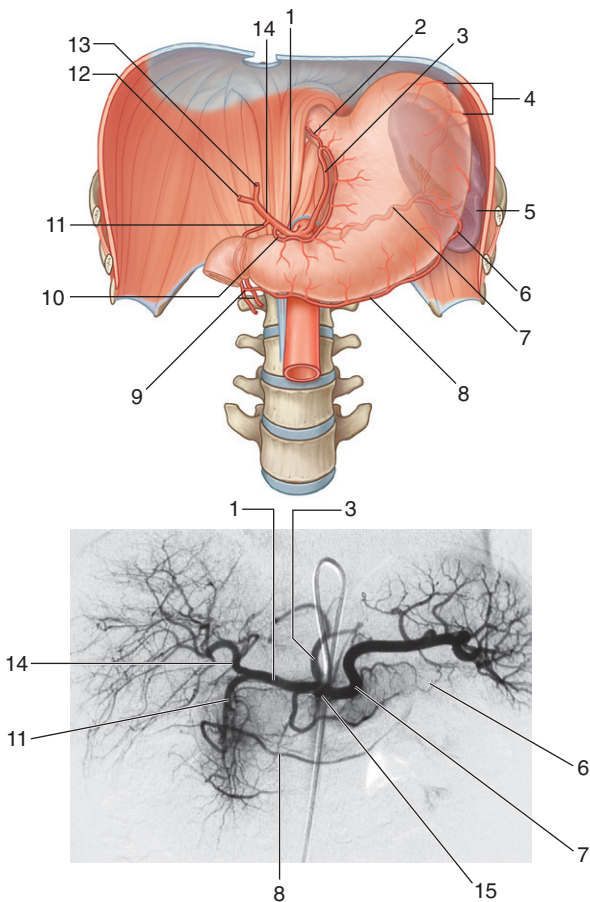
ARTERIES: ARTERIAL SUPPLY OF VISCERA



1. Celiac trunk
2. Left gastric artery
3. Esophageal artery
4. Splenic artery
5. Short gastric arteries
6. Spleen
7. Left gastro-omental artery
8. Stomach
9. Right gastro-omental artery
10. Transverse colon
11. Marginal artery
12. Inferior mesenteric artery
13. Left colic artery
14. Descending colon
15. Sigmoid arteries
16. Sigmoid colon
17. Superior rectal artery
18. Rectum
19. Appendix
20. Appendicular artery
21. Ascending colon
22. Ileocolic artery
23. Marginal artery
24. Right colic artery
25. Middle colic artery
26. Abdominal aorta
27. Inferior pancreaticoduodenal artery
28. Anterior pancreaticoduodenal artery
29. Superior mesenteric artery
30. Posterior pancreaticoduodenal artery
31. Duodenum
32. Supraduodenal artery
33. Gastroduodenal artery
34. Right gastric artery
35. Common hepatic artery
36. Hepatic artery proper
37. Cystic artery
38. Right hepatic artery
39. Left hepatic artery
40. Marginal artery

Figure from Gray's Atlas of Anatomy, 2nd edition, p. 157.

Identify the indicated branches of the celiac trunk and associated structures.



ARTERIES: CELIAC TRUNK



1. Common hepatic artery
2. Esophageal branches
3. Left gastric artery
4. Short gastric arteries
5. Spleen
6. Left gastro-omental artery
7. Splenic artery
8. Right gastro-omental artery
9. Superior pancreaticoduodenal arteries
10. Right gastric artery
11. Gastroduodenal artery
12. Right hepatic artery
13. Left hepatic artery
14. Hepatic artery proper
15. Celiac trunk

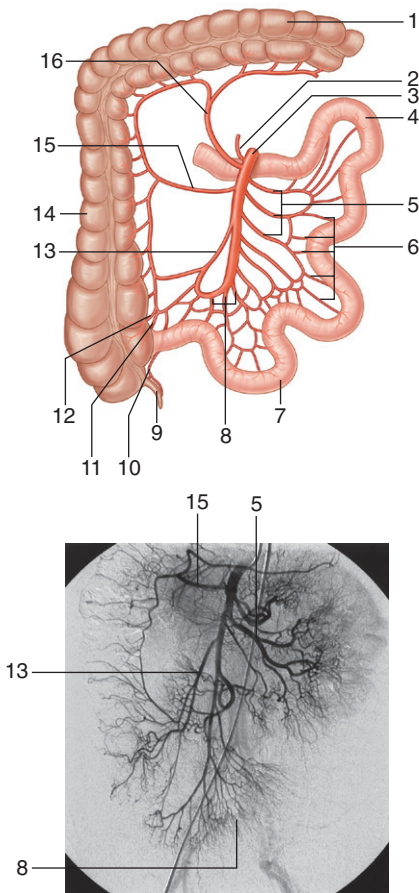
IN THE CLINIC:

- **The celiac trunk supplies the lower esophagus, stomach, duodenum (superior to the major duodenal papilla), liver, pancreas, gallbladder, and spleen.**

Figure from Gray's Anatomy for Students, 3rd edition, p. 345.



Identify the indicated branches of the superior mesenteric artery and associated structures.



ARTERIES: SUPERIOR MESENTERIC



1. Transverse colon
2. Inferior pancreaticoduodenal artery
3. Superior mesenteric artery
4. Jejunum
5. Jejunal arteries
6. Vasa recta
7. Ileum
8. Ileal arteries
9. Appendix
10. Appendicular artery
11. Posterior cecal artery
12. Anterior cecal artery
13. Iliocolic artery
14. Ascending colon
15. Right colic artery
16. Middle colic artery

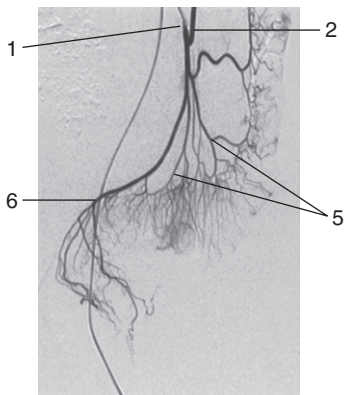
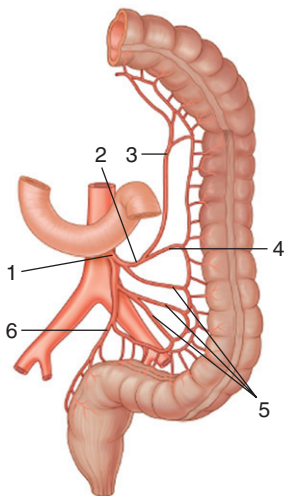
IN THE CLINIC:

- **The superior mesenteric artery supplies the duodenum (inferior to the major duodenal papilla), jejunum, ileum, appendix, cecum, ascending colon, and right (proximal) two thirds of the transverse colon.**

Figure from Gray's Anatomy for Students, 3rd edition, p. 349.



Identify the indicated branches of the inferior mesenteric artery.



ARTERIES: INFERIOR MESENTERIC



1. Inferior mesenteric artery
2. Left colic artery
3. Ascending branch of left colic artery
4. Descending branch of left colic artery
5. Sigmoid arteries
6. Superior rectal artery

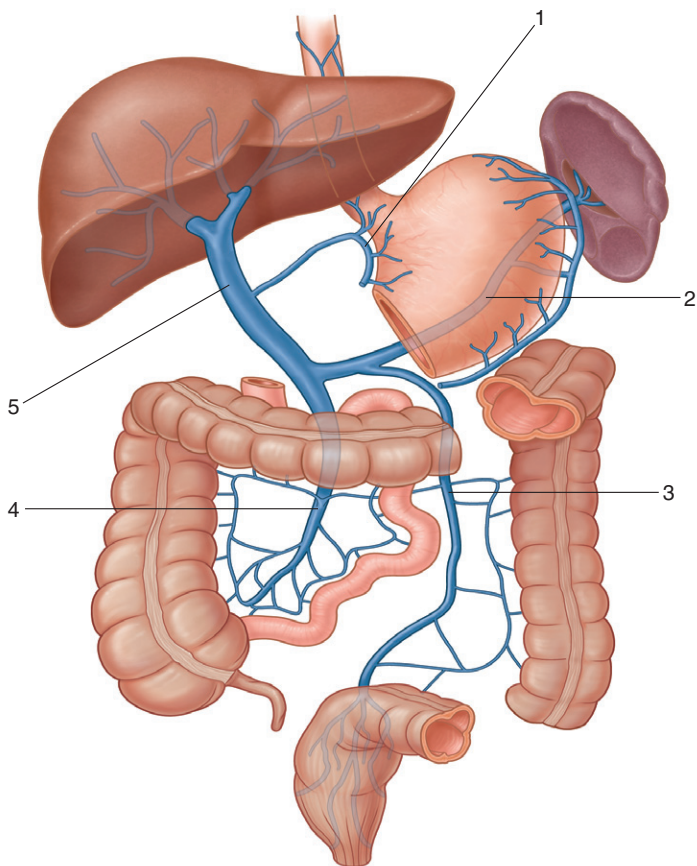
IN THE CLINIC:

- **The inferior mesenteric artery supplies the distal third of the transverse colon, the descending colon, the sigmoid colon, most of the rectum, and the upper part of the anal canal.**

Figure from Gray's Anatomy for Students, 3rd edition, p. 351.



Identify the indicated tributaries to the portal system.



VEINS: PORTAL SYSTEM



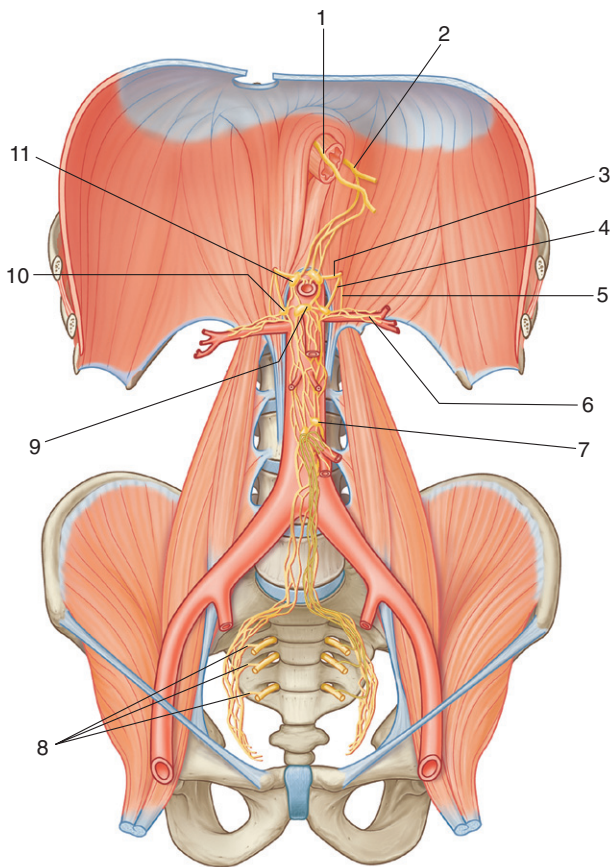
1. Left gastric vein
2. Splenic vein
3. Inferior mesenteric vein
4. Superior mesenteric vein
5. Portal vein

IN THE CLINIC:

- **Patients with hepatic cirrhosis develop increased pressure in the portal vein as a result of the increased resistance to blood flowing through the liver. This increased pressure allows the development of collateral channels that bypass the liver, forming portosystemic shunts. The largest of these are at the gastroesophageal junction, where the left gastric vein forms a portosystemic anastomosis (shunt) with the azygos venous system. Another portosystemic anastomosis occurs at the anus, where the superior rectal vein of the portal system anastomoses with the middle and inferior rectal veins of the systemic venous system. A further anastomosis occurs around the umbilicus on the anterior abdominal wall, where the paraumbilical veins anastomose with veins on the anterior abdominal wall.**

Figure from Gray's Anatomy for Students, 3rd edition, p. 355.

Identify the indicated structures supplying sympathetic and parasympathetic innervation to the abdominal portion of the gastrointestinal tract.





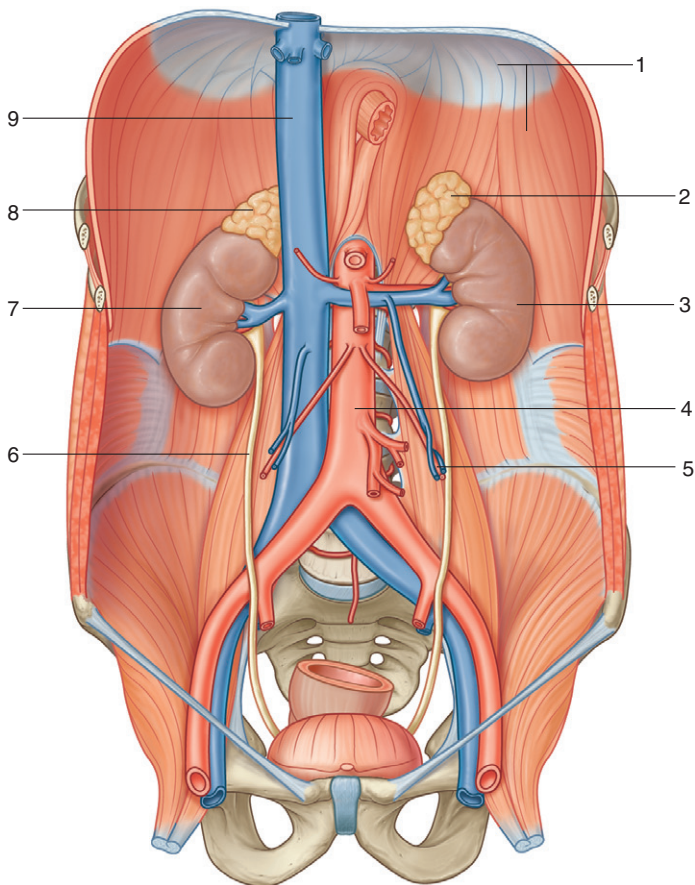
1. Anterior vagal trunk
2. Posterior vagal trunk
3. Greater splanchnic nerve
4. Lesser splanchnic nerve
5. Least splanchnic nerve
6. Renal plexus
7. Inferior mesenteric ganglion
8. Pelvic splanchnic nerves
9. Superior mesenteric ganglion
10. Aorticorenal ganglion
11. Celiac ganglion

IN THE CLINIC:

- **The abdominal prevertebral plexus receives preganglionic parasympathetic and visceral afferent fibers from the vagus nerves (X), preganglionic sympathetic and visceral afferent fibers from the thoracic and lumbar splanchnic nerves, and preganglionic parasympathetic fibers from the pelvic splanchnic nerves.**

Figure from Gray's Anatomy for Students, 3rd edition, p. 363.

Identify the indicated structures in the posterior abdominal region.



POSTERIOR ABDOMINAL REGION: OVERVIEW



1. Diaphragm
2. Left suprarenal gland
3. Left kidney
4. Abdominal aorta
5. Right gonadal vessels
6. Right ureter
7. Right kidney
8. Right suprarenal gland
9. Inferior vena cava

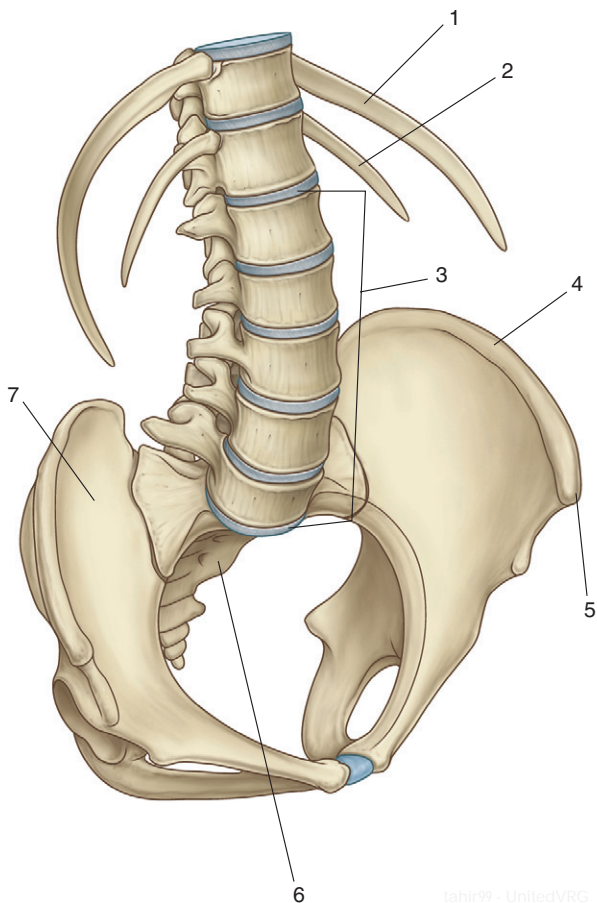
Figure from Gray's Anatomy for Students, 3rd edition, p. 366.



POSTERIOR ABDOMINAL REGION: BONES

103

Identify the indicated bones and bony landmarks of the posterior abdominal wall.



POSTERIOR ABDOMINAL REGION: BONES



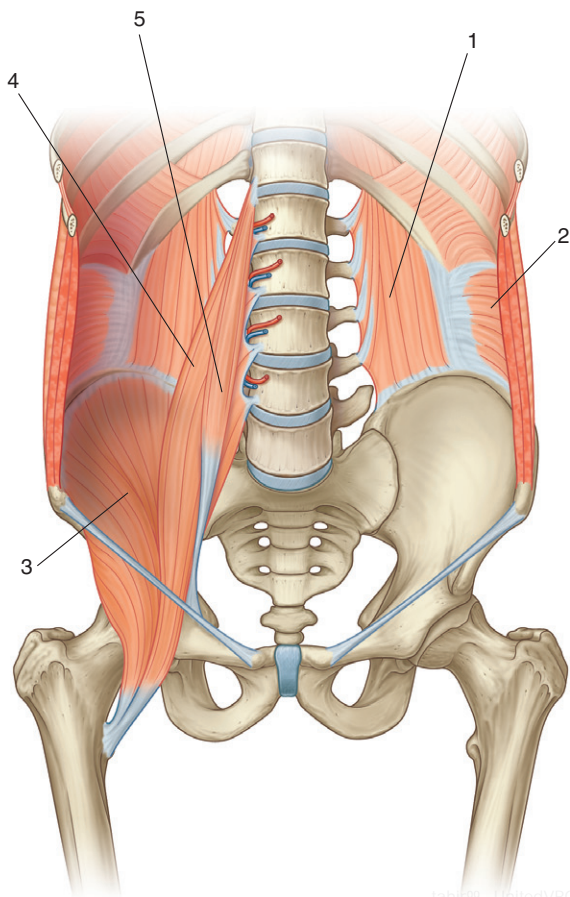
1. Rib XI
2. Rib XII
3. Lumbar vertebrae
4. Iliac crest
5. Anterior superior iliac spine
6. Sacrum
7. Ilium

IN THE CLINIC:

- **Projecting into the midline of the posterior abdominal area are the bodies of five lumbar vertebrae and their associated intervertebral discs. The prominence of these structures is due to the normal secondary curvature (a forward convexity) of this part of the vertebral column.**

Figure from Gray's Anatomy for Students, 3rd edition, p. 367.

Identify the indicated muscles of the posterior abdominal wall.



POSTERIOR ABDOMINAL REGION: MUSCLES



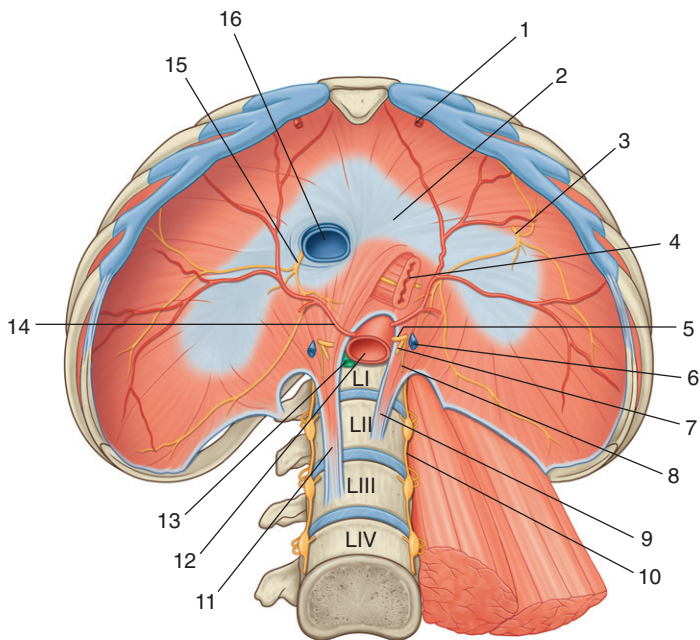
1. Quadratus lumborum muscle
2. Transversus abdominis muscle
3. Iliacus muscle
4. Psoas major muscle
5. Psoas minor muscle

IN THE CLINIC:

- The psoas muscle and its sheath arise from the lumbar vertebrae and the intervertebral discs between each vertebra. With certain infections, typically tuberculosis, the disc is preferentially affected. As the infection develops, it spreads anteriorly and anterolaterally into the psoas muscle sheath and may appear as a mass below the inguinal ligament in the femoral triangle.

Figure from Gray's Anatomy for Students, 3rd edition, p. 368.

Identify the indicated structures related to the diaphragm.



DIAPHRAGM



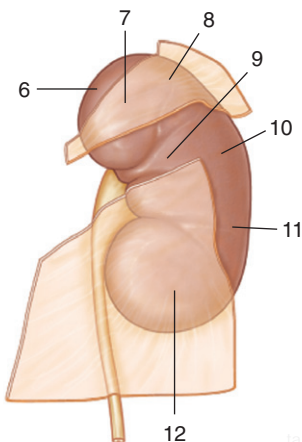
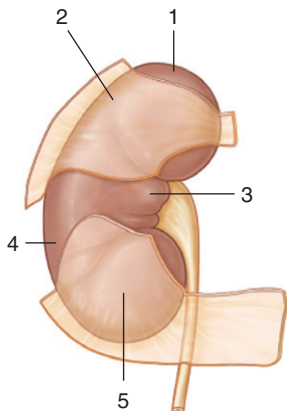
1. Superior epigastric artery
2. Central tendon
3. Left phrenic nerve
4. Esophagus with anterior and posterior vagal trunks
5. Greater splanchnic nerve
6. Hemi-azygos vein
7. Lesser splanchnic nerve
8. Least splanchnic nerve
9. Left crus
10. Sympathetic trunk
11. Right crus
12. Aorta
13. Thoracic duct
14. Inferior phrenic artery
15. Right phrenic nerve
16. Inferior vena cava

IN THE CLINIC:

- **At the level of the esophageal hiatus, the diaphragm may be lax, allowing the stomach to herniate into the posterior mediastinum. This may produce symptoms of acid reflux. Ulceration and bleeding may also occur.**

Figure from Gray's Anatomy for Students, 3rd edition, p. 3694.

Identify the structures related to the anterior surface of each kidney.



ANTERIOR RELATIONSHIPS OF KIDNEYS



1. Right suprarenal gland
2. Liver
3. Descending part of duodenum
4. Right colic flexure
5. Small intestine
6. Left suprarenal gland
7. Stomach
8. Spleen
9. Pancreas
10. Left colic flexure
11. Descending colon
12. Jejunum

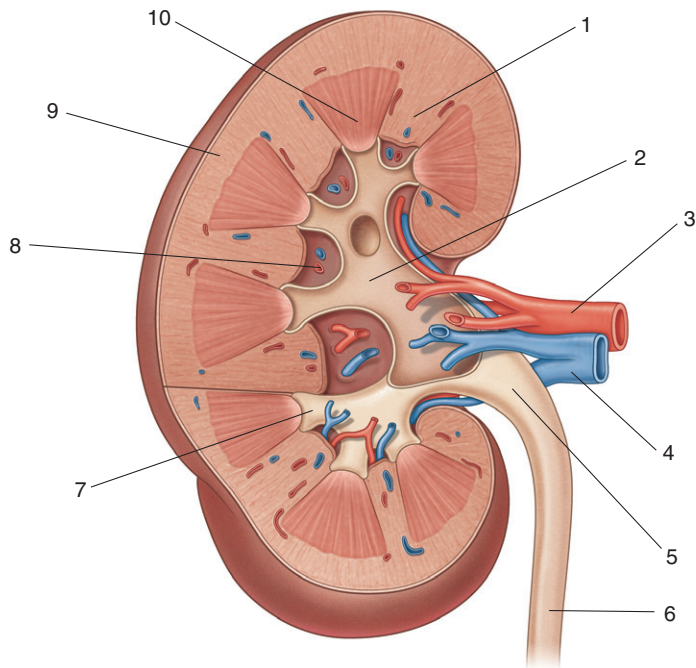
IN THE CLINIC:

- **The kidneys are retroperitoneal and lie on the posterior abdominal wall in the extraperitoneal connective tissue lateral to the vertebral column. In the supine position the kidneys extend from approximately vertebra LIII to vertebra TXII. The right kidney is somewhat lower than the left because of the position of the right lobe of the liver, which displaces it inferiorly.**

Figure from Gray's Anatomy for Students, 3rd edition, p. 374.



Identify the indicated internal structures of the kidney.



INTERNAL STRUCTURE OF THE KIDNEY



1. Renal column
2. Major calyx
3. Renal artery
4. Renal vein
5. Renal pelvis
6. Ureter
7. Minor calyx
8. Renal sinus
9. Renal cortex
10. Pyramid in renal medulla

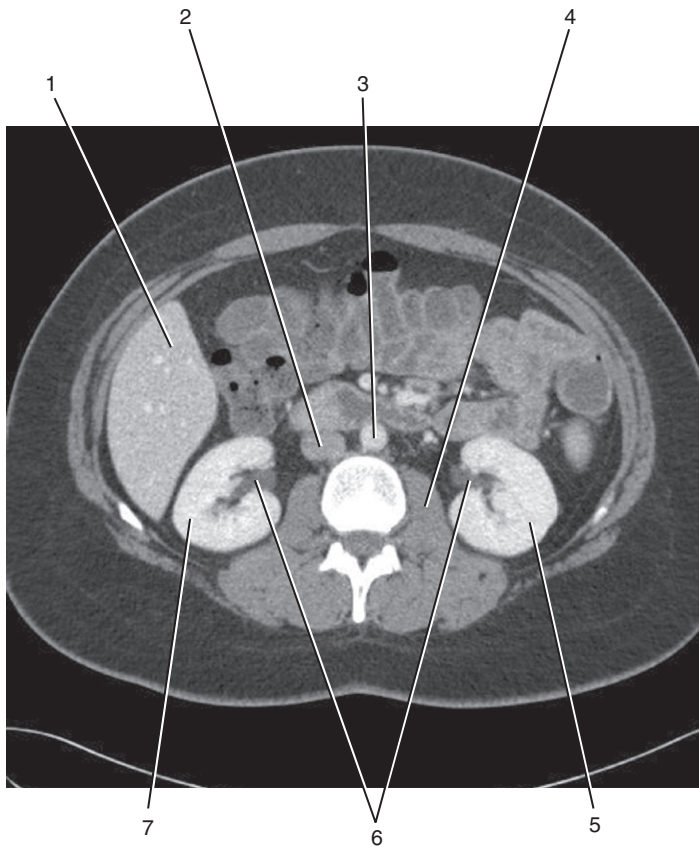
IN THE CLINIC:

- **Most kidney tumors are renal cell carcinomas. These tumors develop from the proximal tubular epithelium. Renal cells grow outward, invading the fat and fascia surrounding the kidney. They may also grow along the renal vein entering the inferior vena cava and can grow into the right atrium.**

Figure from Gray's Anatomy for Students, 3rd edition, p. 377.



Identify the indicated structures.

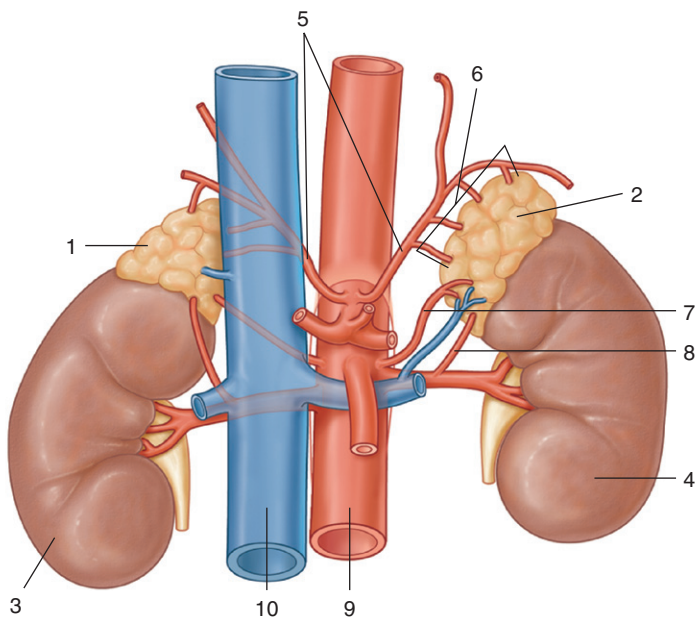




1. Liver
2. Inferior vena cava
3. Abdominal aorta
4. Psoas major muscle
5. Left kidney
6. Renal pelvis
7. Right kidney

Figure from Gray's Basic Anatomy, p. 194.

Identify indicated structures related to the renal and suprarenal glands.





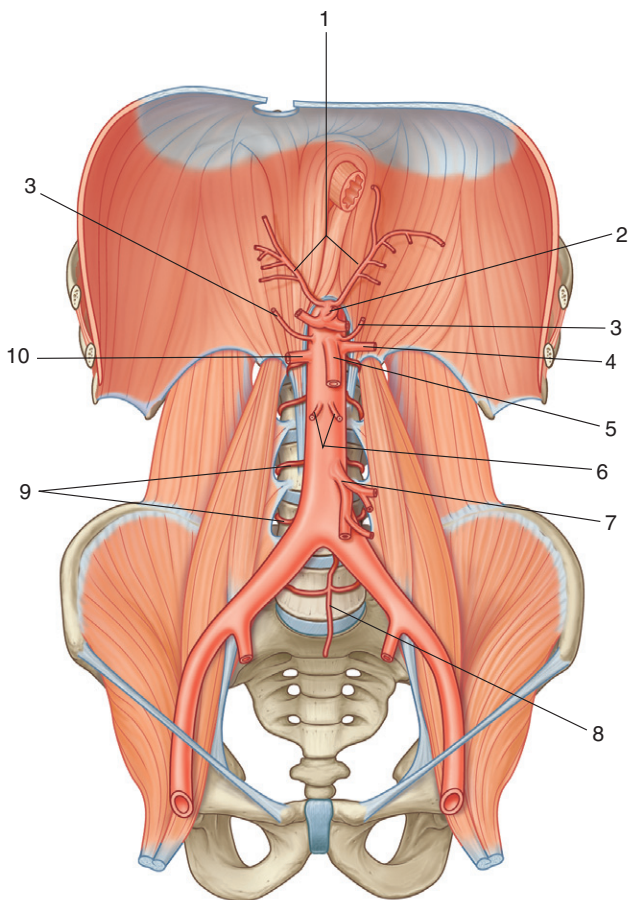
1. Right suprarenal gland
2. Left suprarenal gland
3. Right kidney
4. Left kidney
5. Inferior phrenic arteries
6. Superior suprarenal arteries
7. Middle suprarenal artery
8. Inferior suprarenal artery
9. Abdominal aorta
10. Inferior vena cava

IN THE CLINIC:

- **The renal arteries are lateral branches of the abdominal aorta. Accessory renal vessels occur in approximately 20% of normal individuals. These vessels tend to arise inferior to the superior mesenteric artery between vertebrae LI and LII. As each artery approaches the renal hilum it divides into anterior and posterior branches.**
- **The arterial supply to each suprarenal gland is from three vessels: the inferior phrenic artery, the abdominal aorta, and the renal artery.**

Figure from Gray's Anatomy for Students, 3rd edition, p. 378.

Identify the indicated branches of the abdominal aorta.



ABDOMINAL AORTA



1. Inferior phrenic arteries
2. Celiac trunk
3. Middle suprarenal artery
4. Left renal artery
5. Superior mesenteric artery
6. Testicular/ovarian arteries
7. Inferior mesenteric artery
8. Median sacral artery
9. Lumbar arteries
10. Right renal artery

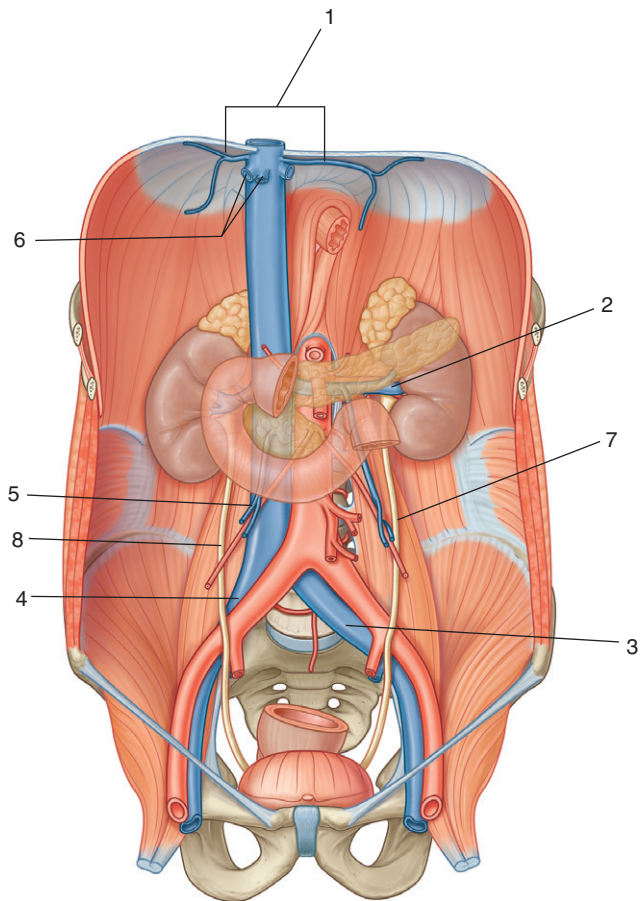
IN THE CLINIC:

- The abdominal aorta extends from the lower level of vertebra TXII to the lower level of vertebra LIV, where it divides into the right and left common iliac arteries. Throughout its course its gives off visceral branches supplying organs, posterior branches supplying the diaphragm and body wall, and terminal branches.
- An abdominal aortic aneurysm is a dilation of the aorta usually occurring below the level of the renal arteries. If left untreated, it will continue to enlarge and may subsequently rupture.

Figure from Gray's Anatomy for Students, 3rd edition, p. 387.



Identify the indicated tributaries to the inferior vena cava.



INFERIOR VENA CAVA



1. Inferior phrenic veins
2. Left renal vein
3. Left common iliac vein
4. Right common iliac vein
5. Right testicular/ovarian vein
6. Hepatic veins
7. Left ureter
8. Right ureter

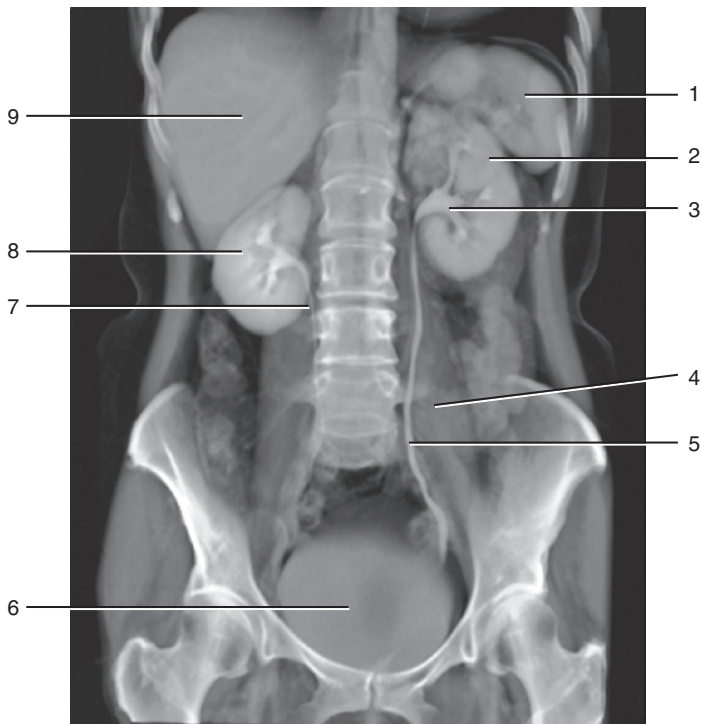
IN THE CLINIC:

- The anterior surface of the inferior vena cava is crossed by the right common iliac artery, the root of the mesentery, the right testicular or ovarian artery, the inferior part of the duodenum, the head of the pancreas, the superior part of the duodenum, the bile duct, the portal vein, and the liver.

Figure from Gray's Anatomy for Students, 3rd edition, p. 390.



Identify the indicated structures.



UROGRAM: PATHWAY OF URETER

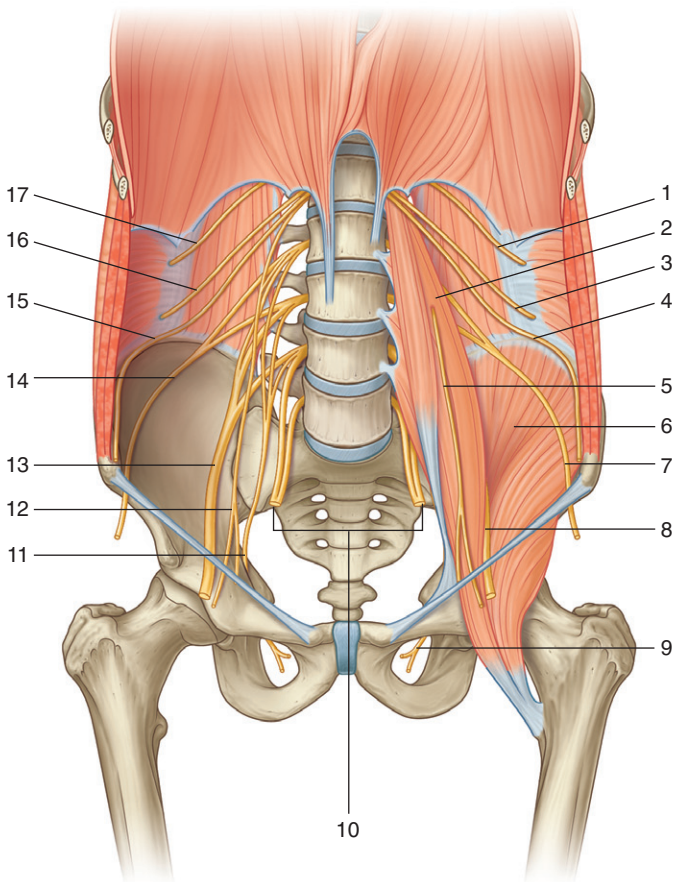


1. Spleen
2. Left kidney
3. Renal pelvis
4. Psoas major
5. Left ureter
6. Bladder
7. Right ureter
8. Right kidney
9. Liver

Figure from Gray's Basic Anatomy, p. 194.



Identify the indicated parts of the lumbar plexus and related structures.



LUMBAR PLEXUS



1. Subcostal nerve (T12)
2. Psoas major muscle
3. Iliohypogastric nerve (L1)
4. Ilio-inguinal nerve (L1)
5. Genitofemoral nerve (L1, L2)
6. Iliacus muscle
7. Lateral cutaneous nerve of thigh (L2, L3)
8. Femoral nerve (L2 to L4)
9. Obturator nerve (L2 to L4)
10. Lumbosacral trunks (L4, L5)
11. Obturator nerve
12. Genitofemoral nerve
13. Femoral nerve
14. Lateral cutaneous nerve of thigh
15. Ilio-inguinal nerve
16. Iliohypogastric nerve
17. Subcostal nerve

IN THE CLINIC:

- The lumbar plexus is formed by the anterior rami of nerves L1 to L3, most of L4, and a branch from T12. It forms in the substance of the psoas major muscle, and its branches emerge through the substance of this muscle.

Figure from Gray's Anatomy for Students, 3rd edition, p. 392.



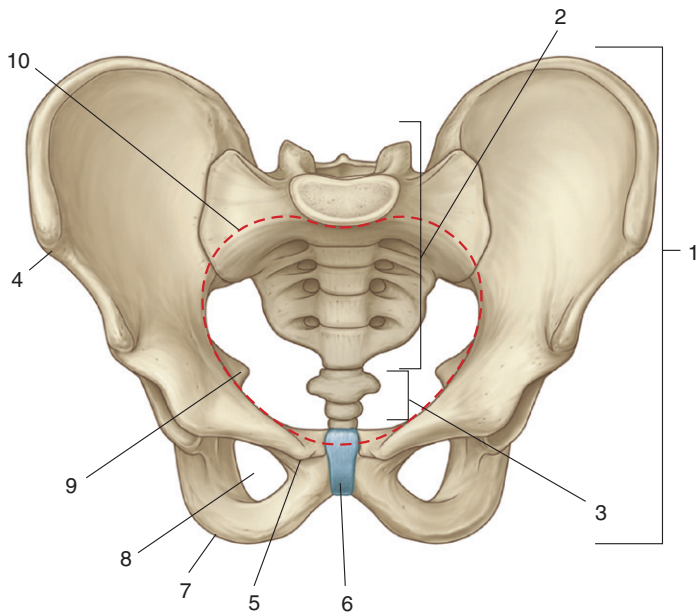
SECTION 5: PELVIS AND PERINEUM

- 114. Pelvis
- 115. Pelvic Bone
- 116. Ligaments
- 117. Muscles: Pelvic Diaphragm and Lateral Wall
- 118. Perineal Membrane and Deep Perineal Pouch
- 119. Viscera: Female Overview
- 120. Viscera: Male Overview
- 121. Male Reproductive System
- 122. Female Reproductive System
- 123. Uterus and Uterine Tubes
- 124. Sacral Plexus
- 125. Internal Iliac Posterior Trunk
- 126. Internal Iliac Anterior Trunk
- 127. Female Perineum
- 128. Male Perineum
- 129. Anal Triangle Cross Section
- 130. Superficial Perineal Pouch: Muscles
- 131. MRI: Male Pelvic Cavity and Perineum
- 132. Deep Perineal Pouch: Muscles
- 133. MRI: Female Pelvic Cavity and Perineum





Identify the indicated structures.





1. Pelvic bone
2. Sacrum
3. Coccyx
4. Anterior superior iliac spine
5. Pubic tubercle
6. Pubic symphysis
7. Ischial tuberosity
8. Obturator foramen
9. Ischial spine
10. Pelvic inlet

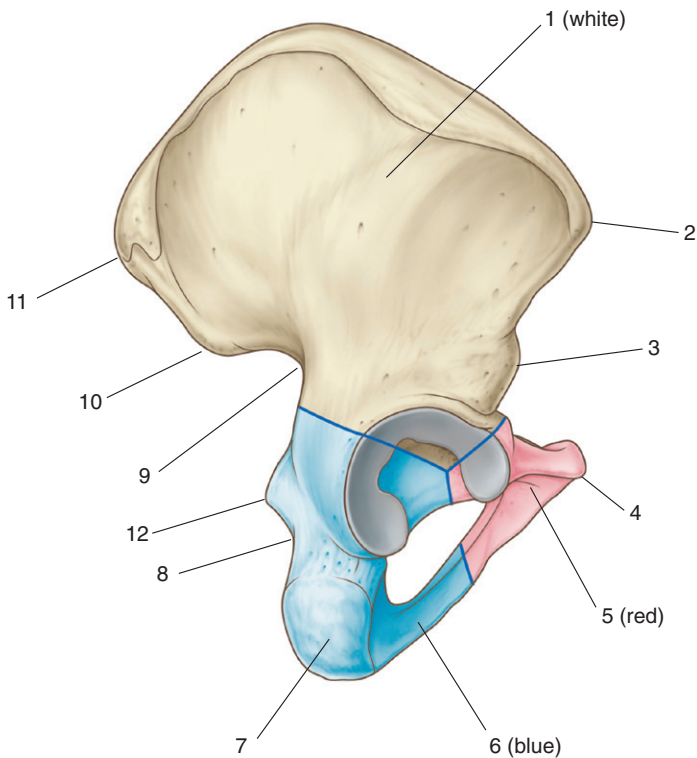
IN THE CLINIC:

- **The pelvic inlet is ringed by bone and joints. During childbirth, the infant must pass from the abdomen and into the pelvis through the pelvic inlet.**

Figure from Gray's Anatomy for Students, 3rd edition, p. 426.



Identify the indicated structures.



PELVIC BONE



1. Ilium
2. Anterior superior iliac spine
3. Anterior inferior iliac spine
4. Pubic tubercle
5. Pubis
6. Ischium
7. Ischial tuberosity
8. Lesser sciatic notch
9. Greater sciatic notch
10. Posterior inferior iliac spine
11. Posterior superior iliac spine
12. Ischial spine

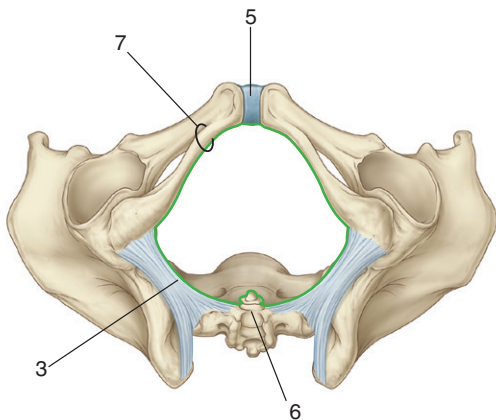
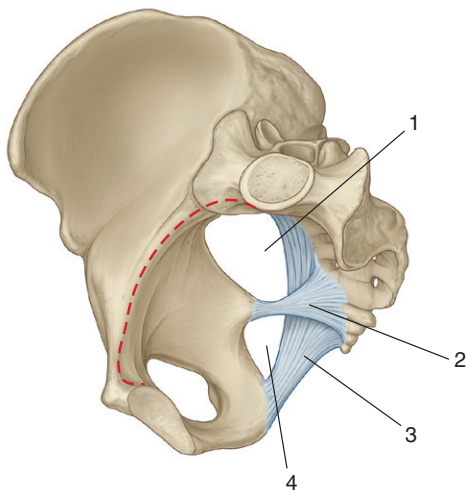
IN THE CLINIC:

- **Depending on location, fractures of the pelvic bone can affect the function of structures in the abdomen, pelvis, lower limb, and perineum.**

Figure from Gray's Anatomy for Students, 3rd edition, p. 443.



Identify the indicated structures.



LIGAMENTS



1. Greater sciatic foramen
2. Sacrospinous ligament
3. Sacrotuberous ligament
4. Lesser sciatic foramen
5. Pubic symphysis
6. Coccyx
7. Inferior pubic ramus

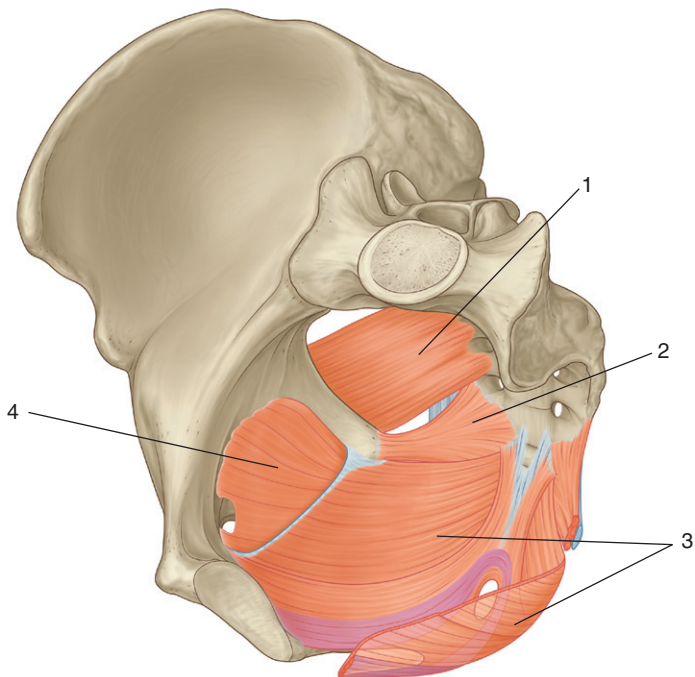
IN THE CLINIC:

- The margin of the pelvic outlet is formed by the pubic symphysis anteriorly and the coccyx posteriorly and on each side by the ischiopubic ramus, the ischial tuberosity, and the sacrotuberous ligament. The pubic symphysis, the ischial tuberosities, and the coccyx can be palpated on a patient. During childbirth, the infant passes through the pelvic outlet. The margins of the pelvic outlet also form the margins of the perineum.

Figure from Gray's Anatomy for Students, 3rd edition, pp. 427-428.



Identify the indicated muscles.



MUSCLES: PELVIC DIAPHRAGM AND LATERAL WALL



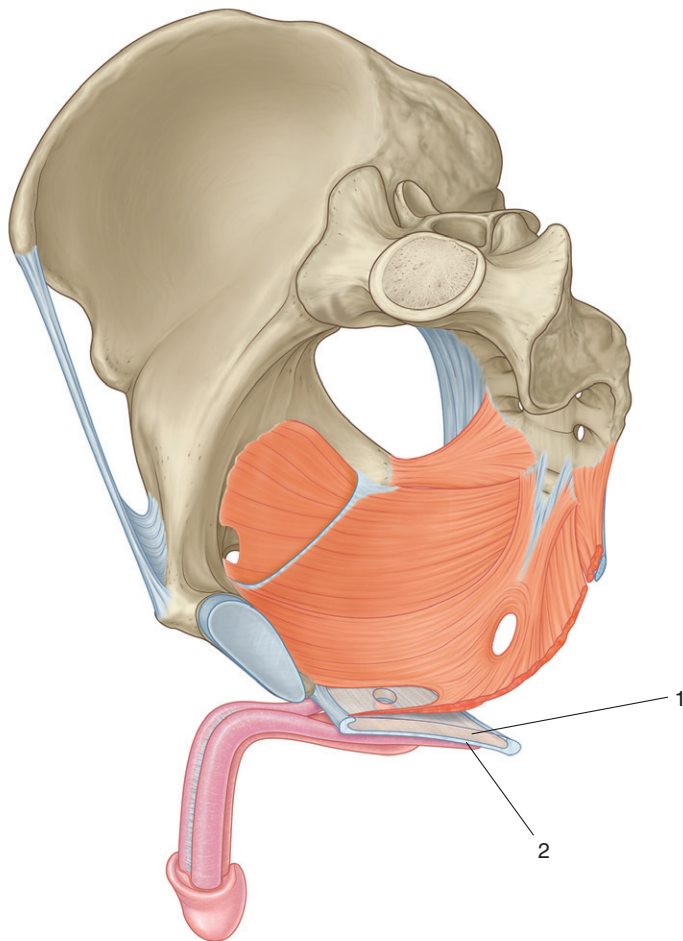
1. Piriformis muscle
2. Coccygeus muscle
3. Levator ani muscles
4. Obturator internus muscle

IN THE CLINIC:

- **The levator ani muscles form the pelvic diaphragm. Reduced motor control of the levator ani muscles contributes to bowel incontinence through loss of the “puborectal sling” function of the puborectalis component of the levator ani muscle.**

Figure from Gray's Anatomy for Students, 3rd edition, p. 455.

Identify the indicated structures.



PERINEAL MEMBRANE AND DEEP PERINEAL POUCH



1. Deep perineal pouch
2. Perineal membrane

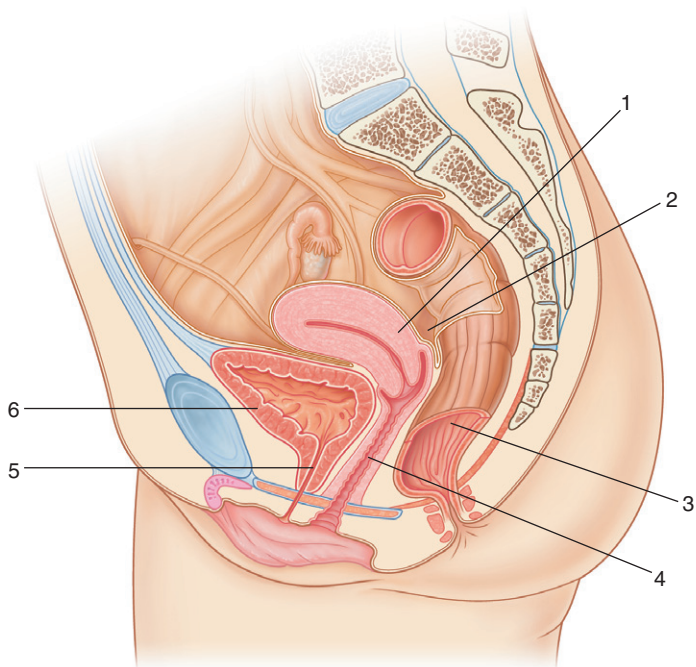
IN THE CLINIC:

- **The perineal membrane and structures in the deep perineal pouch reinforce the anterior part of the pelvic floor and therefore contribute to the support of pelvic viscera. In women the pelvic floor is weakened during childbirth.**

Figure from Gray's Anatomy for Students, 3rd edition, p. 458.



Identify the indicated structures.





1. Uterus
2. Rectouterine pouch
3. Rectum
4. Vagina
5. Urethra
6. Bladder

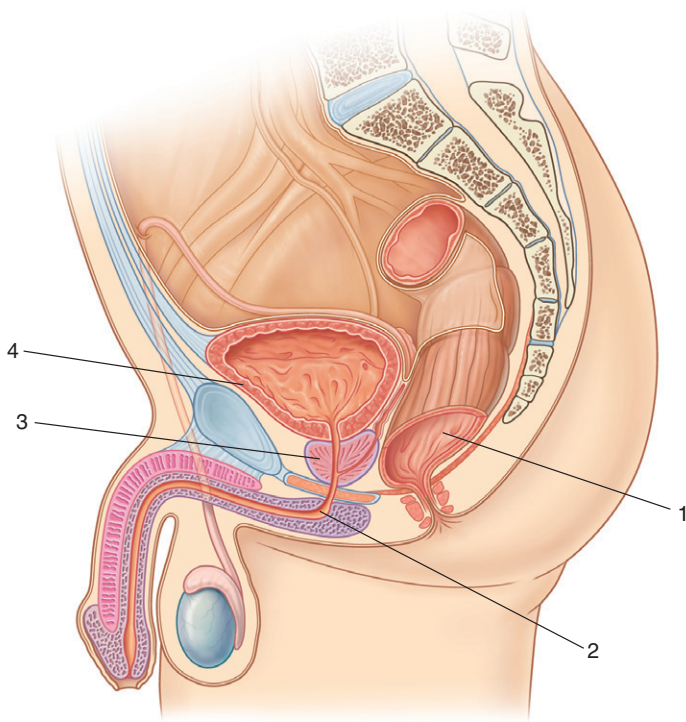
IN THE CLINIC:

- **In women, access to the pelvic cavity can be achieved by passing a needle through the posterior fornix of the vagina and into the rectouterine pouch.**

Figure from Gray's Anatomy for Students, 3rd edition, p. 424.



Identify the indicated structures.





1. Rectum
2. Urethra
3. Prostate
4. Bladder

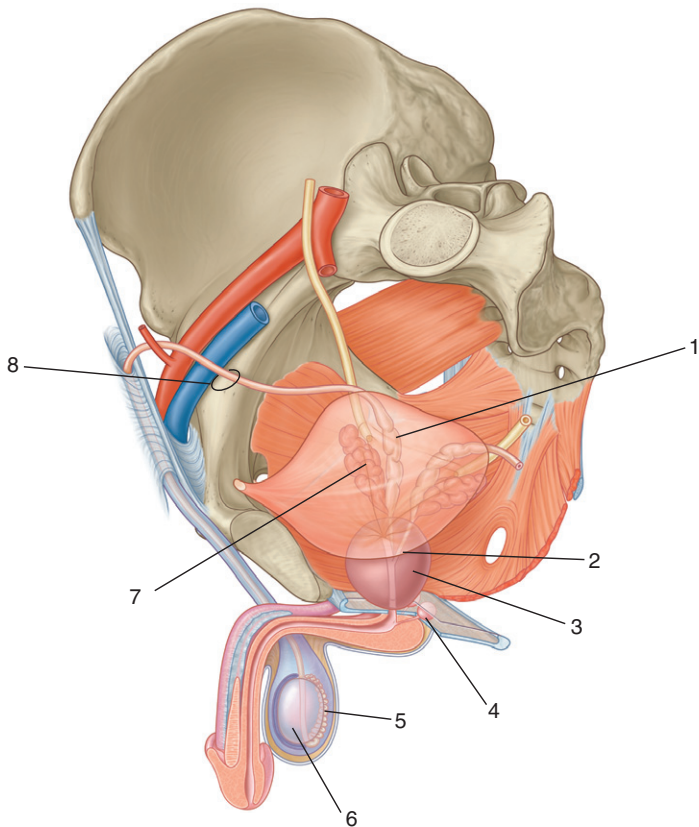
IN THE CLINIC:

- **In men the prostate lies directly anterior to the rectum in the pelvis. A physician can assess the size and texture of the gland in a patient by doing a digital rectal examination.**

Figure from Gray's Anatomy for Students, 3rd edition, p. 424.



Identify the indicated structures.





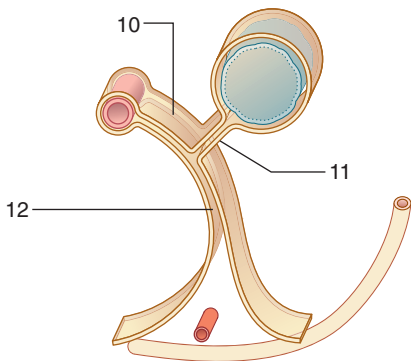
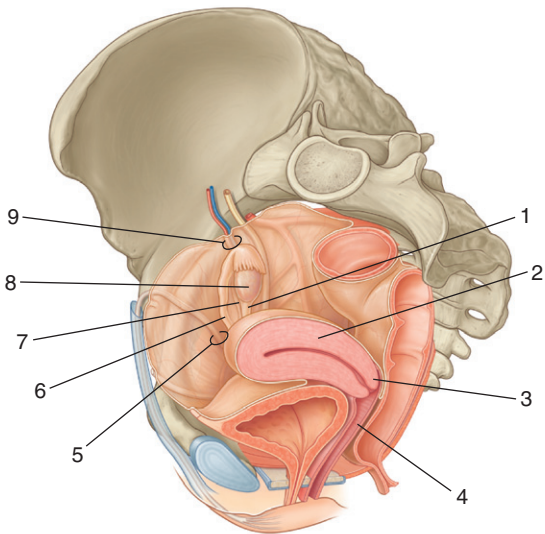
1. Ampulla of ductus deferens
2. Ejaculatory duct
3. Prostate
4. Bulbourethral gland
5. Epididymis
6. Testis
7. Seminal vesicle
8. Ductus deferens

IN THE CLINIC:

- The urethra passes through the prostate gland. Enlargement of the gland due to a pathologic process (cancer, hypertrophy) can impede urine flow.
- Autonomic nerves that supply the erectile tissues in the perineum pass around the sides of the prostate gland in the pelvis. Removal of the prostate gland can lead to impotence.
- Vasectomy (dividing and ligating the ductus deferens at a point between the testis and superficial inguinal ring) is one method of birth control.

Figure from Gray's Anatomy for Students, 3rd edition, p. 471.

Identify the indicated structures.



FEMALE REPRODUCTIVE SYSTEM



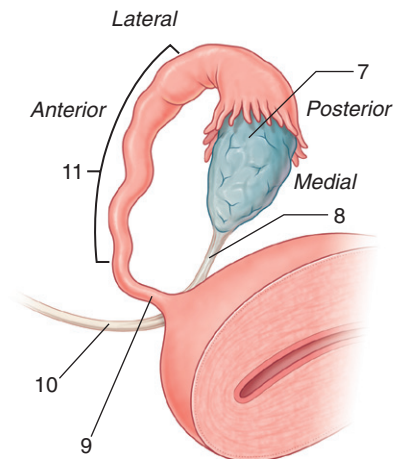
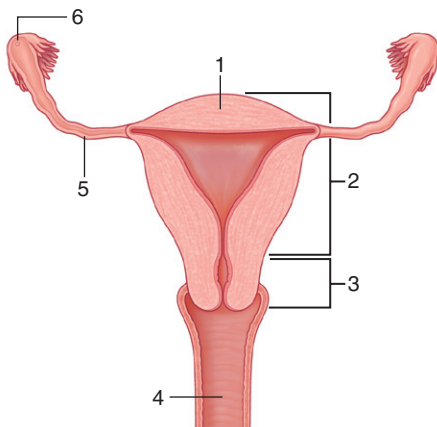
1. Ligament of ovary
2. Uterus
3. Cervix
4. Vagina
5. Round ligament of uterus
6. Uterine tube
7. Mesovarium
8. Ovary
9. Suspensory ligament of ovary
10. Mesosalpinx
11. Mesovarium
12. Mesometrium

IN THE CLINIC:

- During ovulation, an ovum is released into the abdominal cavity and must be moved into the abdominal opening of the uterine tube. If the ovum is fertilized before it enters the uterine tube, it can implant and undergo development on the bowel, leading to one form of ectopic pregnancy.

Figures from Gray's Anatomy for Students, 3rd edition, pp. 476 and 484.

Identify the indicated features of the uterus and the related structures.





1. Fundus
2. Body
3. Cervix
4. Vagina
5. Uterine tube
6. Position of opening of uterine tube
7. Ovary
8. Ligament of ovary
9. Isthmus of uterine tube
10. Round ligament of uterus
11. Ampulla

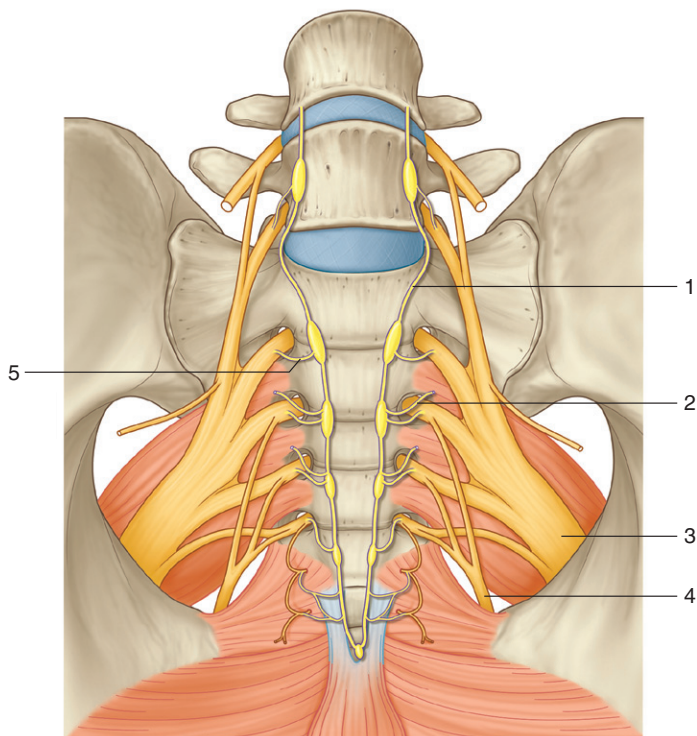
IN THE CLINIC:

- During pregnancy the uterus dramatically expands into the abdomen.
- Blockage of uterine tubes is one cause of infertility in women.
- Tubal ligation is one method of birth control.

Figure from Gray's Anatomy for Students, 3rd edition, pp. 477-478.



Identify the indicated nerves.



SACRAL PLEXUS



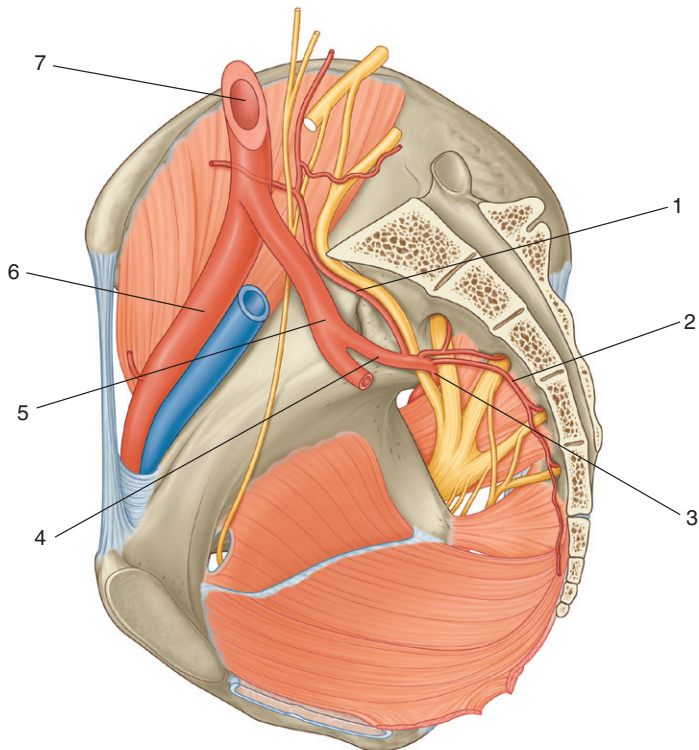
1. Sympathetic trunk
2. Sacral splanchnic nerve to inferior hypogastric plexus
3. Sciatic nerve
4. Pudendal nerve
5. Gray ramus communicans

IN THE CLINIC:

- **Lesions of the sympathetic trunks in the lower lumbar region lead mainly to loss of sympathetic output into sacral spinal nerves, not to loss of sympathetic innervation of pelvic viscera, which is derived mainly from pelvic extensions of the prevertebral plexus.**

Figure from Gray's Anatomy for Students, 3rd edition, p. 488.

Identify the indicated arteries.



INTERNAL ILIAC POSTERIOR TRUNK

1. Iliolumbar
2. Lateral sacral
3. Superior gluteal
4. Posterior trunk of internal iliac
5. Internal iliac
6. External iliac
7. Common iliac

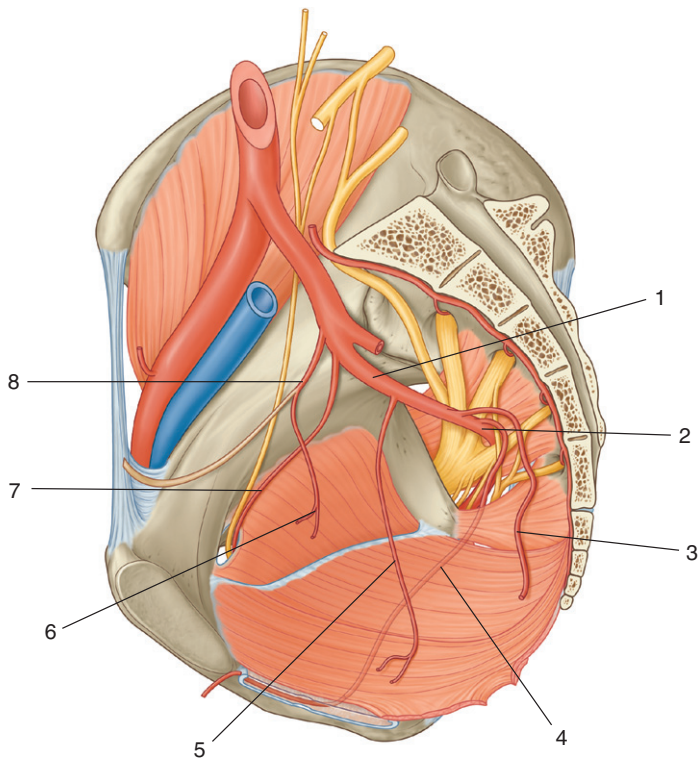
IN THE CLINIC:

- **Problems with the external iliac artery manifest in the lower limb. Problems with the internal iliac artery manifest in the pelvis, gluteal region, and perineum.**

Figure from Gray's Anatomy for Students, 3rd edition, p. 495.



Identify the indicated arteries.



INTERNAL ILIAC ANTERIOR TRUNK

1. Anterior trunk of internal iliac
2. Inferior gluteal
3. Middle rectal
4. Internal pudendal
5. Inferior vesicle
6. Superior vesicle
7. Obturator
8. Umbilical

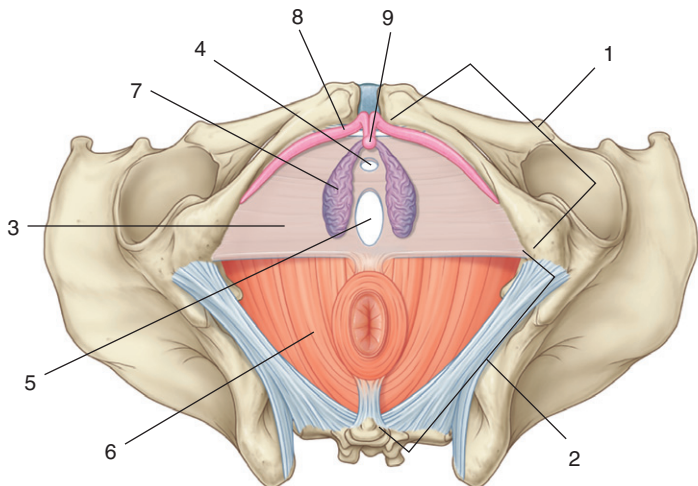
IN THE CLINIC:

- **Erectile tissues in the perineum receive their blood supply through the internal pudendal artery. Reduced blood flow through the internal pudendal artery, often a result of vascular disease in the aorta or internal iliac artery, can lead to erectile dysfunction.**

Figure from Gray's Anatomy for Students, 3rd edition, p. 497.



Identify the indicated regions and structures.



FEMALE PERINEUM



1. Urogenital triangle
2. Anal triangle
3. Perineal membrane
4. Opening for urethra in perineal membrane
5. Opening for vagina in perineal membrane
6. Levator ani muscle
7. Bulb of vestibule
8. Corpus cavernosum of clitoris
9. Glans clitoris

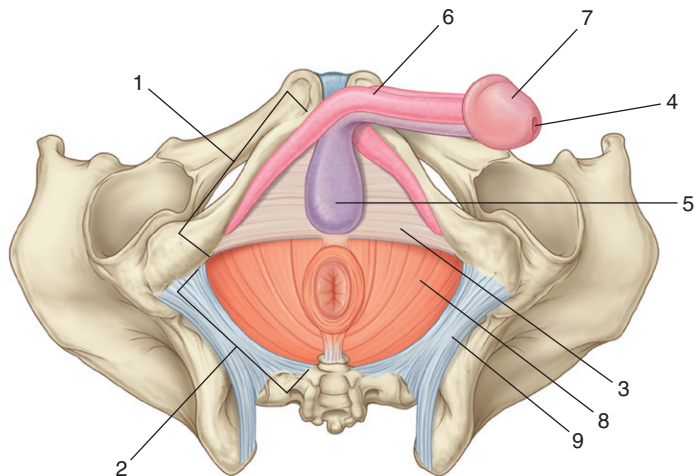
IN THE CLINIC:

- **During the physical examination of a patient, the margins of the perineum can be established by palpating the ischial tuberosities, the coccyx, and the pubic symphysis.**

Figure from Gray's Anatomy for Students, 3rd edition, p. 431.



Identify the indicated regions and structures.





1. Urogenital triangle
2. Anal triangle
3. Perineal membrane
4. External urethral orifice
5. Bulb of penis
6. Corpus cavernosum of penis
7. Glans penis
8. Levator ani muscle
9. Sacrotuberous ligament

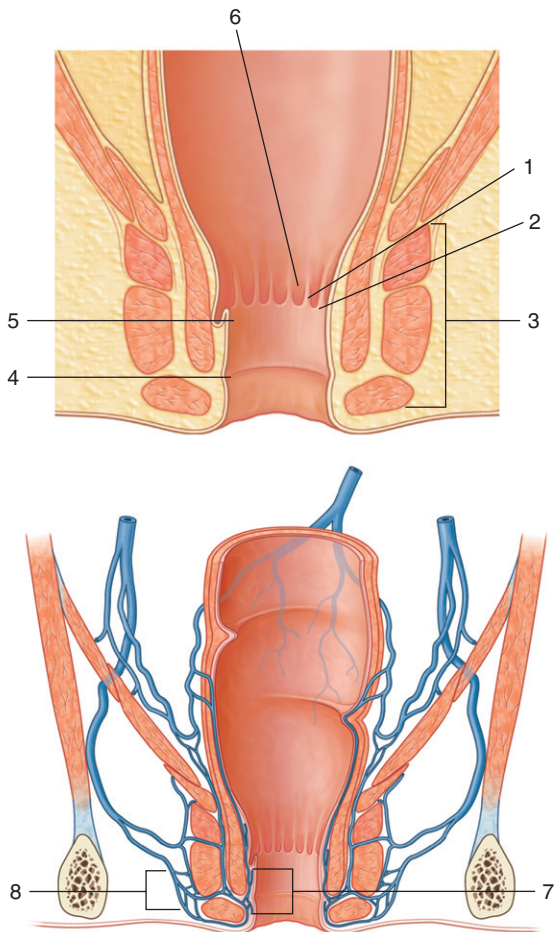
IN THE CLINIC:

- **In severe injuries of the pelvis, erectile tissues in the perineum can be torn or fractured.**

Figure from Gray's Anatomy for Students, 3rd edition, p. 431.



Identify the indicated structures.



ANAL TRIANGLE CROSS SECTION



1. Anal column
2. Anal valve
3. External anal sphincter
4. White line
5. Pectinate line
6. Anal sinus
7. Internal rectal plexus of veins
8. External rectal plexus of veins

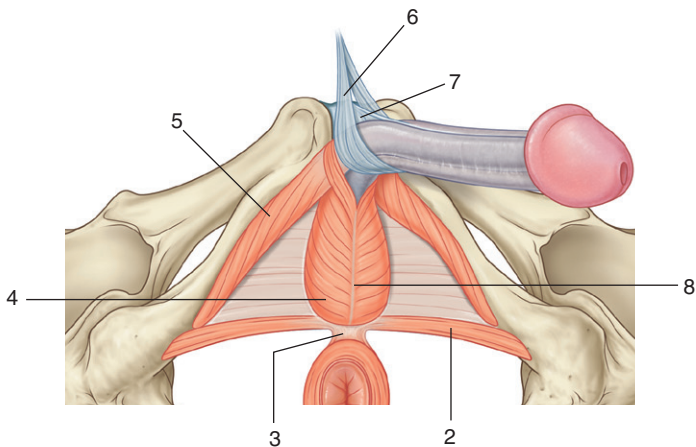
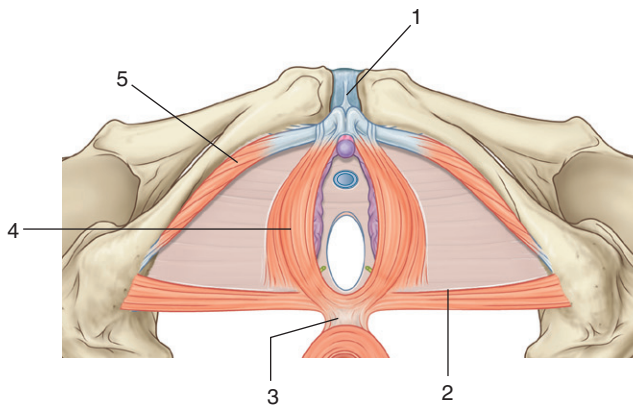
IN THE CLINIC:

- **Enlargement of veins in the external and internal rectal plexuses are external and internal hemorrhoids, respectively.**
- **Venous plexuses around the anal canal are one of the sites where veins draining into the caval system and those draining into the hepatic portal system interconnect. Anorectal varices (venous enlargements) can be a sign of portal hypertension.**

Figure from Gray's Anatomy for Students, 3rd edition, pp. 461 and 500.



Identify the indicated structures.



SUPERFICIAL PERINEAL POUCH: MUSCLES

1. Suspensory ligament of clitoris
2. Superficial transverse perineal muscle
3. Perineal body
4. Bulbospongiosus muscle
5. Ischiocavernosus muscle
6. Fundiform ligament of penis
7. Suspensory ligament of penis
8. Midline raphe

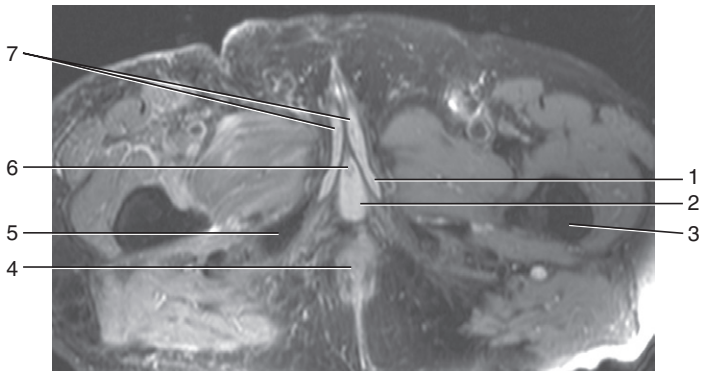
IN THE CLINIC:

- In women the perineum can tear during childbirth as the vaginal orifice expands. The tear can occur posteriorly in the midline, where it can extend through the perineal body and into the rectum.

Figure from Gray's Anatomy for Students, 3rd edition, p. 509.



Identify the indicated structures.



MRI: MALE PELVIC CAVITY AND PERINEUM

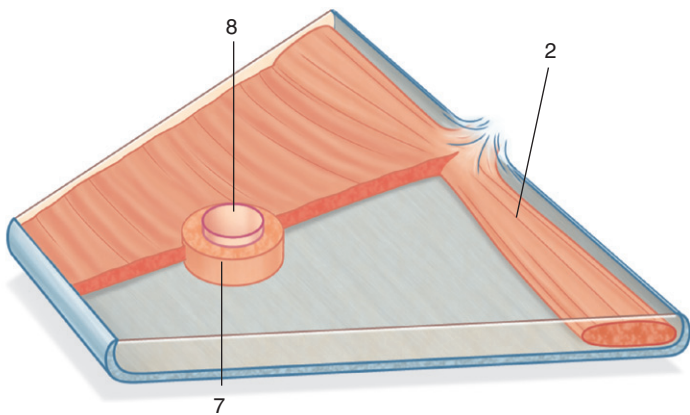
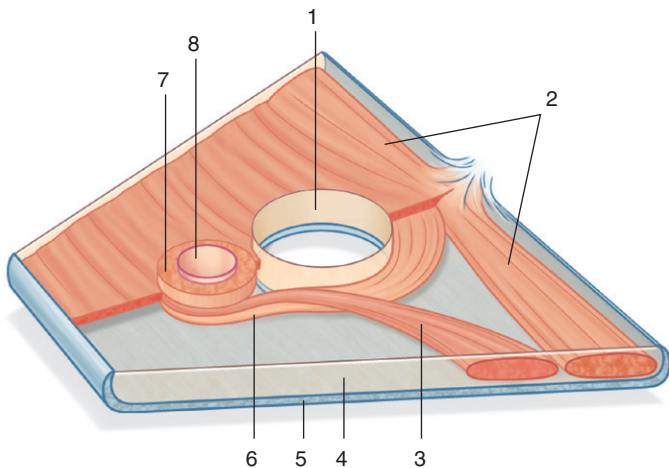


1. Crus of penis
2. Bulb of penis
3. Femur
4. Anal canal
5. Ischiopubic ramus
6. Spongy urethra
7. Corpora cavernosa

Figure from Gray's Basic Anatomy, p. 257.



Identify the indicated structures.



DEEP PERINEAL POUCH: MUSCLES

1. Opening for vagina
2. Deep transverse perineal muscle
3. Compressor urethrae
4. Deep perineal pouch
5. Perineal membrane
6. Sphincter urethrovaginalis
7. External urethral sphincter
8. Opening for urethra

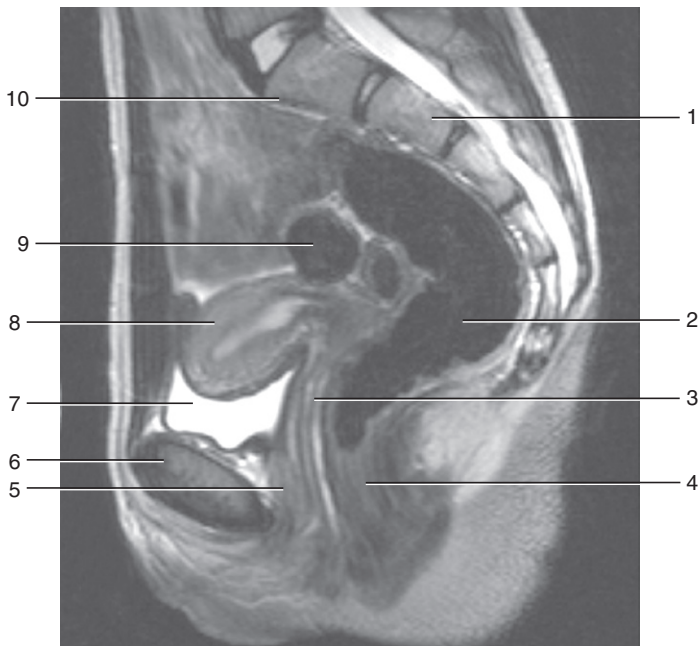
IN THE CLINIC:

- **All muscles in the deep perineal pouch are innervated by the pudendal nerve. This includes the external urethral sphincter, which is skeletal muscle. Loss of function of the pudendal nerve leads not only to the loss of general sensation in the perineum, but also to motor loss in the deep and superficial perineal pouches and to some loss of function of the levator ani.**

Figure from Gray's Anatomy for Students, 3rd edition, p. 459.



Identify the indicated structures.



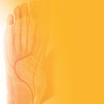

1. Sacrum
2. Rectum
3. Vagina
4. Anal canal
5. Urethra
6. Pubic symphysis
7. Bladder
8. Uterus
9. Small intestine
10. Sacral promontory

Figure from Gray's Basic Anatomy, p. 260.



SECTION 6: LOWER LIMB

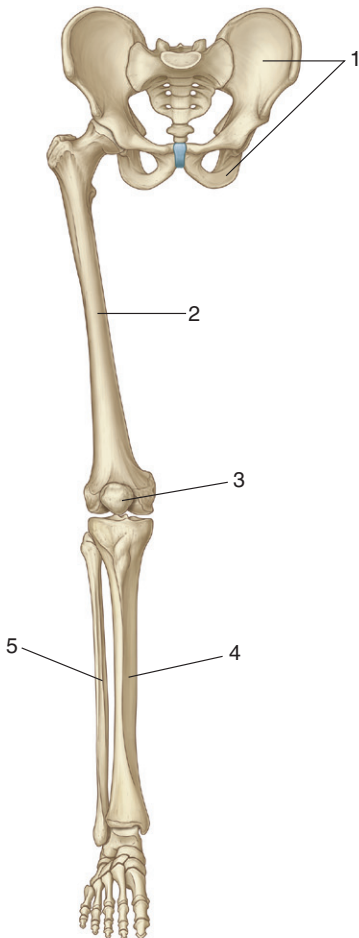


134. Skeleton: Overview
135. Acetabulum
136. Femur
137. Hip Joint Ligaments
138. Ligament of Head of Femur
139. Radiograph: Hip Joint
140. CT: Hip Joint
141. Femoral Triangle
142. Saphenous Vein
143. Anterior Compartment: Muscles
144. Anterior Compartment: Muscle Attachments
145. Femoral Artery
146. Medial Compartment: Muscles
147. Medial Compartment: Muscle Attachments
148. Obturator Nerve
149. Gluteal Region: Muscles
150. Gluteal Region: Muscle Attachments I
151. Gluteal Region: Muscle Attachments II
152. Gluteal Region: Arteries
153. Gluteal Region: Nerves
154. Sacral Plexus
155. Posterior Compartment: Muscles
156. Posterior Compartment: Muscle Attachments
157. Sciatic Nerve
158. Knee: Anterolateral View
159. Knee: Menisci and Ligaments
160. Knee: Collateral Ligaments
161. MRI: Knee Joint
162. Radiographs: Knee Joint
163. Knee: Popliteal Fossa
164. Leg: Bones
165. Leg Posterior Compartment: Muscles
166. Leg Posterior Compartment: Muscle Attachments I
167. Leg Posterior Compartment: Muscle Attachments II
168. Leg Posterior Compartment: Arteries and Nerves
169. Leg Lateral Compartment: Muscles
170. Leg Lateral Compartment: Muscle Attachments
171. Leg Lateral Compartment: Nerves

- 
- 
172. Leg Anterior Compartment: Muscles
 173. Leg Anterior Compartment: Muscle Attachments
 174. Leg Anterior Compartment: Arteries and Nerves
 175. Foot: Bones
 176. Radiograph: Foot
 177. Foot: Ligaments
 178. Radiograph: Ankle
 179. Dorsal Foot: Muscles
 180. Dorsal Foot: Muscle Attachments
 181. Dorsal Foot: Arteries
 182. Dorsal Foot: Nerves
 183. Tarsal Tunnel
 184. Sole of Foot: Muscles, First Layer
 185. Sole of Foot: Muscles, Second Layer
 186. Sole of Foot: Muscles, Third Layer
 187. Sole of Foot: Muscles, Fourth Layer
 188. Sole of Foot: Muscle Attachments, First and Second Layers
 189. Sole of Foot: Muscle Attachments, Third Layer
 190. Sole of Foot: Arteries
 191. Sole of Foot: Nerves



Identify the indicated bones.



SKELETON: OVERVIEW



1. Pelvic bone
2. Femur
3. Patella
4. Tibia
5. Fibula

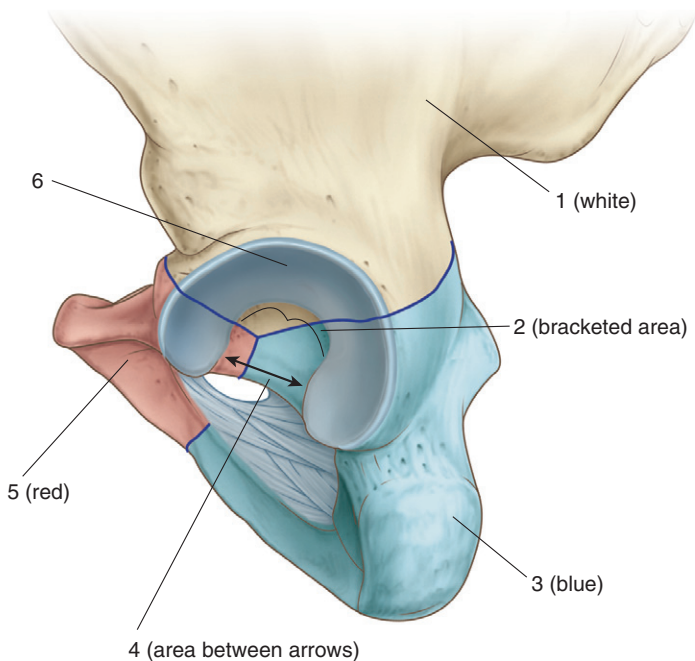
Figure from Gray's Anatomy for Students, 3rd edition, p. 541.



ACETABULUM

135

*Is this structure from the right or left side of the body?
Identify the bones and features.*





ACETABULUM



This structure is on the left side of the body.

1. Ilium
2. Acetabular fossa
3. Ischium
4. Acetabular notch
5. Pubis
6. Lunate surface/articular surface

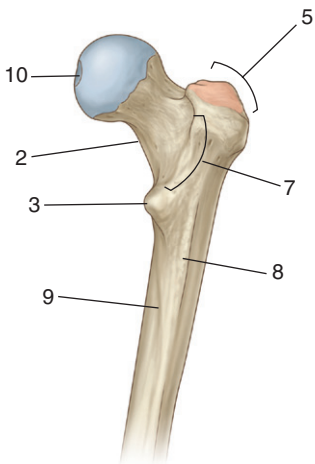
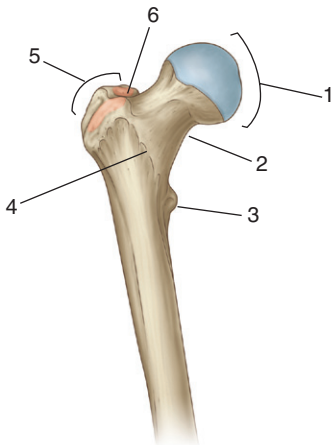
Figure from Gray's Anatomy for Students, 3rd edition, p. 553.



FEMUR

136

Identify the indicated features.



FEMUR



1. Head
2. Neck
3. Lesser trochanter
4. Intertrochanteric line
5. Greater trochanter
6. Trochanteric fossa
7. Intertrochanteric crest
8. Gluteal tuberosity
9. Pectineal line
10. Fovea

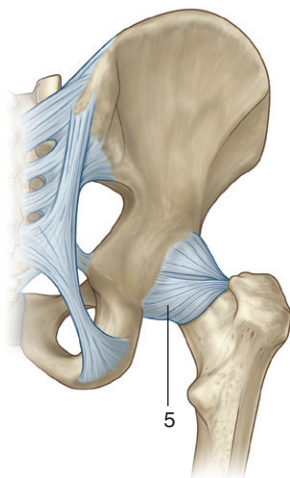
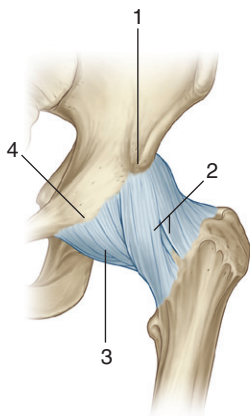
IN THE CLINIC:

- **The femoral neck is a common site of fracture. Fractures of the neck may interrupt the blood supply to the femoral head.**

Figure from Gray's Anatomy for Students, 3rd edition, p. 555.



Identify the indicated ligaments and bony features.



HIP JOINT LIGAMENTS



1. Anterior inferior iliac spine
2. Iliofemoral ligament
3. Pubofemoral ligament
4. Iliopubic eminence
5. Ischiofemoral ligament

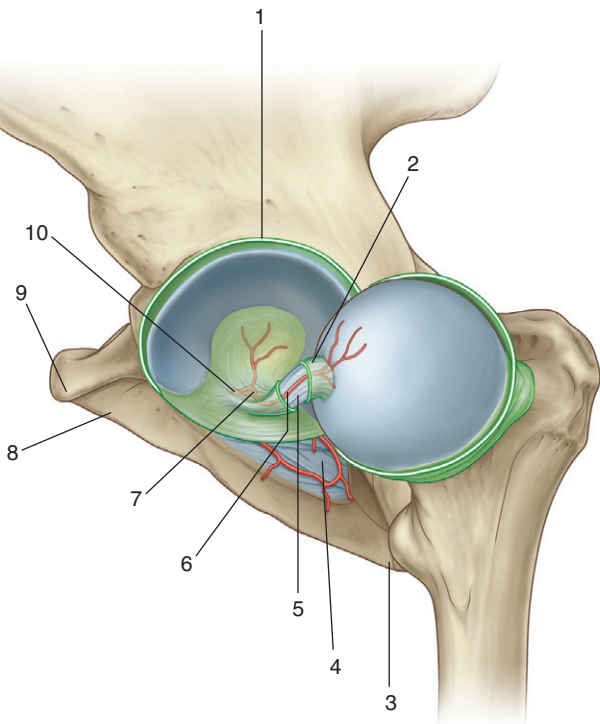
IN THE CLINIC:

- **The hip joint is most stable when it is extended and the ligaments are taut.**

Figure from Gray's Anatomy for Students, 3rd edition, p. 560.



*Is this joint from the left or right side of the body?
Identify the indicated structures and arteries.*





LIGAMENT OF HEAD OF FEMUR



The joint is on the left side of the body.

1. Cut synovial membrane
2. Synovial sleeve around ligament of head of femur
3. Ischial tuberosity
4. Obturator membrane
5. Ligament of head of femur
6. Artery of ligament of head
7. Acetabular branch of obturator artery
8. Pubis
9. Pubic tubercle
10. Obturator artery

IN THE CLINIC:

- The artery in the ligament of the head is important for delivering blood to the femoral head in the growing skeleton. In adults, the predominant blood supply to the head is via arteries along the neck, which, if damaged when the neck is fractured, leads to necrosis of the femoral head.

Figure from Gray's Anatomy for Students, 3rd edition, p. 559.

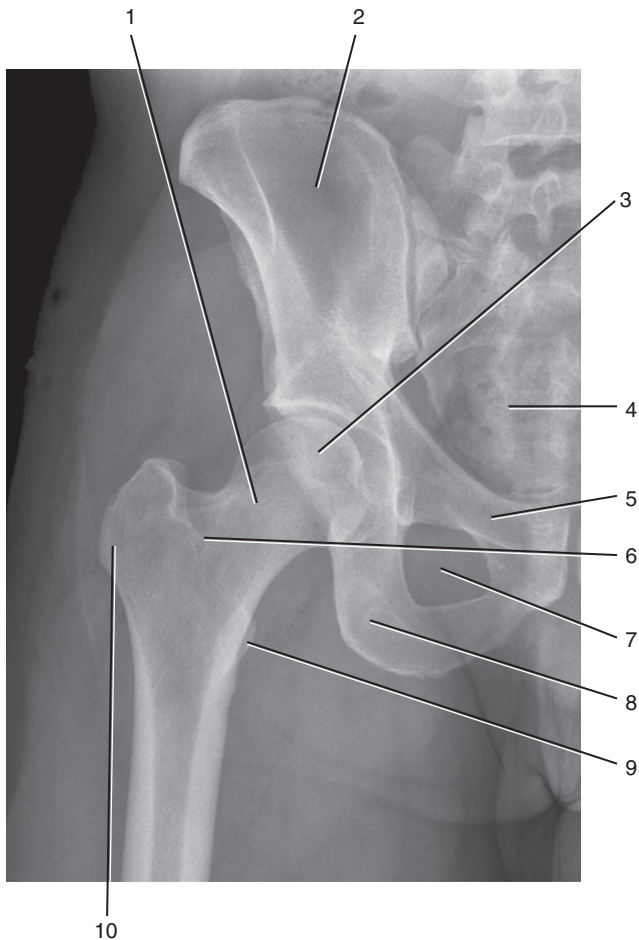


RADIOGRAPH: HIP JOINT



139

Identify the indicated structures.



RADIOGRAPH: HIP JOINT

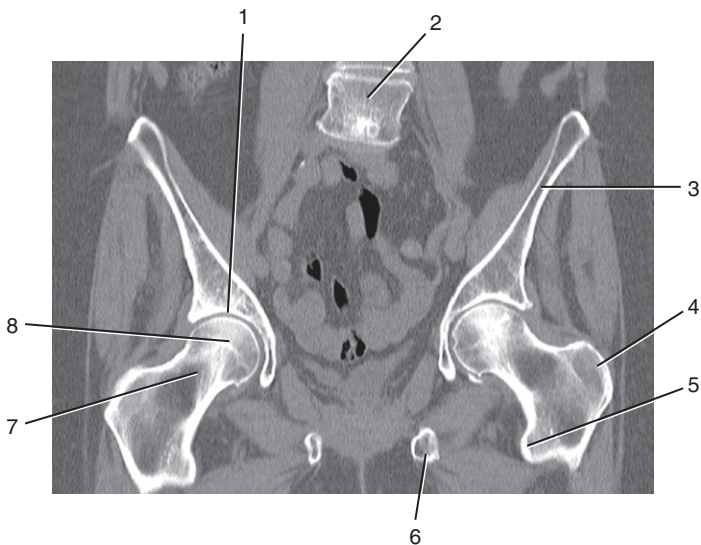


1. Neck of femur
2. Ilium
3. Head of femur
4. Sacrum
5. Pubis
6. Intertrochanteric line
7. Obturator foramen
8. Ischium
9. Lesser trochanter
10. Greater trochanter

Figure from Gray's Basic Anatomy, p. 275.



Identify the indicated structures.



CT: HIP JOINT



1. Acetabulum
2. Body of LIV vertebra
3. Ilium
4. Greater trochanter
5. Lesser trochanter
6. Ischial tuberosity
7. Neck of femur
8. Head of femur

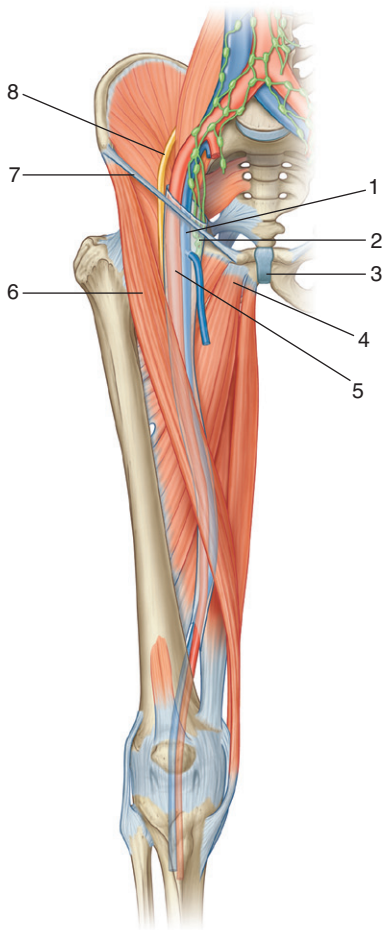
Figure from Gray's Basic Anatomy, p. 275.



FEMORAL TRIANGLE

141

Identify the indicated structures.



FEMORAL TRIANGLE



1. Femoral vein
2. Lymphatic vessels in the femoral canal
3. Pubic symphysis
4. Adductor longus muscle
5. Femoral artery
6. Sartorius muscle
7. Inguinal ligament
8. Femoral nerve

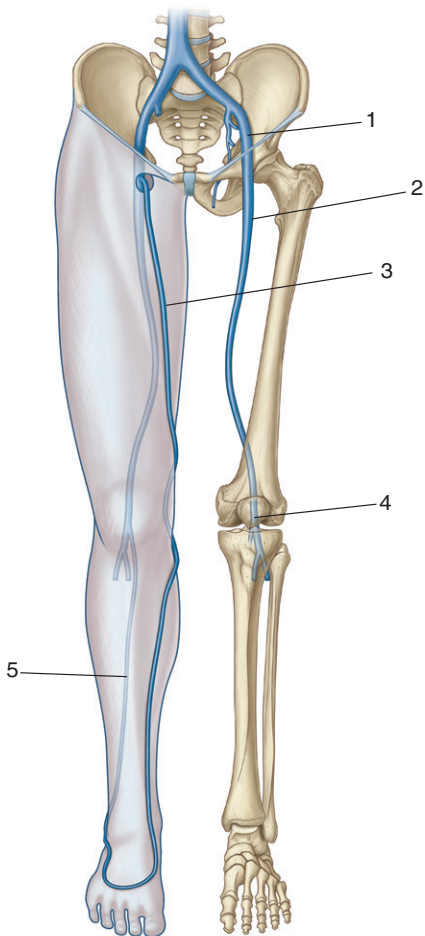
IN THE CLINIC:

- The pulse of the femoral artery can be felt in the femoral triangle immediately below the inguinal ligament midway between the anterior superior iliac spine and the pubic symphysis.
- Femoral hernias occur in the femoral canal, which is medial to the femoral artery and vein, and inferior to the inguinal ligament.

Figure from Gray's Anatomy for Students, 3rd edition, p. 573.




Identify the indicated veins.





SAPHENOUS VEIN



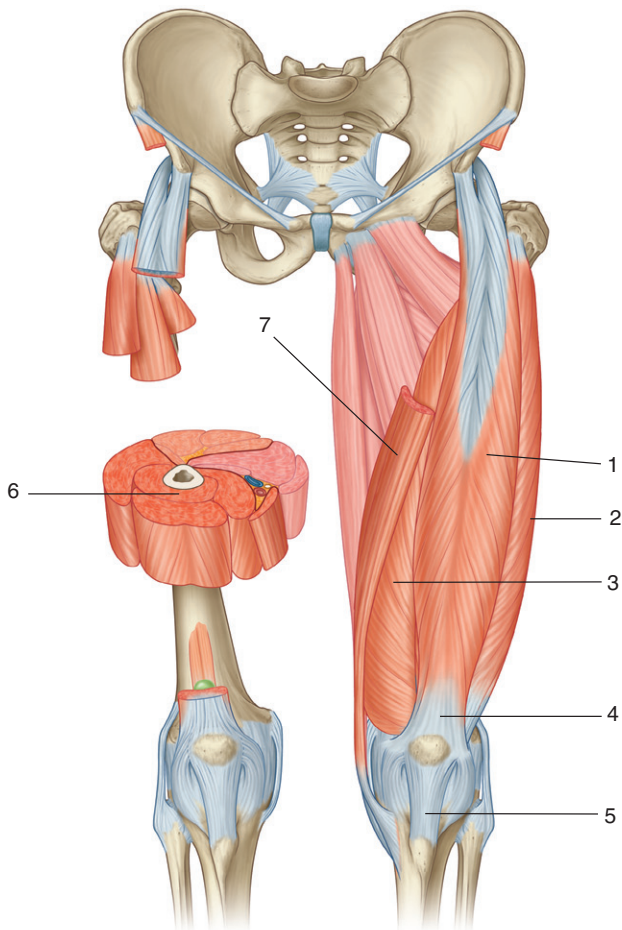
1. External iliac vein
2. Femoral vein
3. Great saphenous vein
4. Popliteal vein
5. Small saphenous vein

IN THE CLINIC:

- **Valve failure in the great and small saphenous veins leads to the pooling of blood in the vessels. As a result, the vessels become enlarged and tortuous, a condition known as “varicose veins.”**
- **Because the great saphenous vein is long and there are regions with few branches, the vessel can be used for transplant into other regions, for example, into the heart during bypass surgery.**

Figure from Gray's Anatomy for Students, 3rd edition, p. 568.

Identify the indicated muscles and tendons.





ANTERIOR COMPARTMENT: MUSCLES

1. Rectus femoris muscle
2. Vastus lateralis muscle
3. Vastus medialis muscle
4. Quadriceps femoris tendon
5. Patellar ligament
6. Vastus intermedius muscle
7. Sartorius muscle

IN THE CLINIC:

- A “tap” on the patellar ligament tests spinal level L3/4.
- Muscles in the anterior compartment of the thigh are innervated by the femoral nerve. A lesion in this nerve leads to a loss mainly of knee extension.

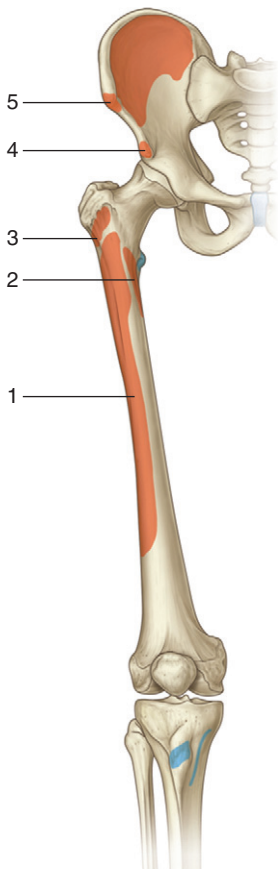
Figure from Gray's Anatomy for Students, 3rd edition, p. 592.



ANTERIOR COMPARTMENT: MUSCLE ATTACHMENTS

144

*Identify the muscles that attach to the areas indicated.
What is the major function and innervation
of each muscle?*



ANTERIOR COMPARTMENT: MUSCLE ATTACHMENTS

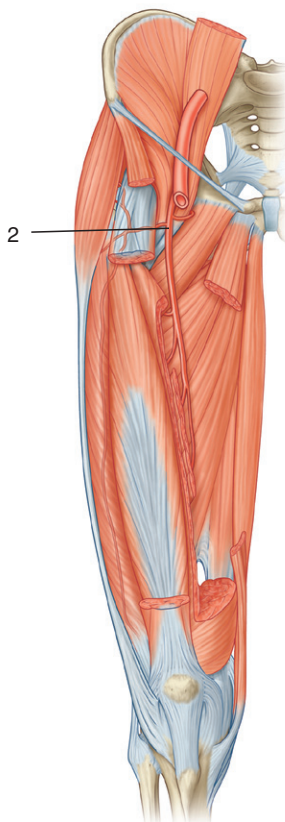
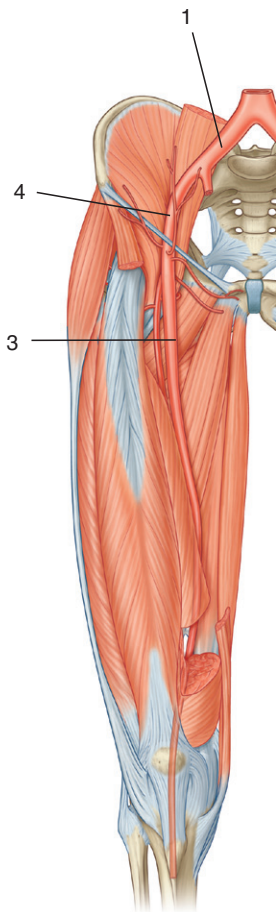
MUSCLES OF THE ANTERIOR COMPARTMENT OF THIGH (SPINAL SEGMENTS IN BOLD ARE THE MAJOR SEGMENTS INNERVATING THE MUSCLE)

Muscle	Origin	Insertion	Innervation	Function
1. Vastus intermedius	Femur—upper two thirds of anterior and lateral surfaces	Quadriceps femoris tendon and lateral margin of patella	Femoral nerve (L2, L3, L4)	Extends the leg at the knee joint
2. Vastus medialis	Femur—medial part of intertrochanteric line, pectineal line, medial lip of the linea aspera, medial supracondylar line	Quadriceps femoris tendon and medial border of patella	Femoral nerve (L2, L3, L4)	Extends the leg at the knee joint
3. Vastus lateralis	Femur—lateral part of intertrochanteric line, margin of greater trochanter, lateral margin of gluteal tuberosity, lateral lip of the linea aspera	Quadriceps femoris tendon	Femoral nerve (L2, L3, L4)	Extends the leg at the knee joint
4. Rectus femoris	Straight head originates from the anterior inferior iliac spine; reflected head originates from the ilium just superior to the acetabulum	Quadriceps femoris tendon	Femoral nerve (L2, L3, L4)	Flexes the thigh at the hip joint and extends the leg at the knee joint
5. Sartorius	Anterior superior iliac spine	Medial surface of tibia just inferomedial to tibial tuberosity	Femoral nerve (L2, L3)	Flexes the thigh at the hip joint and flexes the leg at the knee joint

Figure from Gray's Atlas of Anatomy, 2nd edition, p. 305



Identify the indicated arteries.





FEMORAL ARTERY



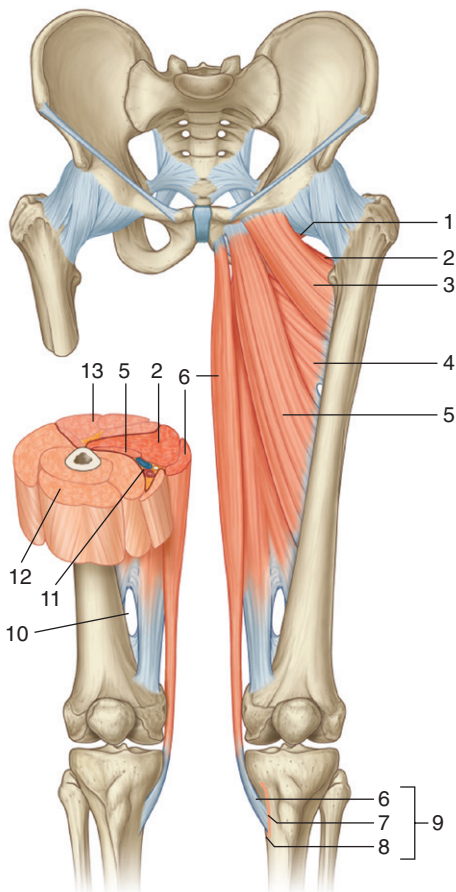
1. Common iliac artery
2. Deep artery of thigh
3. Femoral artery
4. External iliac artery

IN THE CLINIC:

- **Reduced blood flow through the common iliac artery reduces blood flow to the lower limb, pelvis, and perineum. When blood flow is reduced only in the external iliac, anastomoses between branches of the femoral artery in the thigh and branches of the internal iliac may maintain blood flow to the limb.**

Figure from Gray's Anatomy for Students, 3rd edition, pp. 600 and 601.

Identify the indicated muscles, related structures, and muscle compartments.





MEDIAL COMPARTMENT: MUSCLES



1. Obturator externus
2. Adductor magnus
3. Pectineus
4. Adductor brevis
5. Adductor longus
6. Gracilis
7. Sartorius attachment
8. Semitendinosus attachment
9. Pes anserinus
10. Adductor hiatus
11. Adductor canal
12. Anterior compartment of thigh
13. Posterior compartment of thigh

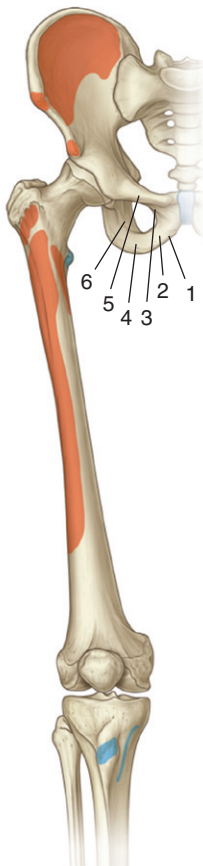Figure from Gray's Anatomy for Students, 3rd edition, p. 595.



MEDIAL COMPARTMENT: MUSCLE ATTACHMENTS

147

*Identify the muscles that attach to the areas indicated.
What is the major function and innervation of
each muscle?*



MEDIAL COMPARTMENT: MUSCLE ATTACHMENTS

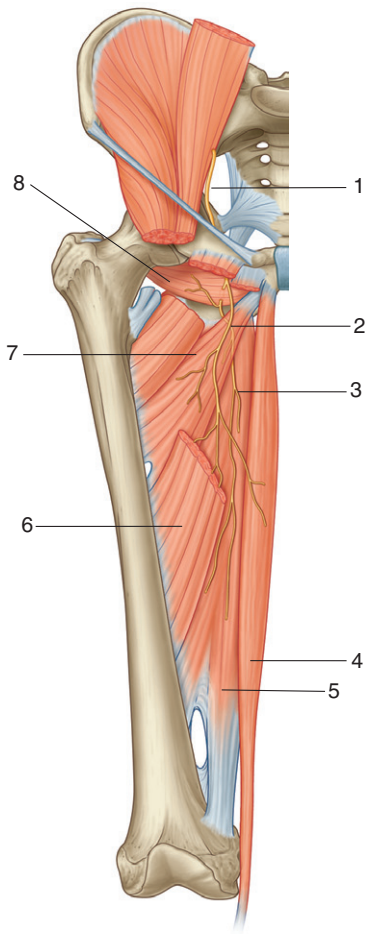


Muscle	Origin	Insertion	Innervation	Function
1. Gracilis	A line on the external surfaces of the body of the pubis, the inferior pubic ramus, and the ramus of the ischium	Medial surface of proximal shaft of the tibia	Obturator nerve (L2,L3)	Adducts thigh at hip joint and flexes leg at knee joint
2. Adductor brevis	External surface of body of pubis and inferior pubic ramus	Posterior surface of proximal femur and upper third of linea aspera	Obturator nerve (L2,L3)	Adducts thigh at hip joint
3. Adductor longus	External surface of body of pubis (triangular depression inferior to pubic crest and lateral to pubic symphysis)	Linea aspera on middle third of shaft of femur	Obturator nerve (anterior division) (L2,L3,L4)	Adducts and medially rotates thigh at hip joint
4. Adductor magnus	Adductor part—ischio pubic ramus Hamstring part—ischial tuberosity	Posterior surface of proximal femur, linea aspera, medial supracondylar line Adductor tubercle and supracondylar line	Obturator nerve (L2,L3,L4) Sciatic nerve (tibial division) (L2,L3,L4)	Adducts and medially rotates thigh at hip joint
5. Pectineus	Pectineal line (pecten pubis) and adjacent bone of pelvis	Oblique line extending from base of lesser trochanter to linea aspera on posterior surface of proximal femur	Femoral nerve (L2,L3)	Adducts and flexes thigh at hip joint
6. Obturator externus	External surface of obturator foramen and adjacent bone	Trochanteric fossa	Obturator nerve (posterior division) (L3,L4)	Laterally rotates thigh at hip joint

Figure from Gray's Atlas of Anatomy, 2nd edition, p. 305.



Identify the indicated nerves and muscles.





OBTURATOR NERVE



1. Obturator nerve
2. Anterior branch of obturator nerve
3. Posterior branch of obturator nerve
4. Gracilis muscle
5. Adductor magnus muscle
6. Adductor longus muscle
7. Adductor brevis muscle
8. Obturator externus muscle

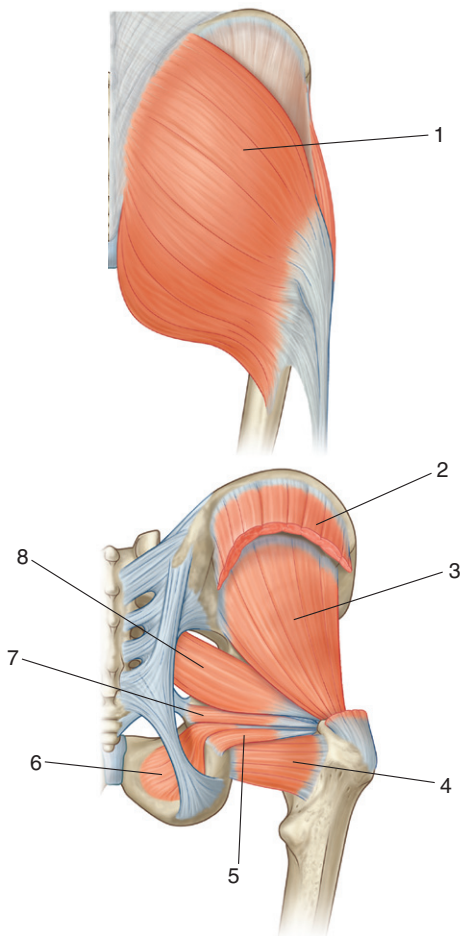
IN THE CLINIC:

- **Muscles in the medial compartment of the thigh are innervated mainly by the obturator nerve. Reduced function of this nerve leads to a reduced ability to adduct the thigh at the hip joint.**

Figure from Gray's Anatomy for Students, 3rd edition, p. 605.



Identify the indicated muscles.





GLUTEAL REGION: MUSCLES



1. Gluteus maximus
2. Gluteus medius
3. Gluteus minimus
4. Quadratus femoris
5. Gemellus inferior
6. Obturator internus
7. Gemellus superior
8. Piriformis

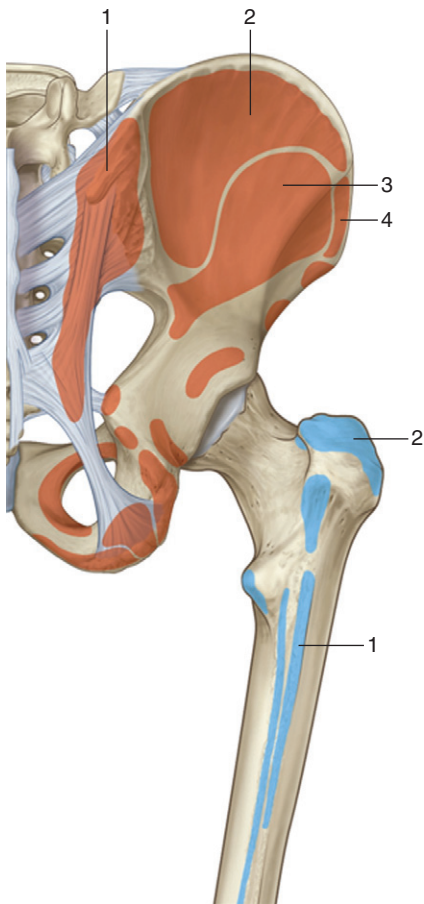
IN THE CLINIC:

- **Gluteus medius and minimus are abductors of the hip joint. They prevent excessive pelvic tilt on the stance leg when the opposite limb swings forward during walking.**
- **Gluteus maximus is a powerful extensor of the hip joint and is most active when standing from a sitting position or when walking up stairs.**
- **The other small muscles in the gluteal region are mainly external rotators of the hip joint.**

Figure from Gray's Anatomy for Students, 3rd edition, pp. 576 and 578.



Identify the muscle and its attachments, innervation, and actions.

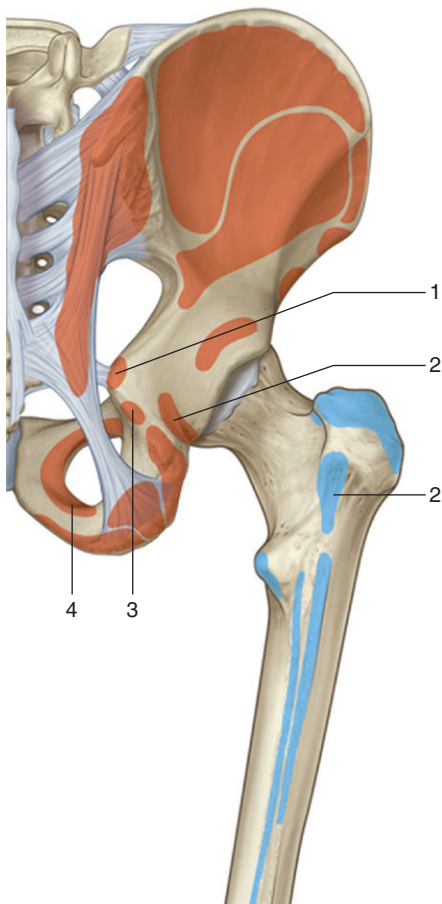


Muscle	Origin	Insertion	Innervation	Function
1. Gluteus maximus	Fascia covering gluteus medius, external surface of ilium behind posterior gluteal line, fascia of erector spinae, dorsal surface of lower sacrum, lateral margin of coccyx, external surface of sacrotuberous ligament	Posterior aspect of iliotibial tract of fascia lata and gluteal tuberosity of proximal femur	Inferior gluteal nerve (L5,S1,S2)	Powerful extensor of flexed femur at hip joint; lateral stabilizer of hip joint and knee joint; laterally rotates and abducts thigh
2. Gluteus medius	External surface of ilium between anterior and posterior gluteal lines	Elongate facet on the lateral surface of the greater trochanter	Superior gluteal nerve (L4,L5,S1)	Abducts femur at hip joint; holds pelvis secure over stance leg and prevents pelvic drop on the opposite swing side during walking; medially rotates thigh
3. Gluteus minimus	External surface of ilium between inferior and anterior gluteal lines	Linear facet on anterolateral aspect of greater trochanter	Superior gluteal nerve (L4,L5,S1)	Abducts femur at hip joint; holds pelvis secure over stance leg and prevents pelvic drop on the opposite swing side during walking; medially rotates thigh
4. Tensor fasciae latae	Lateral aspect of crest of ilium between anterior superior iliac spine and tubercle of the crest	Iliotibial tract of fascia lata	Superior gluteal nerve (L4,L5,S1)	Stabilizes the knee in extension

Figure from Gray's Atlas of Anatomy, 2nd edition, p. 300.



Identify the muscle and its attachments, innervation, and actions.

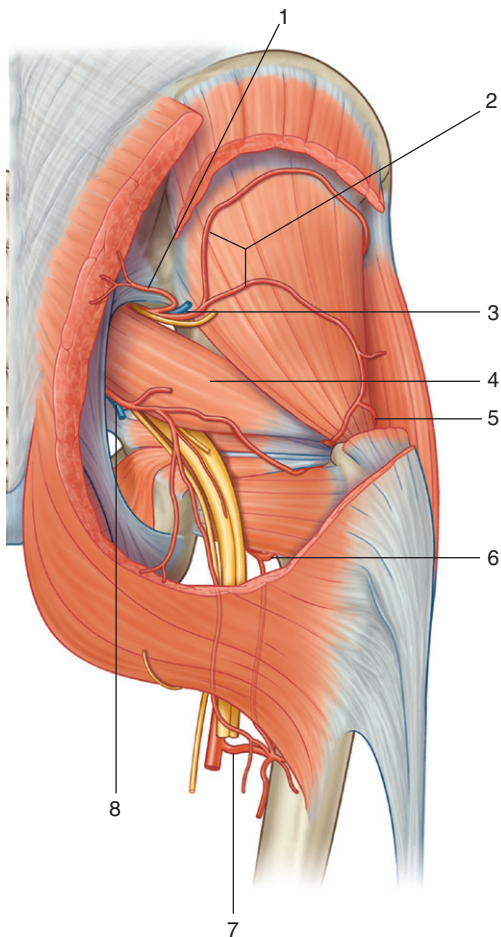


MUSCLES OF THE GLUTEAL REGION (SPINAL SEGMENTS IN BOLD ARE THE MAJOR SEGMENTS INNERVATING THE MUSCLE)

Muscle	Origin	Insertion	Innervation	Function
1. Gemellus superior	External surface of ischial spine	Along length of superior surface of the obturator internus tendon and into the medial side of greater trochanter of femur with obturator internus tendon	Nerve to obturator internus (L5, S1)	Laterally rotates the extended femur at hip joint; abduction of flexed femur at hip joint
2. Quadratus femoris	Lateral aspect of the ischium just anterior to the ischial tuberosity	Quadratus tubercle on the intertrochanteric crest of the proximal femur	Nerve to quadratus femoris (L5, S1)	Laterally rotates femur at hip joint
3. Gemellus inferior	Upper aspect of ischial tuberosity	Along length of inferior surface of the obturator internus tendon and into the medial side of greater trochanter of femur with obturator internus tendon	Nerve to quadratus femoris (L5, S1)	Laterally rotates the extended femur at hip joint; abducts flexed femur at hip joint
4. Obturator internus	Anterolateral wall of true pelvis; deep surface of obturator foramen and surrounding bone	Medial side of greater trochanter of femur	Nerve to obturator internus (L5, S1)	Laterally rotates the extended femur at hip joint; abducts flexed femur at hip joint

Figure from Gray's Atlas of Anatomy, 2nd edition, p. 300.

Identify the indicated arteries.





GLUTEAL REGION: ARTERIES



1. Superficial branch
2. Deep branch
3. Superior gluteal artery and vein
4. Piriformis muscle
5. Lateral femoral circumflex artery
6. Medial femoral circumflex artery
7. First perforating artery from deep artery of thigh
8. Inferior gluteal artery and vein

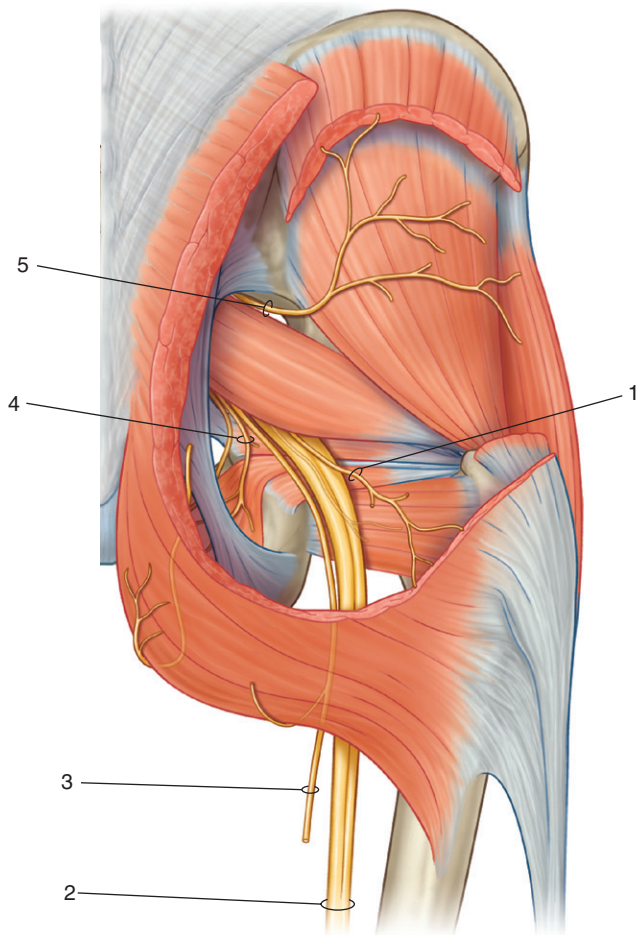
IN THE CLINIC:

- **The gluteal arteries from the internal iliac artery form an anastomotic network of vessels around the hip with branches of the femoral artery from the external iliac artery. This network may maintain blood flow to the limb when one of the supply vessels is blocked.**

Figure from Gray's Anatomy for Students, 3rd edition, p. 582.



Identify the indicated nerves.



GLUTEAL REGION: NERVES



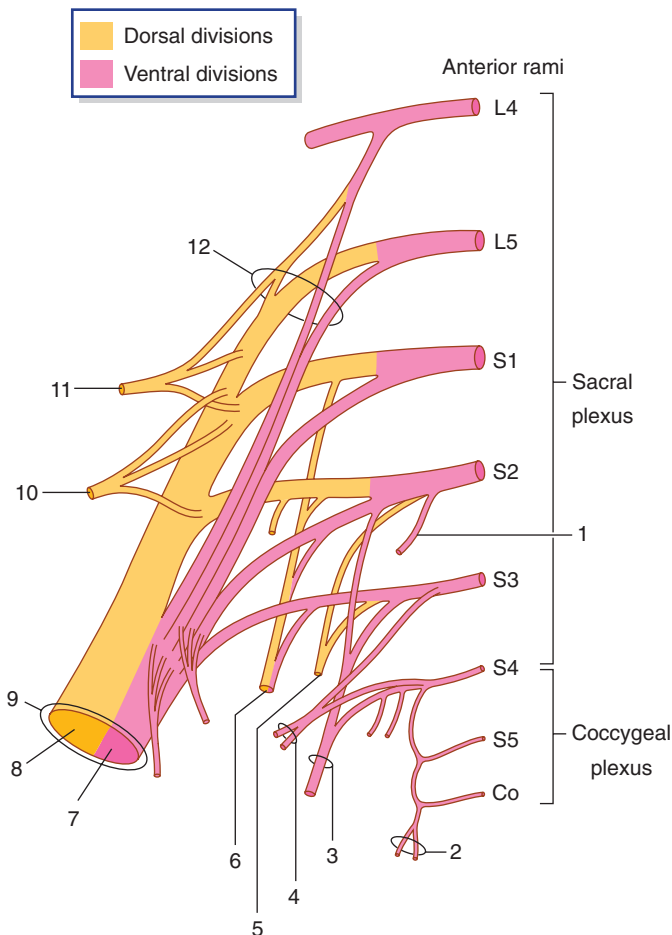
1. Inferior gluteal nerve
2. Sciatic nerve
3. Posterior cutaneous nerve of thigh
4. Nerve to obturator internus
5. Superior gluteal nerve

IN THE CLINIC:

- **A lesion of the superior gluteal nerve leads to reduced ability to abduct the thigh and to excessive pelvic tilt over the swing leg during walking.**
- **A lesion of the inferior gluteal nerve leads to a reduced ability to extend the hip.**
- **A lesion of the sciatic nerve leads to loss of muscle function in the foot, leg, and posterior thigh, as well as to sensory loss from the foot and lateral leg.**

Figure from Gray's Anatomy for Students, 3rd edition, p. 579.

Identify the indicated nerves.



SACRAL PLEXUS



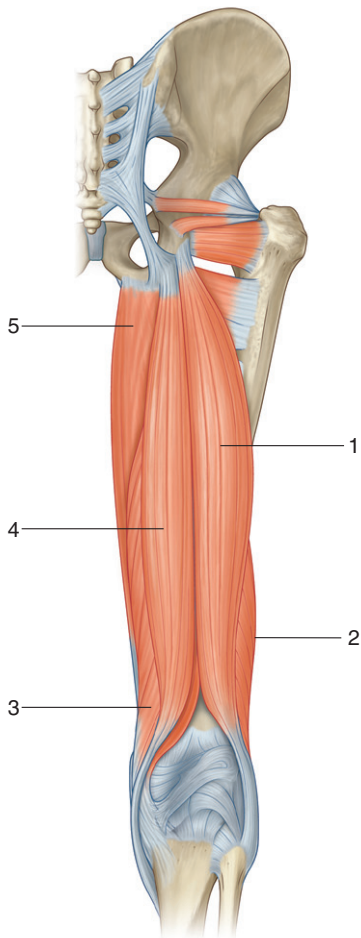
1. Pelvic splanchnic nerve
2. Anococcygeal nerves
3. Pudendal nerve
4. Pelvic splanchnic nerves
5. Perforating cutaneous nerve
6. Posterior femoral cutaneous nerve
7. Tibial part
8. Common fibular part
9. Sciatic nerve
10. Inferior gluteal nerve
11. Superior gluteal nerve
12. Lumbosacral trunk

IN THE CLINIC:

- **Nerves in the lower limb originate from the lumbosacral plexus. As a result, a pathologic process that affects the anterior rami of lumbar and sacral spinal nerves can appear as motor and sensory “signs” in the lower limb. Problems with spinal nerves L4 and L5 can appear as problems with the sciatic nerve or gluteal nerves.**

Figure from Gray’s Anatomy for Students, 3rd edition, p. 487.

Identify the indicated muscles.



POSTERIOR COMPARTMENT: MUSCLES

1. Long head of biceps femoris
2. Short head of biceps femoris
3. Semimembranosus
4. Semitendinosus
5. Hamstring part of adductor magnus

IN THE CLINIC:

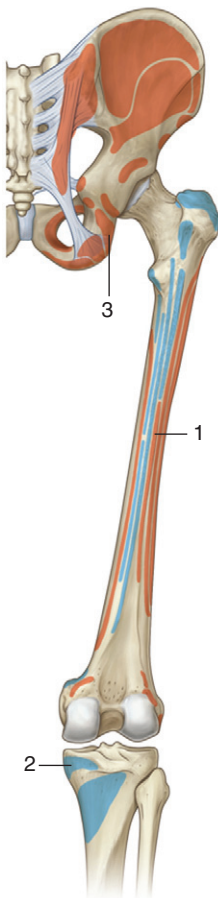
- **As a group, the hamstring muscles extend the hip and flex the knee. The long head of biceps femoris and the semitendinosus and semimembranosus muscles cross both the hip and knee joints and are innervated by the tibial part of the sciatic nerve. The hamstring part of adductor longus also is innervated by the tibial nerve but functions only on the hip joint. The short head of biceps femoris crosses only the knee joint and is innervated by the common fibular part of the sciatic nerve.**

Figure from Gray's Anatomy for Students, 3rd edition, p. 599.

POSTERIOR COMPARTMENT: MUSCLE ATTACHMENTS

156

Identify the muscle and its attachments, innervation, and actions.



POSTERIOR COMPARTMENT: MUSCLE ATTACHMENTS

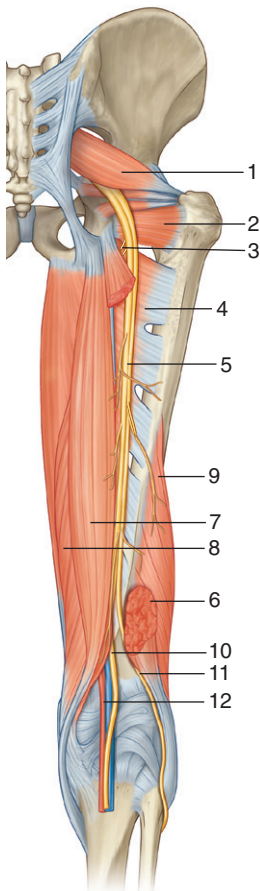
MUSCLES OF THE POSTERIOR COMPARTMENT OF THIGH (SPINAL SEGMENTS IN BOLD ARE THE MAJOR SEGMENTS INNERVATING THE MUSCLE)

Muscle	Origin	Insertion	Innervation	Function
1. Biceps femoris	Long head— inferomedial part of the upper area of the ischial tuberosity; short head—lateral lip of linea aspera	Head of fibula	Sciatic nerve (L5, S1 , S2)	Flexes leg at knee joint; extends and laterally rotates thigh at hip joint and laterally rotates leg at knee joint
2. Semimembranosus	Superolateral impression on the ischial tuberosity	Groove and adjacent bone on medial and posterior surface of medial tibial condyle	Sciatic nerve (L5, S1 , S2)	Flexes leg at knee joint and extends thigh at hip joint; medially rotates thigh at the hip joint and leg at the knee joint
3. Semitendinosus	Semitendinosus Inferomedial part of the upper area of the ischial tuberosity	Medial surface of proximal tibia	Sciatic nerve (L5, S1 , S2)	Flexes leg at knee joint and extends thigh at hip joint; medially rotates the thigh at the hip joint and leg at the knee joint

Figure from Gray's Atlas of Anatomy, p. 305.



Identify the indicated nerves, vessels, and muscles.





1. Piriformis muscle
2. Quadratus femoris muscle
3. Branch to part of adductor magnus originating from ischial tuberosity
4. Adductor magnus muscle
5. Sciatic nerve
6. Long head of biceps femoris muscle
7. Semitendinosus muscle
8. Semimembranosus muscle
9. Short head of biceps femoris muscle
10. Tibial nerve
11. Common fibular nerve
12. Popliteal artery and vein

IN THE CLINIC:

- The sciatic nerve can be damaged when giving intramuscular injections in the gluteal region if the injections are not done in the correct location.
- Irritation or compression of the anterior rami of spinal nerves, particularly from L4 and L5, that contribute to formation of the sciatic nerve can result in sensory and motor dysfunction of the sciatic nerve. Diffuse pain from the area of distribution of the sciatic nerve is termed *sciatica*.
- The common fibular nerve courses laterally around the neck of the fibula, where it can be damaged by impact or compression injuries. Damage to the common fibular nerve leads to footdrop (the inability to dorsiflex the foot) and to sensory loss over the lateral leg and dorsal surface of the foot.

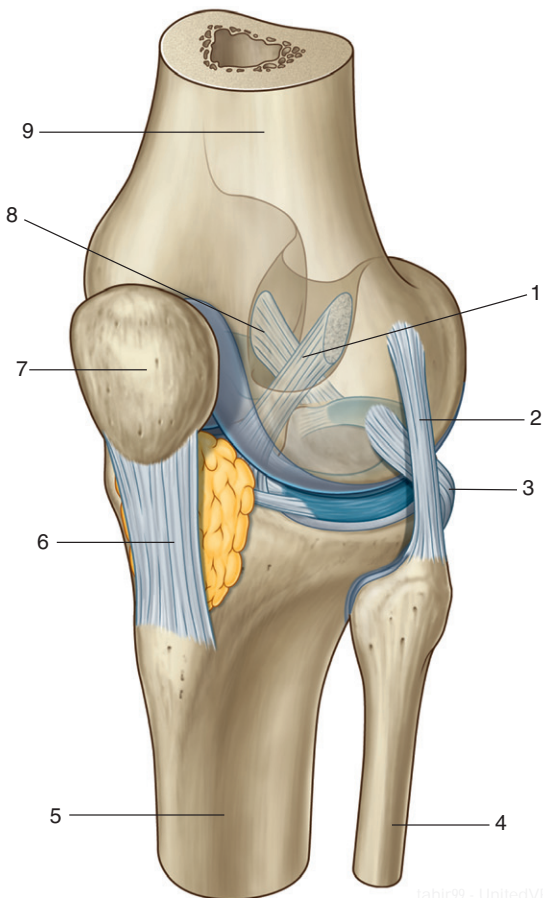
Figure from Gray's Anatomy for Students, 3rd edition, p. 605.



KNEE: ANTEROLATERAL VIEW

158

*Is this a left or a right knee joint?
Identify the indicated structures.*



KNEE: ANTEROLATERAL VIEW

This is a left knee joint.

1. Anterior cruciate ligament
2. Fibular collateral ligament
3. Tendon of popliteus muscle
4. Fibula
5. Tibia
6. Patellar ligament
7. Patella
8. Posterior cruciate ligament
9. Femur

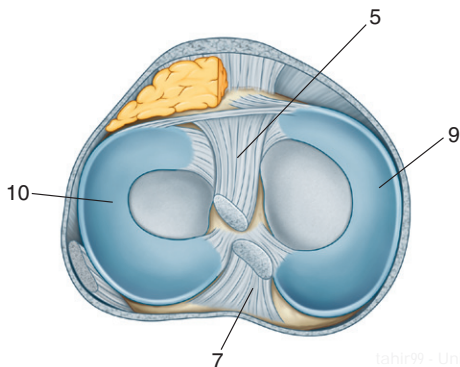
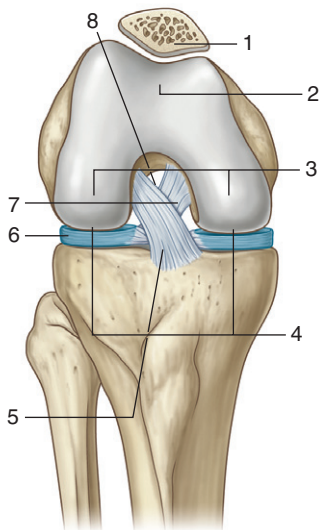
IN THE CLINIC:

- When the posterior cruciate ligament is torn, the head of the femur moves forward on the tibia (or a clinician can push the tibia posteriorly on the fixed femur of a patient—a positive posterior “drawer” sign).
- When the anterior cruciate ligament is torn, the head of the femur moves backward on the tibia (or a clinician can pull the tibia forward on the fixed femur of a patient—a positive anterior “drawer” sign).

Figure from Gray's Anatomy for Students, 3rd edition, p. 606.



Identify the indicated structures.



KNEE: MENISCI AND LIGAMENTS

1. Patella
2. Surface for articulation with patella
3. Flat surfaces for articulation with tibia in extension
4. Round surfaces for articulation with tibia in flexion
5. Anterior cruciate ligament
6. Meniscus
7. Posterior cruciate ligament
8. Intercondylar region
9. Medial meniscus
10. Lateral meniscus

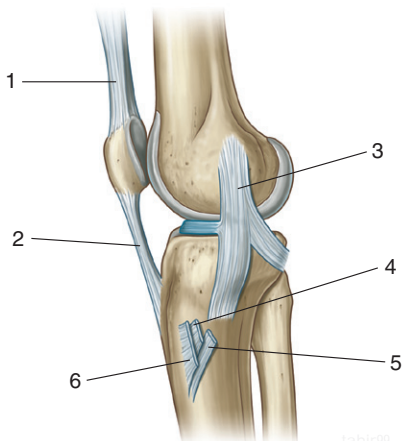
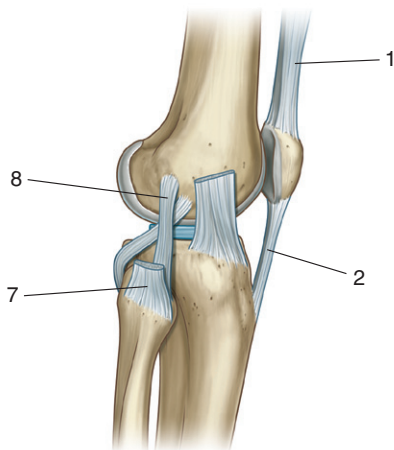
IN THE CLINIC:

- The patella dislocates more often laterally than medially because the angle of pull of the quadriceps muscle tends to pull more laterally than medially.
- In lateral blows to the knee on the standing leg, the tibial collateral ligament and the medial meniscus can be torn. It is also possible in this type of injury to tear the lateral meniscus due to compression forces on the lateral side of the knee joint.

Figure from Gray's Anatomy for Students, 3rd edition, p. 607.



Identify the indicated ligaments and tendons.



KNEE: COLLATERAL LIGAMENTS

1. Tendon of quadriceps muscles
2. Patellar ligament
3. Tibial collateral ligament
4. Tendon of gracilis
5. Tendon of semitendinosus
6. Tendon of sartorius
7. Tendon of biceps femoris muscle
8. Fibular collateral ligament

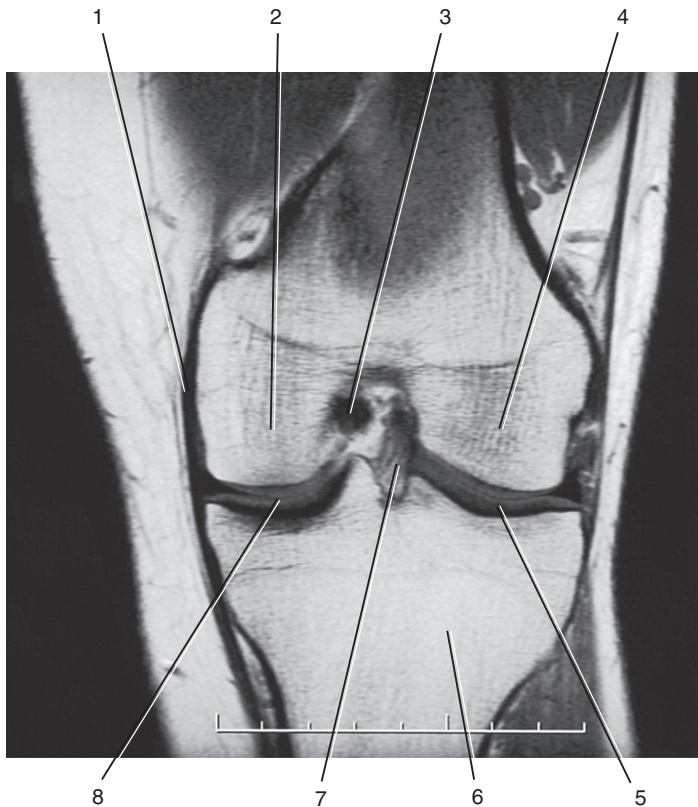
IN THE CLINIC:

- Lateral and medial blows to the knee can tear the tibial and fibular collateral ligaments, respectively, of the knee. When the fibular collateral ligament is torn in these injuries, the medial meniscus also can be injured because of compression forces that occur on the medial side of the joint. For the same reason, when the tibial collateral ligament is torn, the lateral meniscus can be injured.
- In posterior and posterolateral blows to the knee, it is possible to tear the tibial collateral ligament, the medial meniscus, and the anterior cruciate ligament. This injury is sometimes referred to as the “unlucky triad.”

Figure from Gray's Anatomy for Students, 3rd edition, p. 611.



Identify the indicated structures.



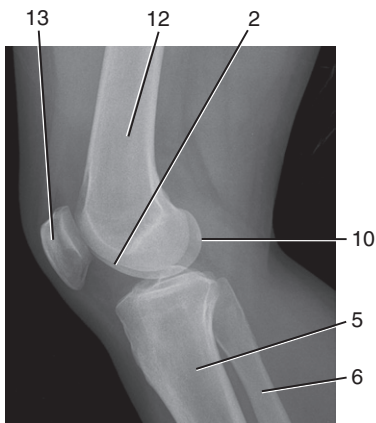
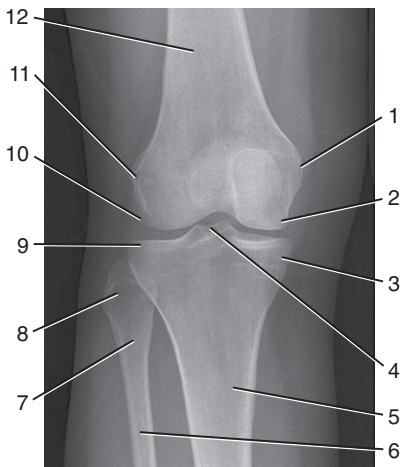
MRI: KNEE JOINT



1. Tibial collateral ligament
2. Medial femoral condyle
3. Posterior cruciate ligament
4. Lateral femoral condyle
5. Lateral meniscus
6. Tibia
7. Anterior cruciate ligament
8. Medial meniscus

Figure from Gray's Basic Anatomy, p. 304.

Identify the indicated structures.



RADIOGRAPHS: KNEE JOINT

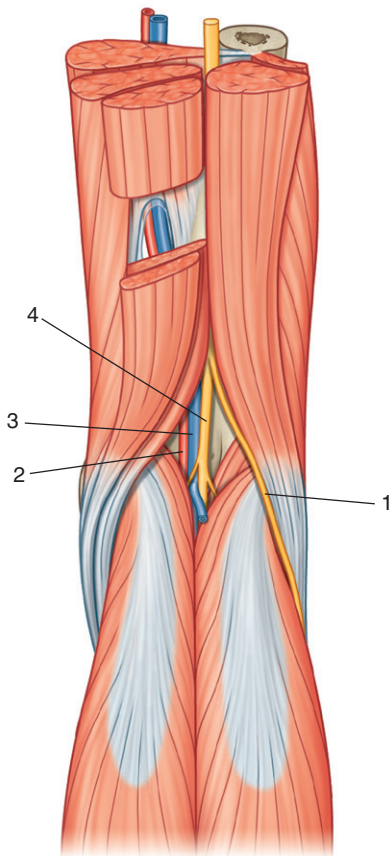


1. Medial epicondyle
2. Medial femoral condyle
3. Medial tibial condyle
4. Intercondylar eminence
5. Tibia
6. Fibula
7. Neck of fibula
8. Head of fibula
9. Lateral tibial condyle
10. Lateral femoral condyle
11. Lateral epicondyle
12. Femur
13. Patella

Figure from Gray's Basic Anatomy, p. 304.



*Is this region from the left or right side of the body?
Identify the indicated structures.*





KNEE: POPLITEAL FOSSA



This region is on the right side of the body.

1. Common fibular nerve
2. Popliteal artery
3. Popliteal vein
4. Tibial nerve

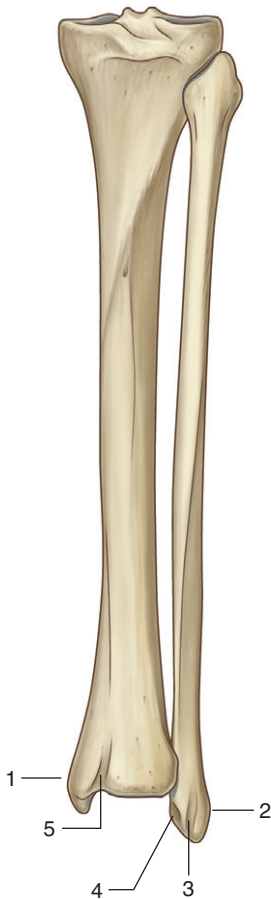
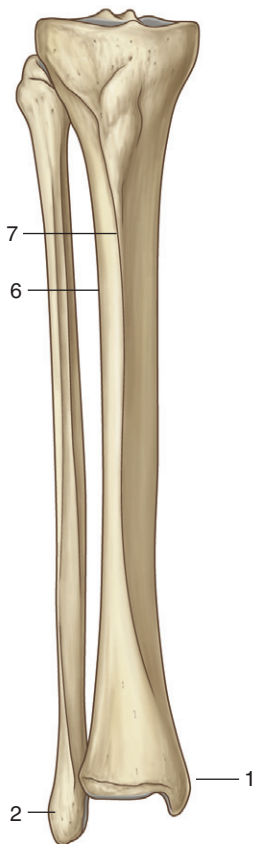
IN THE CLINIC:

- **A popliteal pulse is difficult to feel because the artery is deep within the popliteal fossa; however, the pulse can be detected by palpating just medial to the midline.**

Figure from Gray's Anatomy for Students, 3rd edition, p. 616.



*Are these bones from the right or left side of the body?
Identify the indicated bones and features.*



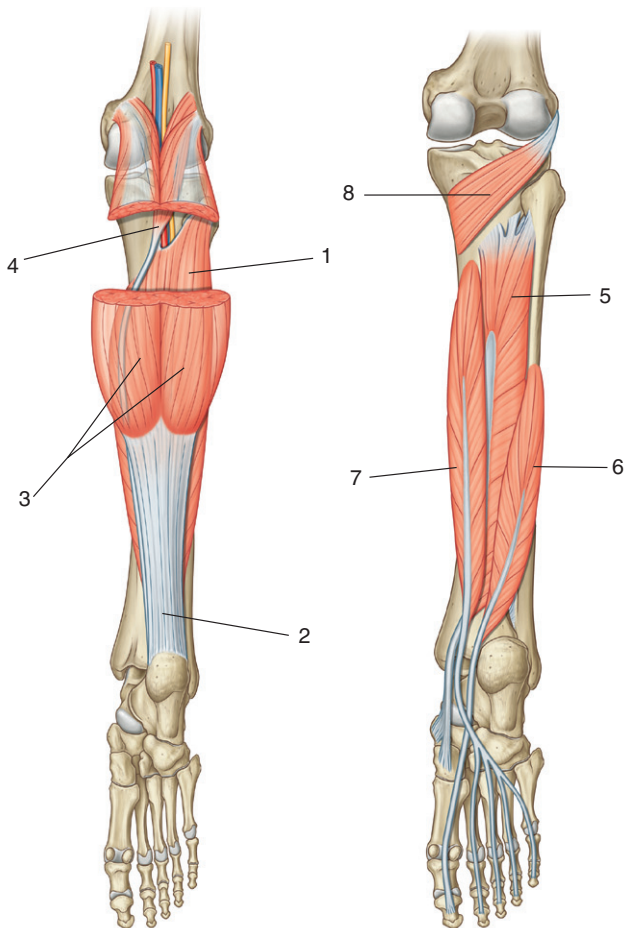


These bones are on the right side of the body.

1. Medial malleolus
2. Lateral malleolus
3. Groove for fibularis longus and brevis muscles
4. Malleolar fossa
5. Groove for tendon of tibialis posterior muscle
6. Interosseous border
7. Anterior border

Figure from Gray's Anatomy for Students, 3rd edition, p. 619.

Identify the indicated muscles and tendons.





LEG POSTERIOR COMPARTMENT: MUSCLES

1. Soleus
2. Calcaneal (Achilles) tendon
3. Gastrocnemius
4. Plantaris
5. Tibialis posterior
6. Flexor hallucis longus
7. Flexor digitorum longus
8. Popliteus

IN THE CLINIC:

- **All muscles in the posterior compartment of the leg are innervated by the tibial branch of the sciatic nerve.**

Figure from Gray's Anatomy for Students, 3rd edition, pp. 622-623.

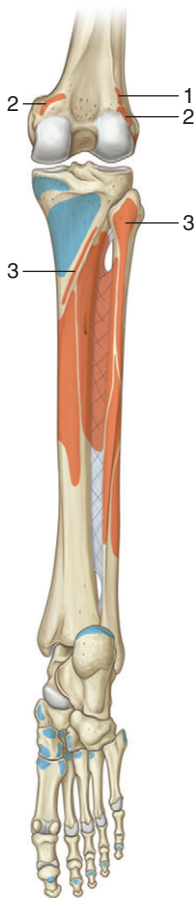


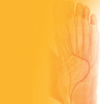LEG POSTERIOR COMPARTMENT: MUSCLE ATTACHMENTS I



166

Identify the muscle and its attachments, innervation, and actions.





LEG POSTERIOR COMPARTMENT: MUSCLE ATTACHMENTS I



SUPERFICIAL GROUP OF MUSCLES IN THE POSTERIOR COMPARTMENT OF LEG (SPINAL SEGMENTS IN BOLD ARE THE MAJOR SEGMENTS INNERVATING THE MUSCLE)

Muscle	Origin	Insertion	Innervation	Function
1. Plantaris	Inferior part of lateral supracondylar line of femur and oblique popliteal ligament of knee	Via calcaneal tendon, to posterior surface of calcaneus	Tibial nerve (S1,S2)	Plantarflexes foot and flexes knee
2. Gastrocnemius	Medial head—posterior surface of distal femur just superior to medial condyle; lateral head—upper posterolateral surface of lateral femoral condyle	Via calcaneal tendon, to posterior surface of calcaneus	Tibial nerve (S1,S2)	Plantarflexes foot and flexes knee
3. Soleus	Soleal line and medial border of tibia; posterior aspect of fibular head and adjacent surfaces of neck and proximal shaft; tendinous arch between tibial and fibular attachments	Via calcaneal tendon, to posterior surface of calcaneus	Tibial nerve (S1,S2)	Plantarflexes foot

Figure from Gray's Atlas of Anatomy, 2nd edition, p. 339.

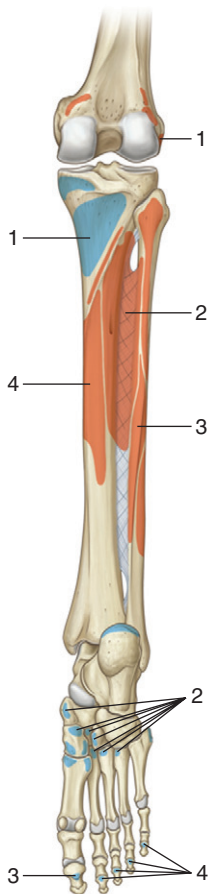


LEG POSTERIOR COMPARTMENT: MUSCLE ATTACHMENTS II



167

Identify the muscle and its attachments, innervation, and actions.



LEG POSTERIOR COMPARTMENT: MUSCLE ATTACHMENTS II

DEEP GROUP OF MUSCLES IN THE POSTERIOR COMPARTMENT OF LEG (SPINAL SEGMENTS IN BOLD ARE THE MAJOR SEGMENTS INNERVATING THE MUSCLE)

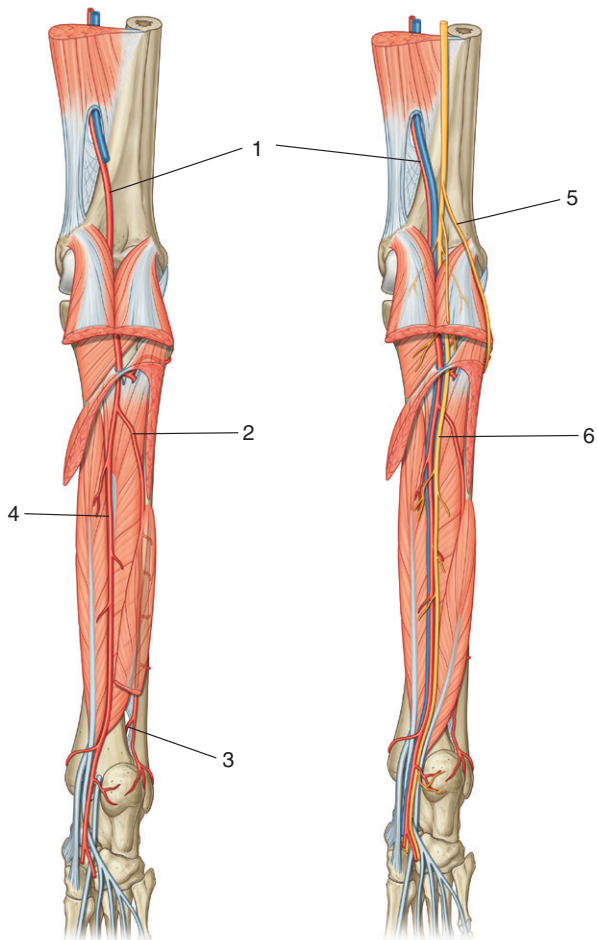
Muscle	Origin	Insertion	Innervation	Function
1. Popliteus	Lateral femoral condyle	Posterior surface of proximal tibia	Tibial nerve (L4 to S1)	Unlocks knee joint (laterally rotates femur on fixed tibia)
2. Tibialis posterior	Posterior surfaces of interosseous membrane and adjacent regions of tibia and fibula	Mainly to tuberosity of navicular and adjacent region of medial cuneiform	Tibial nerve (L4,L5)	Inversion and plantar flexion of foot; support of medial arch of foot during walking
3. Flexor hallucis longus	Posterior surface of fibula and adjacent interosseous membrane	Plantar surface of distal phalanx of great toe	Tibial nerve (S2,S3)	Flexes great toe
4. Flexor digitorum longus	Medial side of posterior surface of the tibia	Plantar surfaces of bases of distal phalanges of the lateral four toes	Tibial nerve (S2,S3)	Flexes lateral four toes

Figure from Gray's Atlas of Anatomy, 2nd edition, p. 339.

LEG POSTERIOR COMPARTMENT: ARTERIES AND NERVES

168

Identify the indicated nerves and arteries.



LEG POSTERIOR COMPARTMENT: ARTERIES AND NERVES



1. Popliteal artery
2. Fibular artery
3. Perforating terminal branch of fibular artery
4. Posterior tibial artery
5. Common fibular nerve
6. Tibial nerve

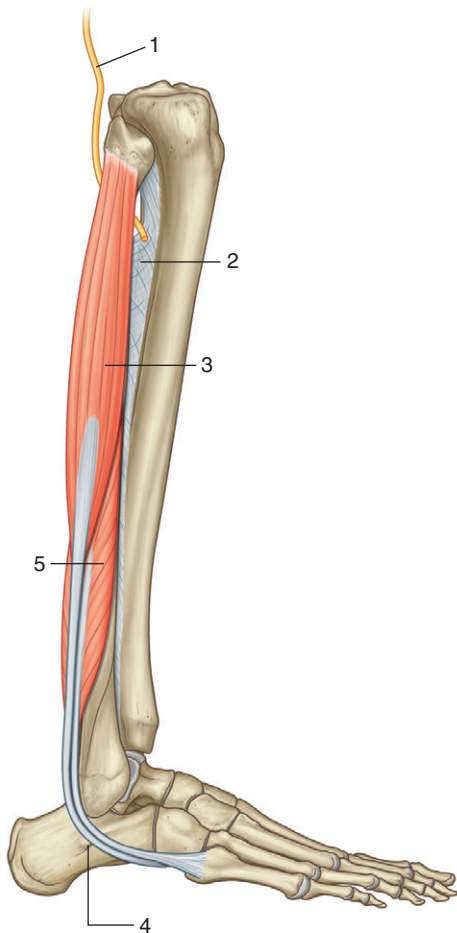
IN THE CLINIC:

- Lesions to the tibial nerve in the thigh result in loss of function of muscles in both the leg and the foot. Because nerves in general innervate muscles soon after entering a compartment, lesions of the nerves in the middle or near the end of their course through a compartment spare muscle function in that compartment but result in loss of function more distally. Therefore, lesions to the tibial nerve in the middle and lower leg result in loss of function of muscles in the foot and spare muscle function in the posterior compartment of the leg.

Figure from Gray's Anatomy for Students, 3rd edition, pp. 626-627.



Identify the indicated muscles.





LEG LATERAL COMPARTMENT: MUSCLES

1. Common fibular nerve
2. Interosseous membrane
3. Fibularis longus
4. Fibular trochlea of calcaneus bone
5. Fibularis brevis

IN THE CLINIC:

- **The fibular muscles are innervated by the superficial fibular nerve.**

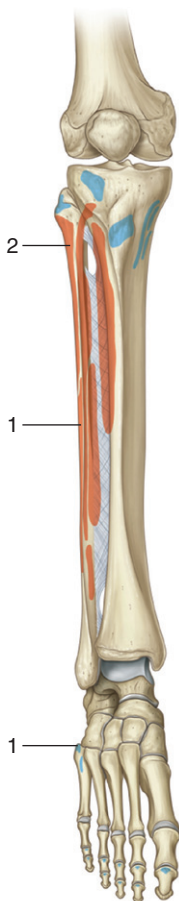
Figure from Gray's Anatomy for Students, 3rd edition, p. 627.



LEG LATERAL COMPARTMENT: MUSCLE ATTACHMENTS

170

*Identify the muscle and its attachments,
innervation, and actions.*





LEG LATERAL COMPARTMENT: MUSCLE ATTACHMENTS

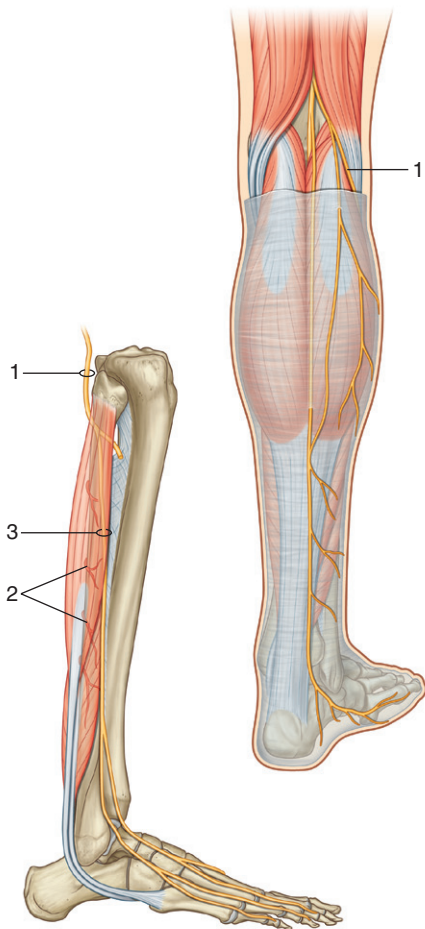


MUSCLES OF THE LATERAL COMPARTMENT OF LEG (SPINAL SEGMENTS IN BOLD ARE THE MAJOR SEGMENTS INNERVATING THE MUSCLE)

Muscle	Origin	Insertion	Innervation	Function
1. Fibularis brevis	Lower two thirds of lateral surface of shaft of fibula	Lateral tubercle at base of metatarsal V	Superficial fibular nerve (L5,S1,S2)	Eversion of foot
2. Fibularis longus	Upper lateral surface of fibula, head of fibula and occasionally the lateral tibial condyle	Undersurface of lateral sides of distal end of medial cuneiform and base of metatarsal I	Superficial fibular nerve (L5,S1,S2)	Eversion and plantarflexion of foot; supports arches of foot

Figure from Gray's Atlas of Anatomy, 2nd edition, p. 339.

Identify the indicated nerves and arteries.





LEG LATERAL COMPARTMENT: NERVES



1. Common fibular nerve
2. Perforating branches of fibular artery
3. Superficial fibular nerve

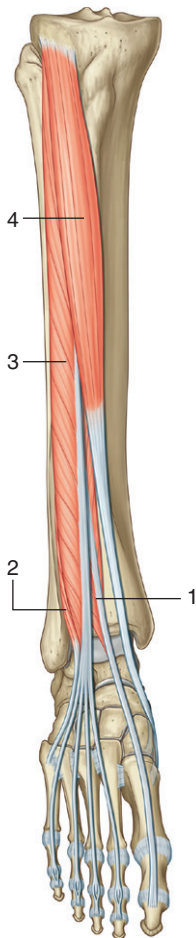
IN THE CLINIC:

- **The lateral compartment of the leg derives its blood supply from the fibular artery in the posterior compartment. Branches from this vessel perforate the intermuscular septum to enter the lateral compartment.**

Figure from Gray's Anatomy for Students, 3rd edition, p. 629.



Identify the indicated muscles.





LEG ANTERIOR COMPARTMENT: MUSCLES



1. Extensor hallucis longus
2. Fibularis tertius
3. Extensor digitorum longus
4. Tibialis anterior

IN THE CLINIC:

- **Muscles in the anterior compartment of the leg dorsiflex and invert the foot and extend the digits.**
- **Loss of motor function in the anterior compartment of the leg results in footdrop.**

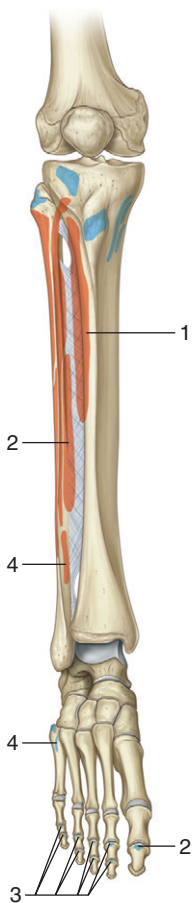
Figure from Gray's Anatomy for Students, 3rd edition, p. 630.



LEG ANTERIOR COMPARTMENT: MUSCLE ATTACHMENTS

173

Identify the muscle and its attachments, innervation, and actions.



LEG ANTERIOR COMPARTMENT: MUSCLE ATTACHMENTS

MUSCLES OF THE ANTERIOR COMPARTMENT OF LEG (SPINAL SEGMENTS IN BOLD ARE THE MAJOR SEGMENTS INNERVATING THE MUSCLE)

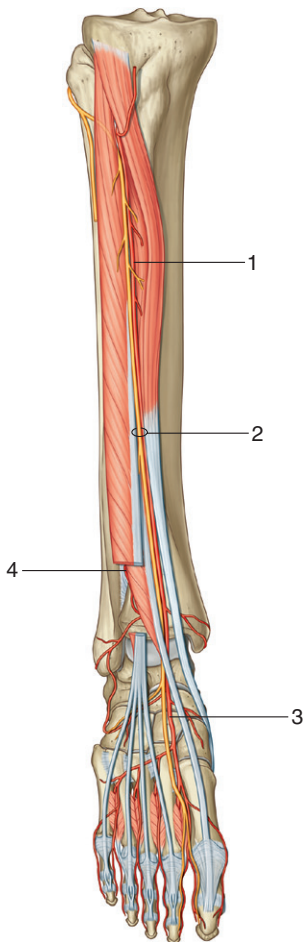
Muscle	Origin	Insertion	Innervation	Function
1. Tibialis anterior	Lateral surface of tibia and adjacent interosseous membrane	Medial and inferior surfaces of medial cuneiform and adjacent surfaces on base of metatarsal I	Deep fibular nerve (L4,L5)	Dorsiflexion of foot at ankle joint; inversion of foot; dynamic support of medial arch of foot
2. Extensor hallucis longus	Middle half of medial surface of fibula and adjacent surface of interosseous membrane	Dorsal surface of base of distal phalanx of great toe	Deep fibular nerve (L5,S1)	Extension of great toe and dorsiflexion of foot
3. Extensor digitorum longus	Proximal half of medial surface of fibula and related surface of lateral tibial condyle	Via dorsal digital expansions into bases of distal and middle phalanges of lateral four toes	Deep fibular nerve (L5,S1)	Extension of lateral four toes and dorsiflexion of foot
4. Fibularis tertius	Distal part of medial surface of fibula	Dorsomedial surface of base of metatarsal V	Deep fibular nerve (L5,S1)	Dorsiflexion and eversion of foot

Figure from Gray's Atlas of Anatomy, 2nd edition, p. 339.

LEG ANTERIOR COMPARTMENT: ARTERIES AND NERVES

174

Identify the indicated nerves and arteries.





LEG ANTERIOR COMPARTMENT: ARTERIES AND NERVES



1. Anterior tibial artery
2. Deep fibular nerve
3. Dorsalis pedis artery
4. Perforating branch of fibular artery

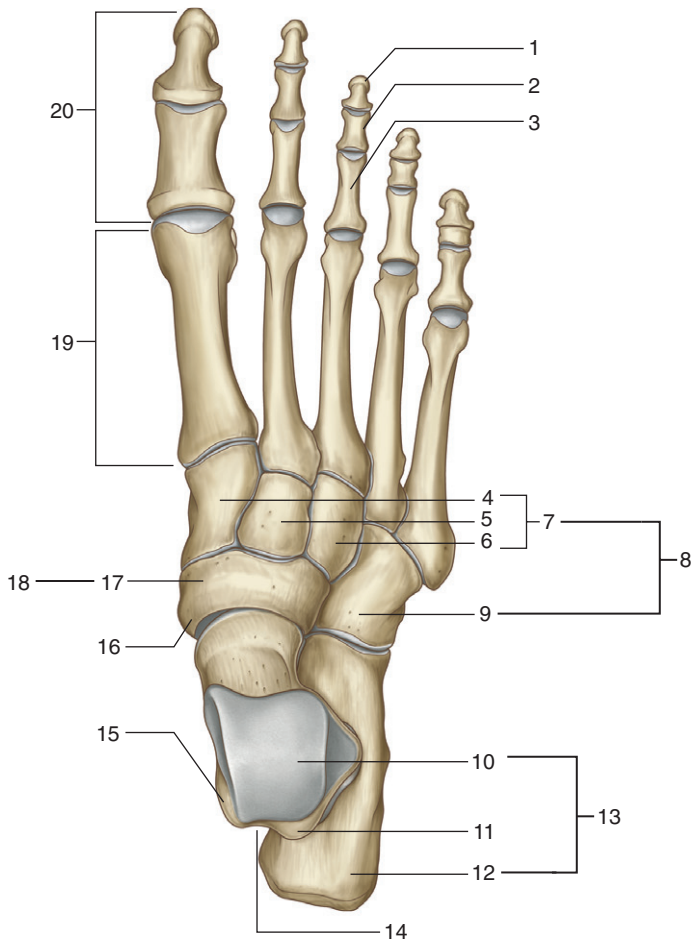
IN THE CLINIC:

- **All muscles in the anterior compartment of the leg are innervated by the deep fibular nerve. Terminal branches of the nerve innervate skin between the first and second toes. Sensation between the first and second toes can be used to monitor the status of the common or deep fibular nerve when motor function cannot be assessed, for example, when the leg and foot are in a cast.**
- **Loss of the common fibular nerve or the deep fibular nerve leads to footdrop.**

Figure from Gray's Anatomy for Students, 3rd edition, p. 632.



Identify the indicated bones.





1. Distal
2. Middle
3. Proximal
4. Medial
5. Intermediate
6. Lateral
7. Cuneiforms
8. Distal group of tarsal bones
9. Cuboid
10. Talus
11. Lateral tubercle
12. Calcaneus
13. Proximal group of tarsal bones
14. Groove for tendon of flexor hallucis longus
15. Medial tubercle
16. Tubercle (on undersurface)
17. Navicular
18. Intermediate tarsal bone
19. Metatarsals
20. Phalanges

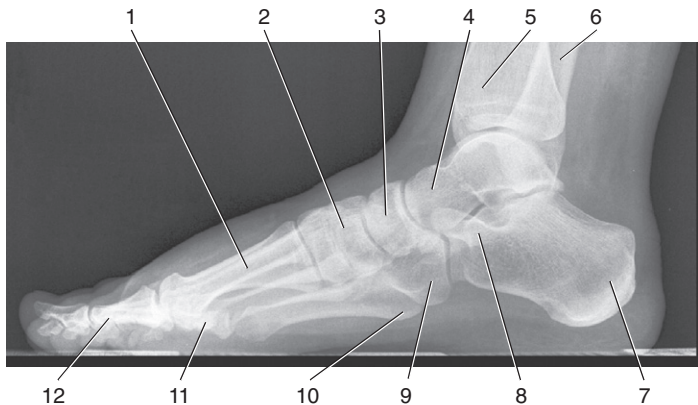
IN THE CLINIC:

- **The talus is the only bone of the foot that participates in forming the ankle joint.**

Figure from Gray's Anatomy for Students, 3rd edition, p. 634.



Identify the indicated structures.



RADIOGRAPH: FOOT

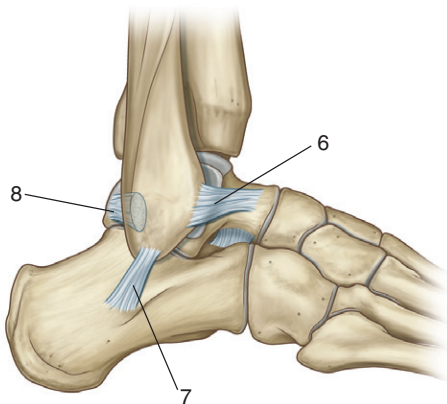
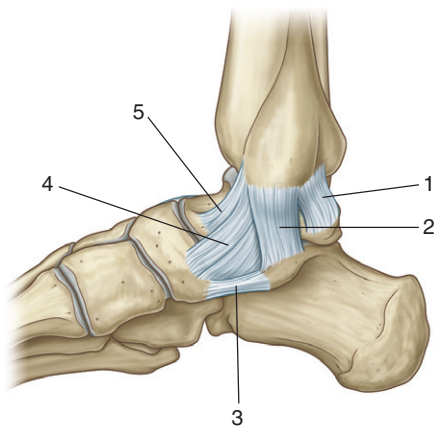


1. Metatarsals
2. Medial cuneiform
3. Navicular
4. Talus
5. Tibia
6. Fibula
7. Calcaneus
8. Sustenaculum tali
9. Cuboid
10. Tuberosity of fifth metatarsal bone
11. Sesamoid bone
12. Phalanges

Figure from Gray's Basic Anatomy, p. 319.



Identify the indicated ligaments.



FOOT: LIGAMENTS



1. Posterior tibiotalar part of the medial ligament of the ankle joint
2. Tibiocalcaneal part of the medial ligament of the ankle joint
3. Plantar calcaneonavicular ligament
4. Tibionavicular part of the medial ligament of the ankle joint
5. Anterior tibiotalar part of the medial ligament of the ankle joint
6. Anterior talofibular ligament
7. Calcaneofibular ligament
8. Posterior talofibular ligament

IN THE CLINIC:

- **The deltoid ligament consists of parts 1, 2, 4, and 5.**

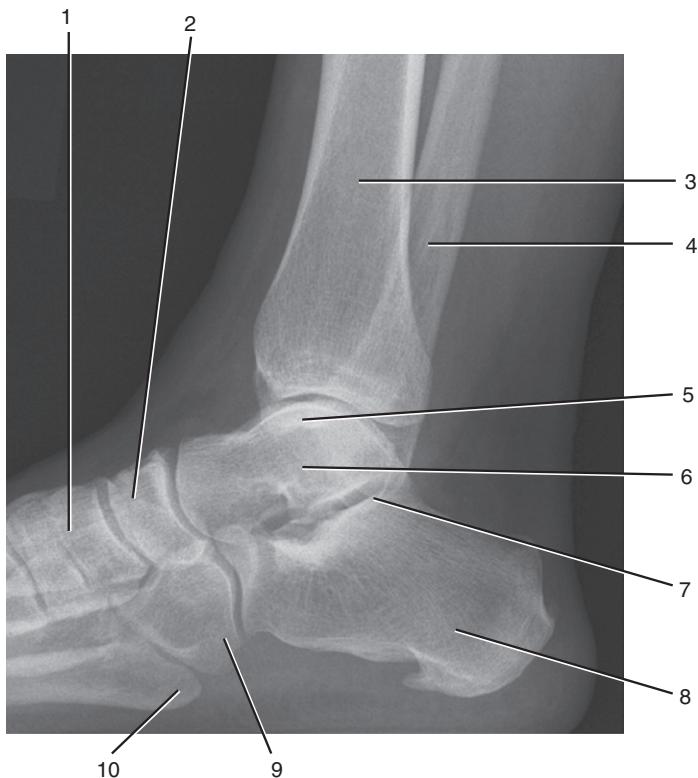
Figure from Gray's Anatomy for Students, 3rd edition, pp. 6399-640.



RADIOGRAPH: ANKLE

178

Identify the indicated structures.



RADIOGRAPH: ANKLE

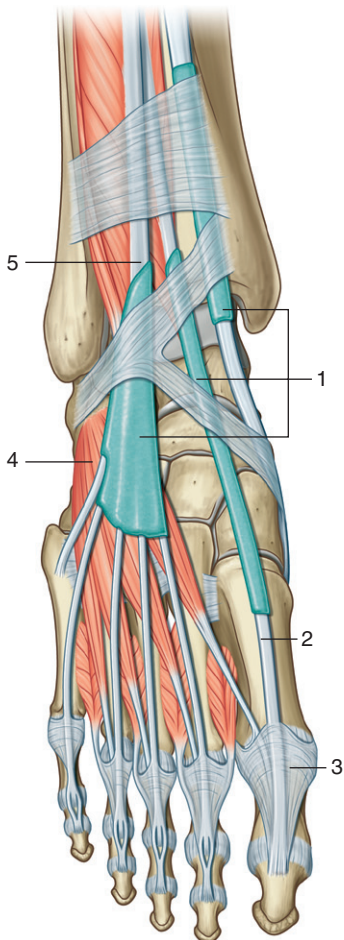


1. Cuneiforms
2. Navicular
3. Tibia
4. Fibula
5. Medial malleolus
6. Talus
7. Lateral malleolus
8. Calcaneus
9. Cuboid
10. Tuberosity of fifth metatarsal

Figure from Gray's Basic Anatomy, p. 322.



Identify the indicated muscle.





DORSAL FOOT: MUSCLES



1. Synovial sheaths
2. Extensor hallucis longus
3. Extensor hood
4. Extensor digitorum brevis
5. Extensor digitorum longus

IN THE CLINIC:

- **The extensor digitorum brevis is innervated by the deep fibular nerve.**

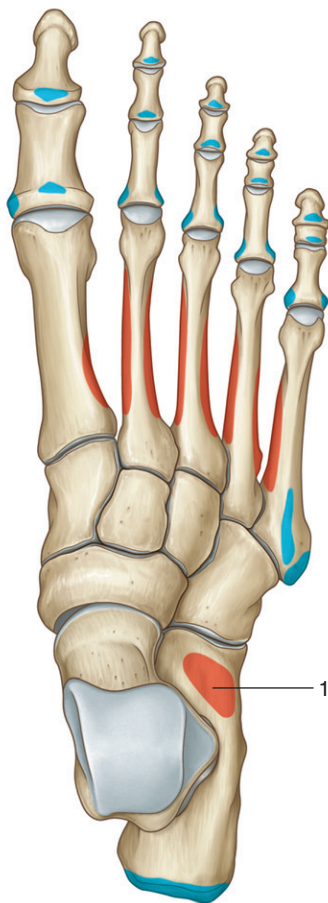
Figure from Gray's Anatomy for Students, 3rd edition, p. 651.



DORSAL FOOT: MUSCLE ATTACHMENTS

180

Identify the muscle and its attachments, innervation, and actions.





DORSAL FOOT: MUSCLE ATTACHMENTS



MUSCLE OF THE DORSAL ASPECT OF THE FOOT				
Muscle	Origin	Insertion	Innervation	Function
1. Extensor digitorum brevis	Superolateral surface of the calcaneus	Base of proximal phalanx of great toe and lateral sides of the tendons of extensor digitorum longus of toes II to IV	Deep fibular nerve (S1,S2)	Extension of metatarsophalangeal joint of great toe and extension of toes II to IV

Figure from Gray's Atlas of Anatomy, 2nd edition, p. 350.

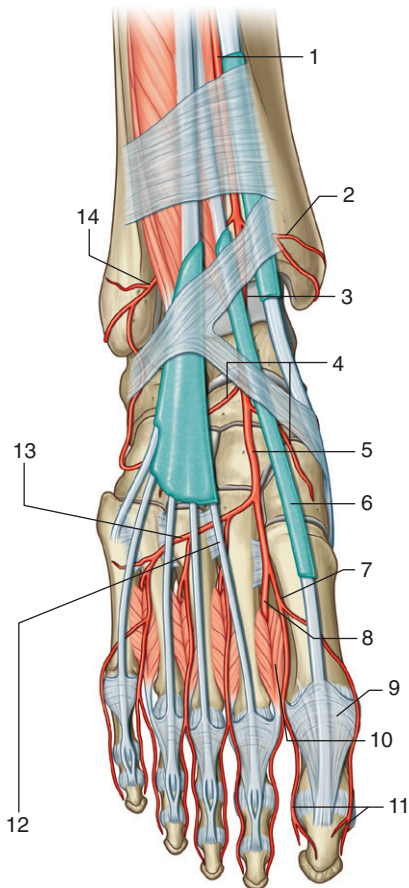
Figure from Gray's Atlas of Anatomy, 2nd edition, p. 350.



DORSAL FOOT: ARTERIES

181

Identify the indicated arteries, tendons, and muscles.



DORSAL FOOT: ARTERIES



1. Anterior tibial artery
2. Anterior medial malleolar artery
3. Dorsalis pedis artery
4. Medial and lateral tarsal branches
5. Dorsalis pedis artery
6. Extensor hallucis longus
7. First dorsal metatarsal muscle
8. Deep plantar artery
9. Extensor hood
10. First dorsal interosseous muscle
11. Dorsal digital arteries
12. Tendon of extensor digitorum longus to toe II
13. Arcuate artery
14. Anterior lateral malleolar artery

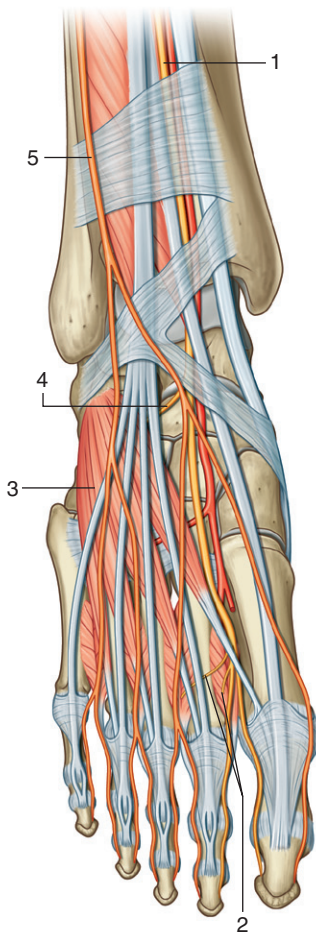
IN THE CLINIC:

- **The dorsalis pedis artery is palpable on the dorsal aspect of the foot between the tendon of the extensor hallucis longus muscle and the tendon of the extensor digitorum longus to the second toe.**

Figure from Gray's Anatomy for Students, 3rd edition, p. 651.



Identify the indicated nerves and muscles.



DORSAL FOOT: NERVES



1. Deep fibular nerve
2. Branches to first and second dorsal interosseous
3. Extensor digitorum brevis
4. Branch of deep fibular to extensor digitorum brevis
5. Superficial fibular nerve

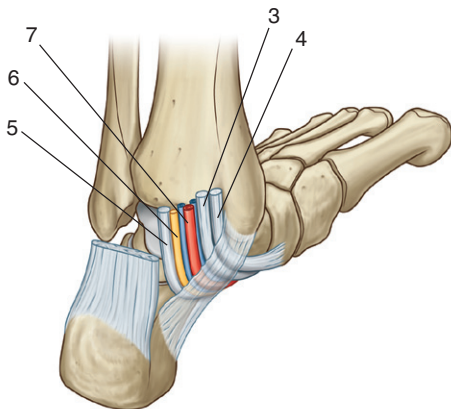
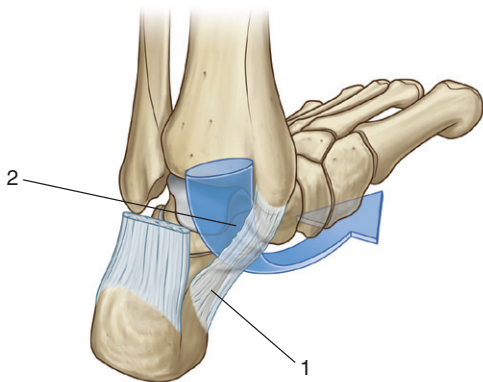
IN THE CLINIC:

- **Sensation in the web space between the first and second toes can be used to monitor the status of the fibular nerves when the leg and foot are in a cast.**

Figure from Gray's Anatomy for Students, 3rd edition, p. 661.



*Is this the left or the right foot?
Identify the indicated structures.*



TARSAL TUNNEL



This is the medial side of the left foot.

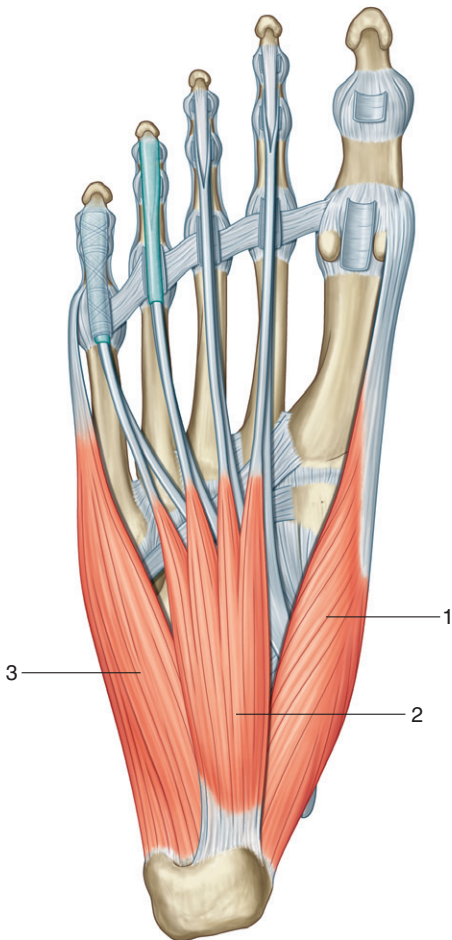
1. Flexor retinaculum
2. Tarsal tunnel
3. Tendon of flexor digitorum longus
4. Tendon of tibialis posterior
5. Tendon of flexor hallucis longus
6. Tibial nerve
7. Posterior tibial artery

IN THE CLINIC:

- **The pulse of the posterior tibial artery can be felt approximately midway between the medial malleolus and the calcaneus.**

Figure from Gray's Anatomy for Students, 3rd edition, p. 646.

Identify the indicated muscles.





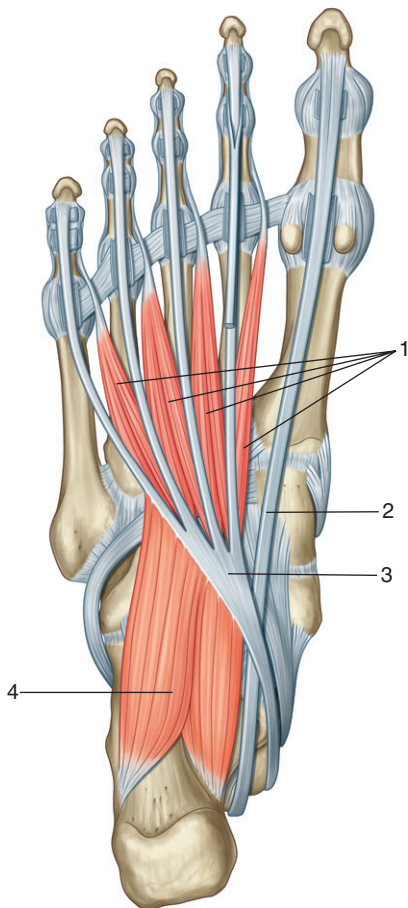
SOLE OF FOOT: MUSCLES, FIRST LAYER



1. Abductor hallucis
2. Flexor digitorum brevis
3. Abductor digiti minimi

Figure from Gray's Anatomy for Students, 3rd edition, p. 652.

Identify the indicated muscles and tendons.





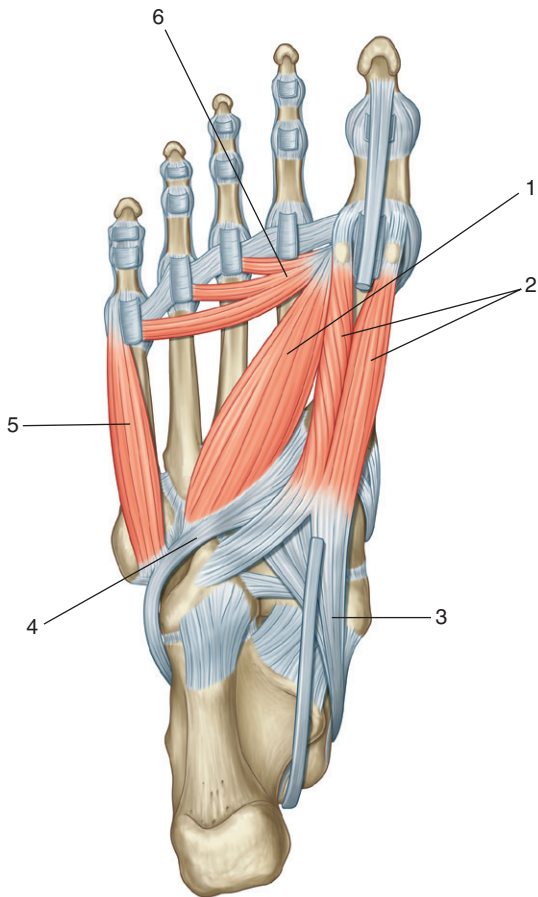
SOLE OF FOOT: MUSCLES, SECOND LAYER



1. Lumbrical muscles
2. Tendon of flexor hallucis longus
3. Tendon of flexor digitorum longus
4. Quadratus plantae

Figure from Gray's Anatomy for Students, 3rd edition, p. 653.

Identify the indicated muscles and tendons.





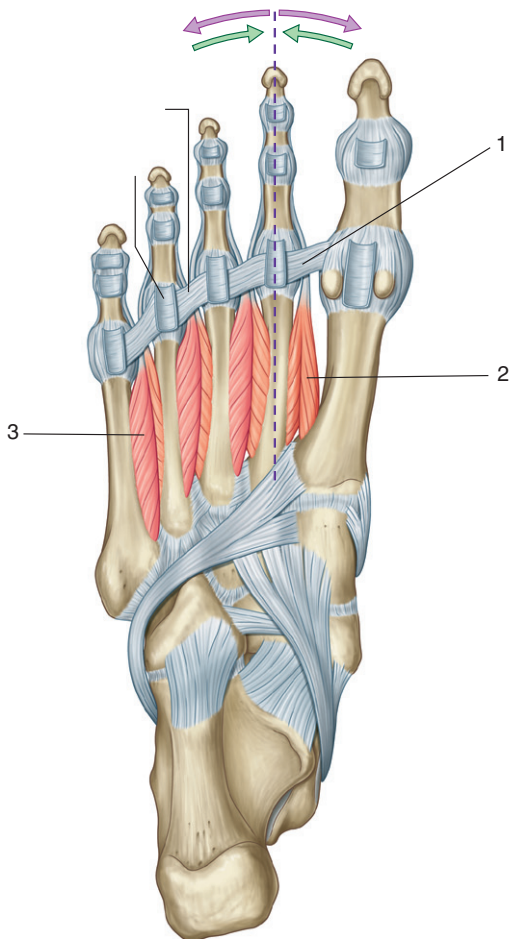
SOLE OF FOOT: MUSCLES, THIRD LAYER



1. Oblique head of adductor hallucis
2. Flexor hallucis brevis
3. Tendon of tibialis posterior
4. Tendon of fibularis longus
5. Flexor digiti minimi
6. Transverse head of adductor hallucis

Figure from Gray's Anatomy for Students, 3rd edition, p. 654.

Identify the indicated ligament and muscles.





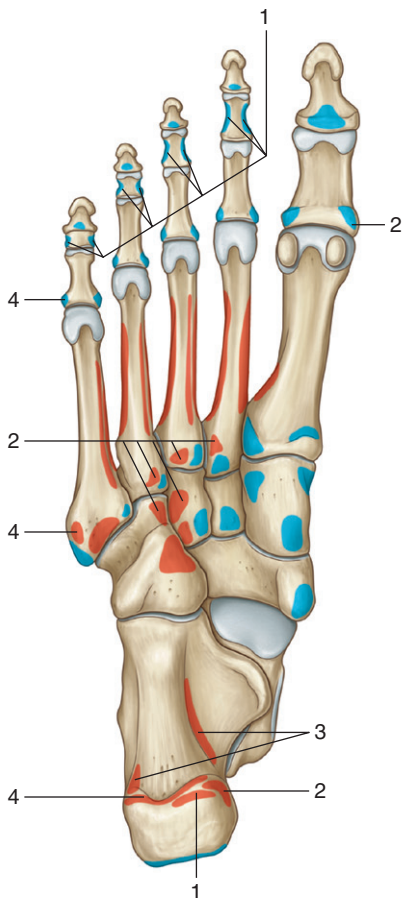
SOLE OF FOOT: MUSCLES, FOURTH LAYER



1. Deep transverse metatarsal ligament
2. First dorsal interosseous muscle
3. Third plantar interosseous muscle

Figure from Gray's Anatomy for Students, 3rd edition, p. 656.

Identify the muscle and its attachments, innervation, and actions.



SOLE OF FOOT: MUSCLE ATTACHMENTS, FIRST AND SECOND LAYERS

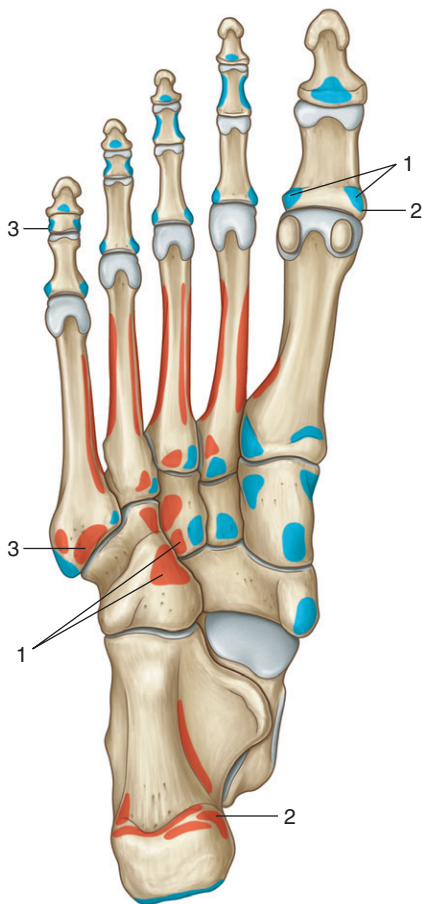
FIRST AND SECOND MUSCLE LAYERS IN THE SOLE OF THE FOOT (SPINAL SEGMENTS IN BOLD ARE THE MAJOR SEGMENTS INNERVATING THE MUSCLE)

Muscle	Origin	Insertion	Innervation	Function
1. Flexor digitorum brevis	Medial process of calcaneal tuberosity and plantar aponeurosis	Sides of plantar surface of middle phalanges of lateral four toes	Medial plantar nerve from the tibial nerve (S2,S3)	Flexes lateral four toes at proximal interphalangeal joint
2. Abductor hallucis	Medial process of calcaneal tuberosity	Medial side of base of proximal phalanx of great toe	Medial plantar nerve from the tibial nerve (S2,S3)	Abducts and flexes great toe at metatarsophalangeal joint
3. Quadratus plantae	Medial surface of calcaneus and lateral process of calcaneal tuberosity	Lateral side of tendon of flexor digitorum longus in proximal sole of the foot	Lateral plantar nerve from tibial nerve (S1 to S3)	Assists flexor digitorum longus tendon in flexing toes II to V
4. Abductor digiti minimi	Lateral and medial processes of calcaneal tuberosity, and band of connective tissue connecting calcaneus with base of metatarsal V	Lateral side of base of proximal phalanx of little toe	Lateral plantar nerve from tibial nerve (S2,S3)	Abducts little toe at the metatarsophalangeal joint

Figure from Gray's Atlas of Anatomy, 2nd edition, p. 350.

SOLE OF FOOT: MUSCLE
ATTACHMENTS, THIRD LAYER

Identify the muscle and its attachments, innervation, and actions.



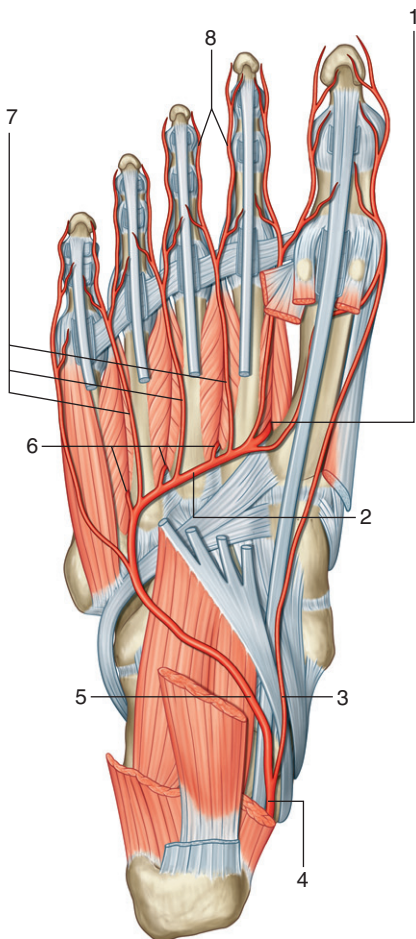
SOLE OF FOOT: MUSCLE ATTACHMENTS, THIRD LAYER

THIRD LAYER OF MUSCLES IN THE SOLE OF THE FOOT (SPINAL SEGMENTS IN BOLD ARE THE MAJOR SEGMENTS INNERVATING THE MUSCLE)

Muscle	Origin	Insertion	Innervation	Function
1. Flexor hallucis brevis	Plantar surface of cuboid and lateral cuneiform; tendon of tibialis posterior	Lateral and medial sides of base of proximal phalanx of the great toe	Medial plantar nerve from tibial nerve (S1,S2)	Flexes metatarsophalangeal joint of the great toe
2. Adductor hallucis	Transverse head—ligaments associated with metatarsophalangeal joints of lateral three toes; oblique head—bases of metatarsals II to IV and from sheath covering fibularis longus	Lateral side of base of proximal phalanx of great toe	Lateral plantar nerve from tibial nerve (S2,S3)	Adducts great toe at metatarsophalangeal joint
3. Flexor digiti minimi brevis	Base of metatarsal V and related sheath of fibularis longus tendon	Lateral side of base of proximal phalanx of little toe	Lateral plantar nerve from tibial nerve (S2,S3)	Flexes little toe at metatarsophalangeal joint

Figure from Gray's Atlas of Anatomy, 2nd edition, p. 350.

Identify the indicated arteries.





SOLE OF FOOT: ARTERIES



1. Deep plantar artery: terminal branch of dorsalis pedis artery
2. Deep plantar arch
3. Medial plantar artery
4. Posterior tibial artery
5. Lateral plantar artery
6. Perforating vessels
7. Plantar metatarsal artery
8. Digital branches

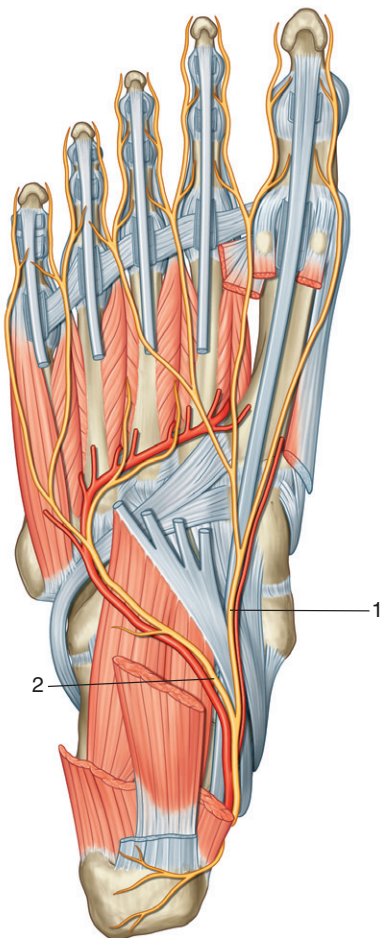
IN THE CLINIC:

- **The deep plantar arch connects with the posterior tibial artery through the lateral plantar artery and with the anterior tibial artery through the deep plantar artery.**

Figure from Gray's Anatomy for Students, 3rd edition, p. 657.



Identify the indicated nerves.



SOLE OF FOOT: NERVES



1. Medial plantar nerve
2. Lateral plantar nerve

IN THE CLINIC:

- **A lesion to the lateral plantar nerve results in loss of function of most intrinsic muscles in the sole of the foot except for three muscles (abductor hallucis, flexor digitorum brevis, and the first lumbrical) that are supplied by the medial plantar nerve. Also lost is sensation from skin on the lateral side of the sole of the foot.**
- **A lesion to the medial plantar nerve results in loss of sensation from a large area of the sole of the foot and in function of abductor hallucis, flexor digitorum brevis, and the first lumbrical.**

Figure from Gray's Anatomy for Students, 3rd edition, p. 660.



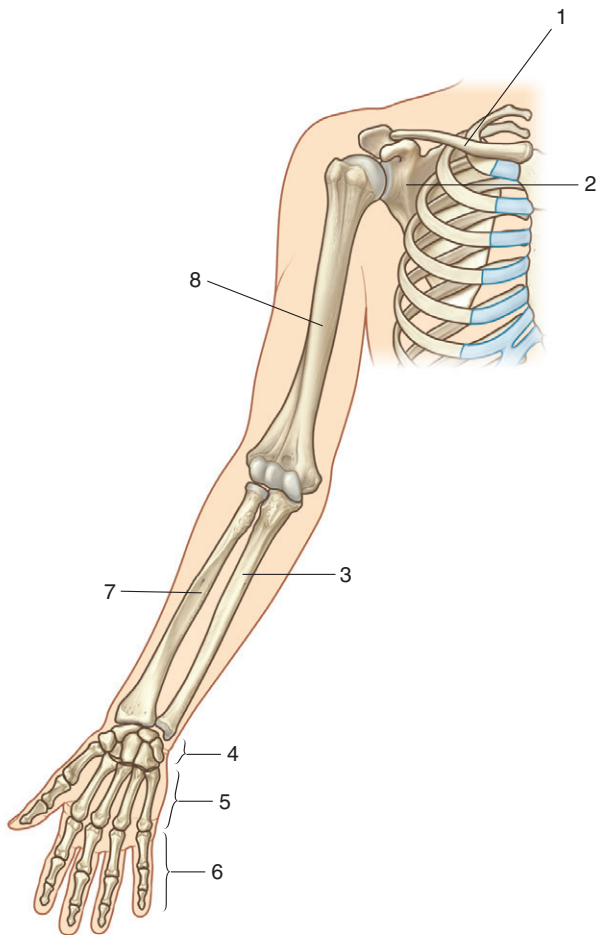
SECTION 7: UPPER LIMB



- 192. Overview: Skeleton
- 193. Clavicle
- 194. Scapula
- 195. Humerus
- 196. Sternoclavicular and Acromioclavicular Joints
- 197. Multidetector CT: Sternoclavicular Joint
- 198. Radiograph: Acromioclavicular Joint
- 199. Shoulder Joint
- 200. Radiograph: Glenohumeral Joint
- 201. Pectoral Region: Breast
- 202. Pectoralis Major
- 203. Pectoralis Minor: Nerves and Vessels
- 204. Posterior Scapular Region: Muscles
- 205. Posterior Scapular Region: Muscle Attachments
- 206. Posterior Scapular Region: Arteries and Nerves
- 207. Axilla: Vessels
- 208. Axilla: Arteries
- 209. Axilla: Nerves
- 210. Axilla: Brachial Plexus
- 211. Axilla: Lymphatics
- 212. Humerus: Posterior View
- 213. Distal Humerus
- 214. Proximal End of Radius and Ulna
- 215. Arm Anterior Compartment: Biceps
- 216. Arm Anterior Compartment: Muscles
- 217. Arm Anterior Compartment: Muscle Attachments
- 218. Arm Anterior Compartment: Arteries
- 219. Arm Anterior Compartment: Veins
- 220. Arm Anterior Compartment: Nerves
- 221. Arm Posterior Compartment: Muscles
- 222. Arm Posterior Compartment: Muscle Attachments
- 223. Arm Posterior Compartment: Nerves and Vessels
- 224. Elbow Joint
- 225. Cubital Fossa
- 226. Radius
- 227. Ulna
- 228. Radiographs: Elbow Joint
- 229. Radiograph: Forearm

- 
- 
230. Wrist and Bones of Hand
 231. Radiograph: Wrist
 232. Radiographs: Hand and Wrist Joint
 233. Forearm Anterior Compartment: Muscles, First Layer
 234. Forearm Anterior Compartment: Muscle Attachments, Superficial Layer
 235. Forearm Anterior Compartment: Muscles, Second Layer
 236. Forearm Anterior Compartment: Muscles, Third Layer
 237. Forearm Anterior Compartment: Muscle Attachments, Intermediate and Deep Layers
 238. Forearm Anterior Compartment: Arteries
 239. Forearm Anterior Compartment: Nerves
 240. Forearm Posterior Compartment: Muscles, Superficial Layer
 241. Forearm Posterior Compartment: Muscle Attachments, Superficial Layer
 242. Forearm Posterior Compartment: Outcropping Muscles
 243. Forearm Posterior Compartment: Muscle Attachments, Deep Layer
 244. Forearm Posterior Compartment: Nerves and Arteries
 245. Hand: Cross Section through Wrist
 246. Hand: Superficial Palm
 247. Hand: Thenar and Hypothenar Muscles
 248. Palm of Hand: Muscle Attachments, Thenar and Hypothenar Muscles
 249. Lumbricals
 250. Adductor Muscles
 251. Interosseous Muscles
 252. Palm of Hand: Muscle Attachments
 253. Superficial Palmar Arch
 254. Deep Palmar Arch
 255. Median Nerve
 256. Ulnar Nerve
 257. Radial Nerve
 258. Dorsal Venous Arch

Identify the indicated bones.



OVERVIEW: SKELETON



1. Clavicle
2. Scapula
3. Ulna
4. Carpals
5. Metacarpals
6. Phalanges
7. Radius
8. Humerus

IN THE CLINIC:

- **The clavicle is the only bony attachment between the upper limb and trunk. Because it is involved with transferring forces from the upper limb to the trunk, it can easily be fractured.**

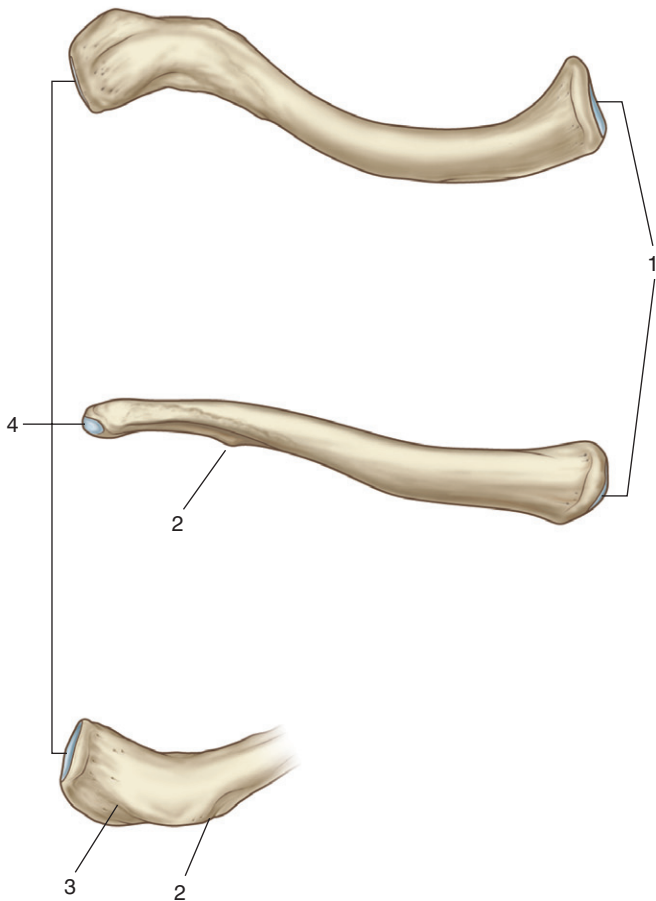
Figure from Gray's Anatomy for Students, 3rd edition, p. 690.



CLAVICLE

193

*Is this bone from the right or left side of the body?
Identify the indicated features.*



CLAVICLE



This bone is from the right side of the body.

1. Surface for articulation with manubrium and first costal cartilage
2. Conoid tubercle
3. Trapezoid line
4. Surface for articulation with acromion

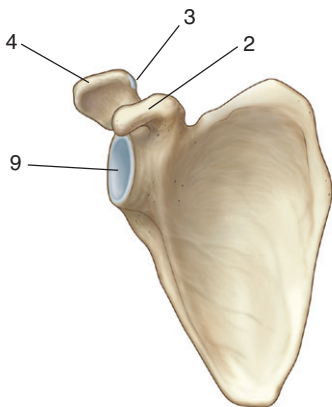
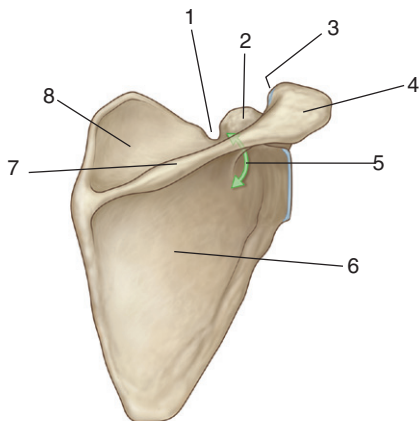
IN THE CLINIC:

- **The clavicle is usually fractured medial to the conoid tubercle because the middle third of the bone is not reinforced with ligaments or muscles.**
- **The anterosuperior surface of the clavicle is palpable along its length.**

Figure from Gray's Anatomy for Students, 3rd edition, p. 702.



*Is this bone from the right or left side of the body?
Identify the indicated features.*



SCAPULA



This bone is from the right side of the body.

1. Suprascapular notch
2. Coracoid process
3. Articular surface for clavicle
4. Acromion
5. Greater scapular notch/spinoglenoid notch
6. Infraspinous fossa
7. Spine of scapula
8. Supraspinous fossa
9. Glenoid cavity

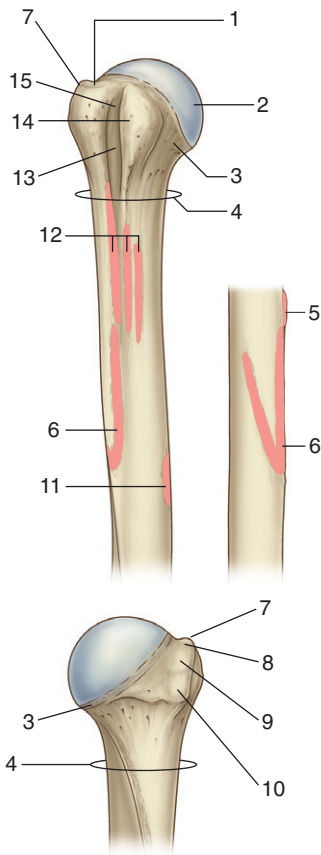
IN THE CLINIC:

- **The scapula is embedded in muscles and rarely fractured. The spine and acromion are palpable along their lengths. The inferior angle and medial margin also can easily be felt through the skin.**

Figure from Gray's Anatomy for Students, 3rd edition, p. 703.



*Is this bone from the right or left side of the body?
Identify the indicated features.*





HUMERUS



This bone is from the right side of the body.

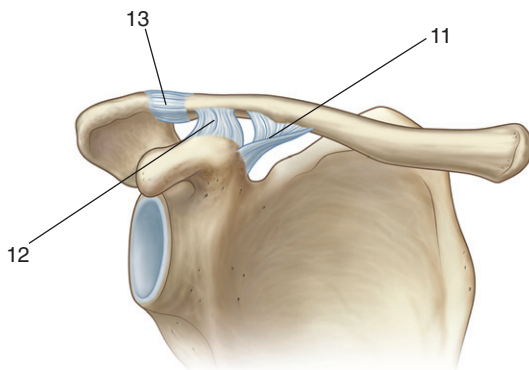
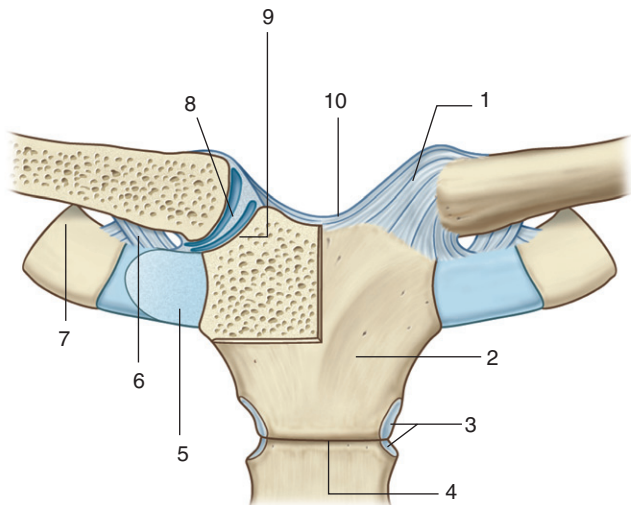
1. Superior facet on greater tubercle (attachment for supraspinatus muscle)
2. Head
3. Anatomical neck
4. Surgical neck
5. Attachment for pectoralis major muscle
6. Deltoid tuberosity (attachment for deltoid muscle)
7. Greater tubercle
8. Superior facet (attachment for supraspinatus muscle)
9. Middle facet (attachment for infraspinatus muscle)
10. Inferior facet (attachment for teres minor muscle)
11. Attachment for coracobrachialis muscle
12. Lateral lip, floor, and medial lip of intertubercular sulcus (attachment for pectoralis major, latissimus dorsi, and teres major muscles respectively)
13. Intertubercular sulcus
14. Lesser tubercle (attachment for subscapularis)
15. Intertubercular sulcus

IN THE CLINIC:

- **The three most common sites of humeral fracture are (1) the surgical neck, (2) midshaft, and (3) supracondylar.**

Figure from Gray's Anatomy for Students, 3rd edition, p. 704.

Identify the indicated ligaments and structures.





STERNOCLAVICULAR AND ACROMIOCLAVICULAR JOINTS



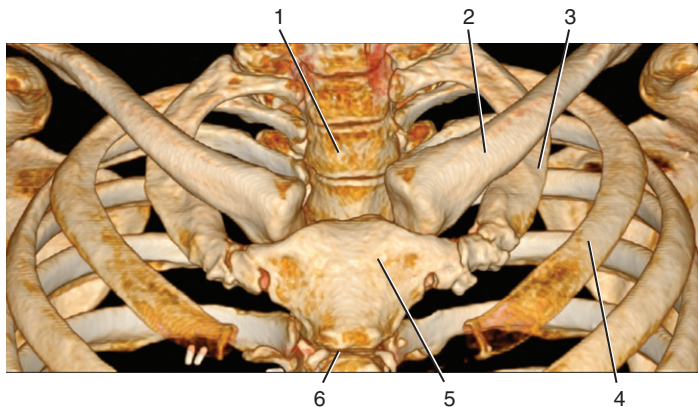
1. Anterior sternoclavicular ligament
2. Manubrium of sternum
3. Attachment site for rib II
4. Sternal angle
5. First costal cartilage
6. Costoclavicular ligament
7. Rib I
8. Articular disc (capsule and ligaments removed anteriorly to expose joint)
9. Clavicular notch
10. Interclavicular ligament
11. Conoid part of coracoclavicular ligament
12. Trapezoid part of coracoclavicular ligament
13. Acromioclavicular ligament

IN THE CLINIC:

- **The coracoclavicular ligament is a much stronger attachment between the scapula and clavicle than is the acromioclavicular joint. In a clavicular fracture medial to the coracoclavicular ligament, the “shoulder” droops.**

Figure from Gray's Anatomy for Students, 3rd edition, pp. 705-706.

Identify the indicated structures.



MULTIDETECTOR CT: STERNOCLAVICULAR JOINT



1. Vertebral body of TII
2. Left clavicle
3. Rib I
4. Rib II
5. Manubrium of sternum
6. Sternal angle

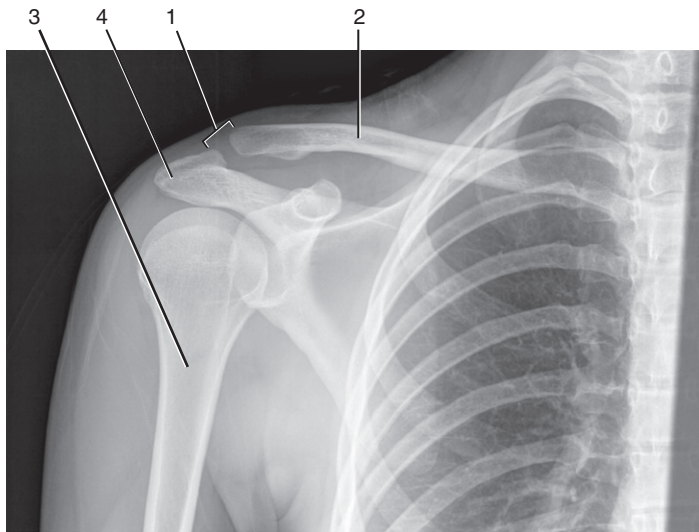
Figure from Gray's Basic Anatomy, p. 347.



RADIOGRAPH: ACROMIOCLAVICULAR JOINT

198

Identify the indicated structures.





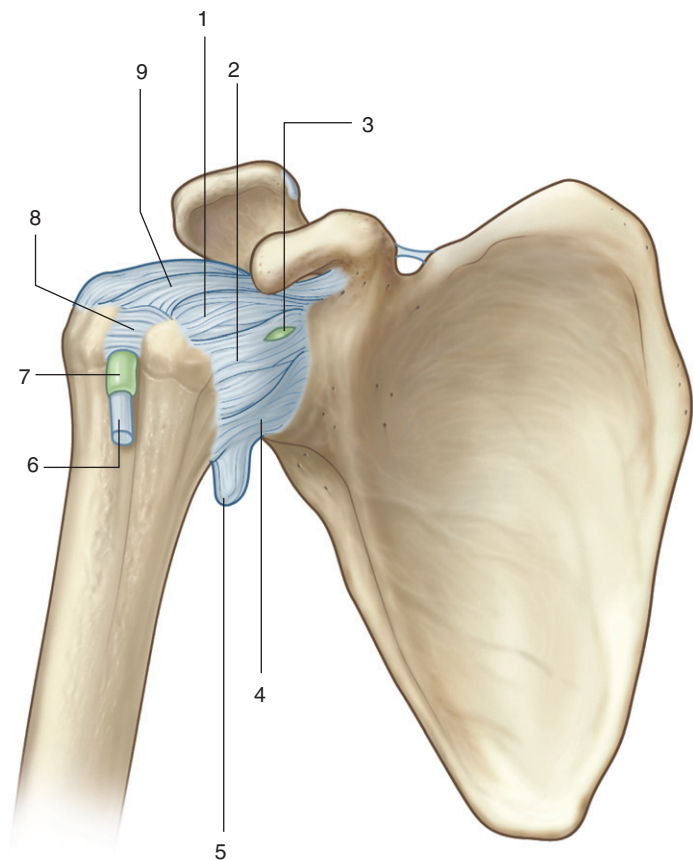
RADIOGRAPH: ACROMIOCLAVICULAR JOINT



1. Acromioclavicular joint
2. Clavicle
3. Humerus
4. Acromion

Figure from Gray's Basic Anatomy, p. 347.

Identify the indicated ligaments and associated structures.



SHOULDER JOINT



1. Superior glenohumeral ligament
2. Middle glenohumeral ligament
3. Aperture for subtendinous bursa of subscapularis muscle
4. Inferior glenohumeral ligament
5. Redundant capsule
6. Tendon of long head of biceps brachii muscle
7. Synovial sheath
8. Transverse humeral ligament
9. Coracohumeral ligament

IN THE CLINIC:

- **Much of the support for the glenohumeral joint is provided by the rotator cuff muscles and not ligaments. Dislocation of the humerus most often occurs inferiorly because this region has the least amount of support.**

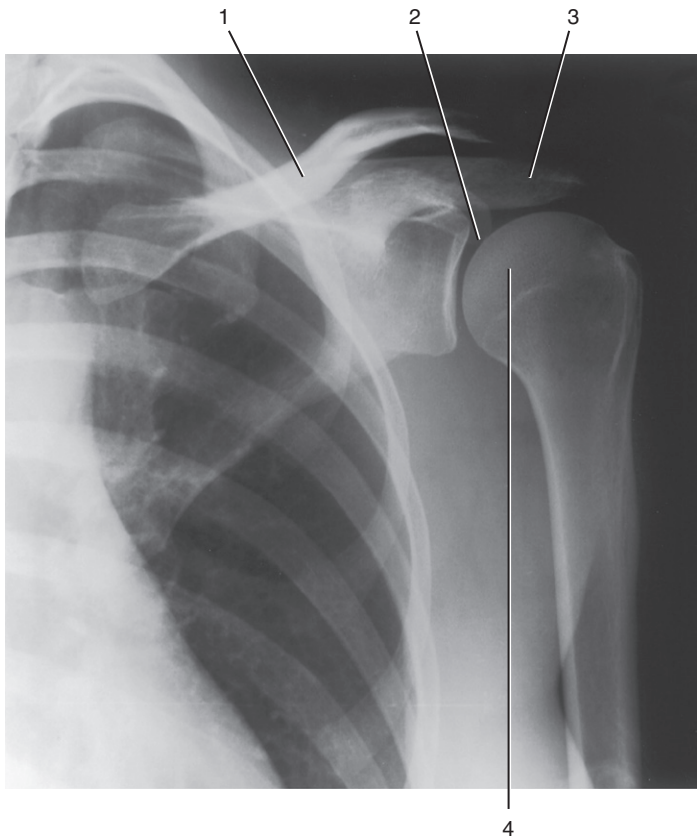
Figure from Gray's Anatomy for Students, 3rd edition, p. 708.



RADIOGRAPH: GLENOHUMERAL JOINT

200

Identify the indicated structures.





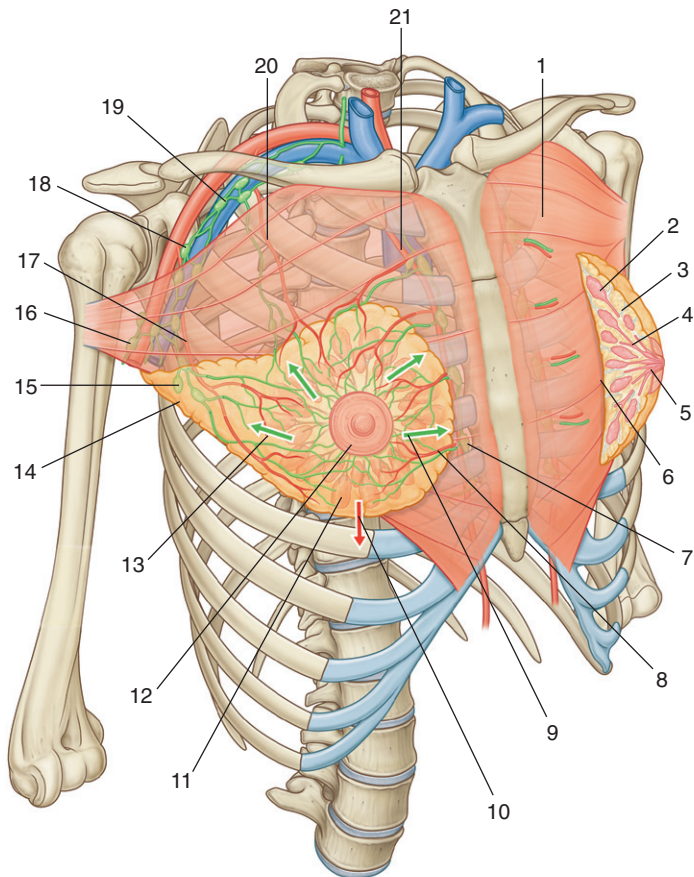
RADIOGRAPH: GLENOHUMERAL JOINT



1. Clavicle
2. Glenoid cavity
3. Acromion
4. Head of humerus

Figure from Gray's Basic Anatomy, p. 348.

Identify the indicated structures.





1. Pectoralis major muscle
2. Secretory lobule of mammary gland
3. Suspensory ligaments
4. Lactiferous ducts
5. Lactiferous sinuses
6. Retromammary space
7. Parasternal lymph nodes
8. Mammary branches of internal thoracic artery
9. Lymphatic and venous drainage passes from medial part of the breast parasternally
10. Lymphatic and venous drainage passes from inferior part of the breast into the anterior abdominal wall
11. Secretory lobules of mammary gland
12. Areola
13. Lymphatic and venous drainage passes from lateral and superior part of the breast into axilla
14. Axillary process of mammary gland
15. Pectoral axillary nodes
16. Lateral axillary nodes
17. Lateral thoracic artery
18. Central axillary nodes
19. Apical axillary nodes
20. Pectoral branch of thoraco-acromial artery
21. Internal thoracic artery

IN THE CLINIC:

- **Breast cancer is one of the most common cancers in women. One of the routes of metastatic spread is through lymphatic vessels that drain laterally into lymph nodes in the axilla and medially into nodes associated with the internal thoracic vessels.**

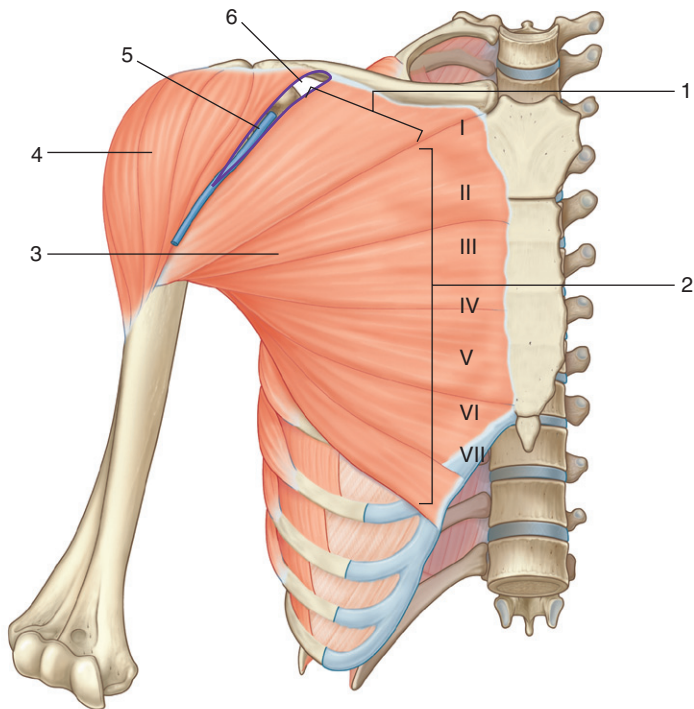
Figure from Gray's Anatomy for Students, 3rd edition, p. 140.



PECTORALIS MAJOR

202

Identify the indicated muscles and vessel.



PECTORALIS MAJOR



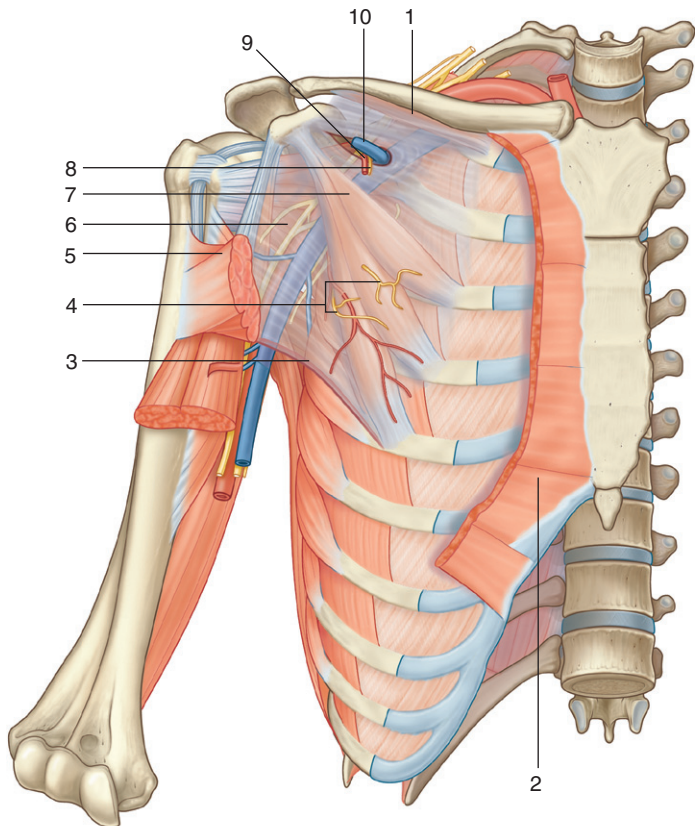
1. Clavicular head of pectoralis major muscle
2. Sternocostal head of pectoralis major muscle
3. Pectoralis major muscle
4. Deltoid muscle
5. Cephalic vein
6. Clavipectoral triangle

IN THE CLINIC:

- **The cephalic vein can be accessed for certain medical procedures in the clavipectoral triangle formed by the middle third of the clavicle, the deltoid muscle, and the pectoralis major muscle.**

Figure from Gray's Anatomy for Students, 3rd edition, p. 724.

Identify the indicated structures.



PECTORALIS MINOR: NERVES AND VESSELS



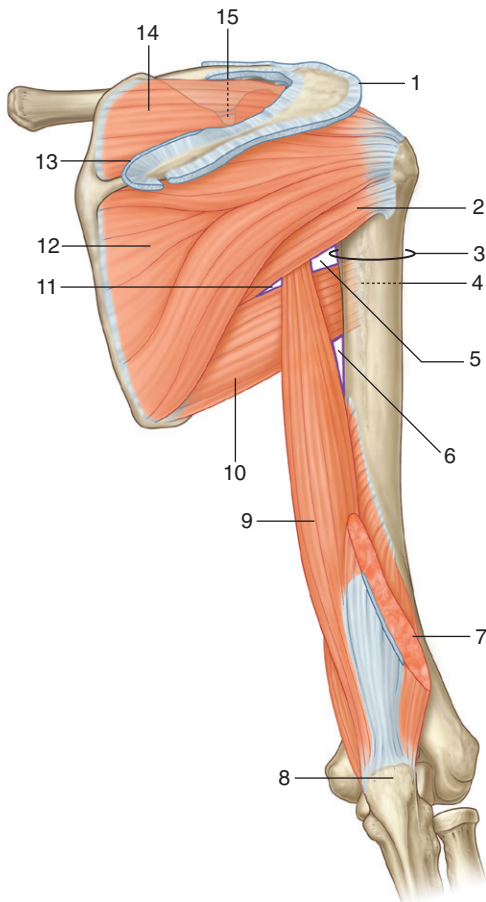
1. Subclavius muscle
2. Pectoralis major muscle
3. Attachment of fascia to floor of axilla
4. Medial pectoral nerves
5. Pectoralis major muscle (cut)
6. Clavipectoral fascia
7. Pectoralis minor muscle
8. Lateral pectoral nerve
9. Pectoral branch of thoraco-acromial artery
10. Cephalic vein

IN THE CLINIC:

- During surgery, the pectoralis minor muscle is an important landmark. It lies immediately anterior to the cords of the brachial plexus and second part of the axillary artery. The thoraco-acromial artery is related to the upper or medial margin of the muscle, and the lateral thoracic artery is related to the lower or lateral margin.

Figure from Gray's Anatomy for Students, 3rd edition, p. 725.

Identify the indicated muscles, spaces, and features.



POSTERIOR SCAPULAR REGION: MUSCLES



1. Cut edge of deltoid muscle
2. Teres minor muscle
3. Surgical neck of humerus
4. Medial lip of intertubercular sulcus
5. Quadrangular space
6. Triangular interval
7. Cut edge of lateral head of triceps brachii muscle
8. Olecranon
9. Long head of triceps brachii muscle
10. Teres major muscle
11. Triangular space
12. Infraspinatus muscle
13. Cut edge of trapezius muscle
14. Supraspinatus muscle
15. Suprascapular notch (foramen)

IN THE CLINIC:

- The rotator cuff muscles are the supraspinatus muscle, the infraspinatus muscle, the teres minor muscle, and the subscapularis muscle. All except the subscapularis muscle are located in the posterior scapular region. Loss of function of the supraspinatus muscle leads to the inability to initiate abduction of the arm at the shoulder joint. Testing abduction and medial and lateral rotation of the humerus at the shoulder joint tests motor function mainly of spinal cord levels C5 and C6.

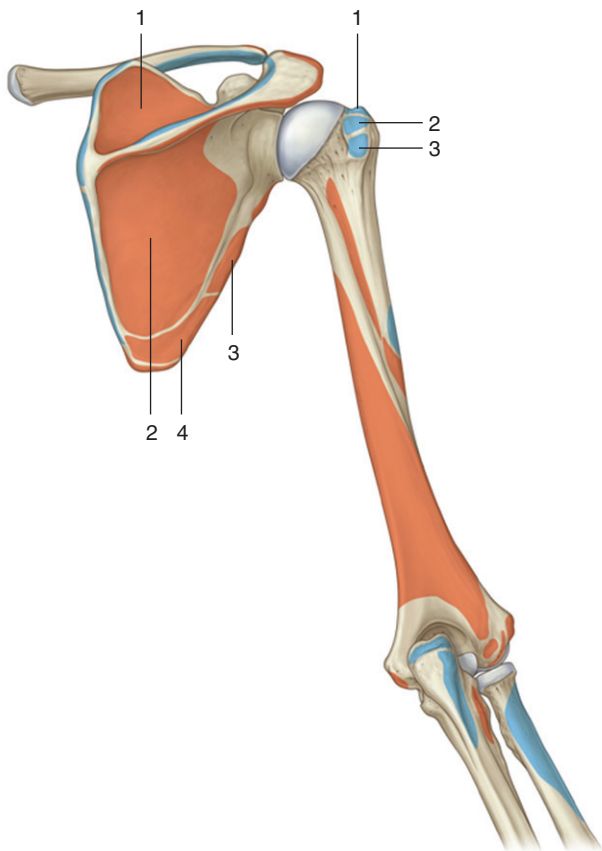
Figure from Gray's Anatomy for Students, 3rd edition, p. 716.



POSTERIOR SCAPULAR REGION: MUSCLE ATTACHMENTS

205

*Identify the muscles that attach to the areas indicated.
What is the major function and innervation of
each muscle?*

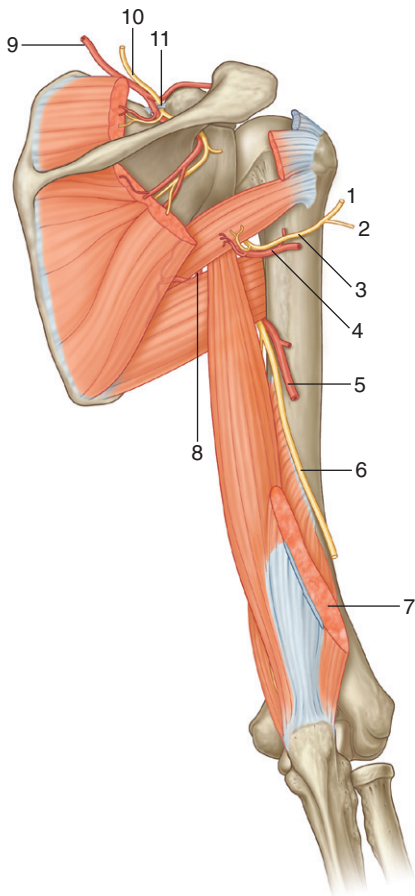


MUSCLES OF THE POSTERIOR SCAPULAR REGION (SPINAL SEGMENTS IN BOLD ARE THE MAJOR SEGMENTS INNERVATING THE MUSCLE)

Muscle	Origin	Insertion	Innervation	Function
1. Suprascapularis	Medial two thirds of the supraspinous fossa of the scapula and the deep fascia that covers the muscle	Most superior facet on the greater tubercle of the humerus	Suprascapular nerve (C5,C6)	Rotator cuff muscle; initiation of abduction of arm to 15 degrees at glenohumeral joint
2. Infraspinatus	Medial two thirds of the infraspinous fossa of the scapula and the deep fascia that covers the muscle	Middle facet on posterior surface of the greater tubercle of the humerus	Suprascapular nerve (C5,C6)	Rotator cuff muscle; lateral rotation of arm at the glenohumeral joint
3. Teres minor	Upper two thirds of a flattened strip of bone on the posterior surface of the scapula immediately adjacent to the lateral border of the scapula	Inferior facet on the posterior surface of the greater tubercle of the humerus	Axillary nerve (C5,C6)	Rotator cuff muscle; lateral rotation of arm at the glenohumeral joint
4. Teres major	Elongate oval area on the posterior surface of the inferior angle of the scapula	Medial lip of the intertubercular sulcus on the anterior surface of the humerus	Inferior subscapular nerve (C5 to C7)	Medial rotation and extension of the arm at the glenohumeral joint

Figure from Gray's Atlas of Anatomy, 2nd edition, p. 407.

Identify the indicated arteries, nerves, and associated structures.





POSTERIOR SCAPULAR REGION: ARTERIES AND NERVES



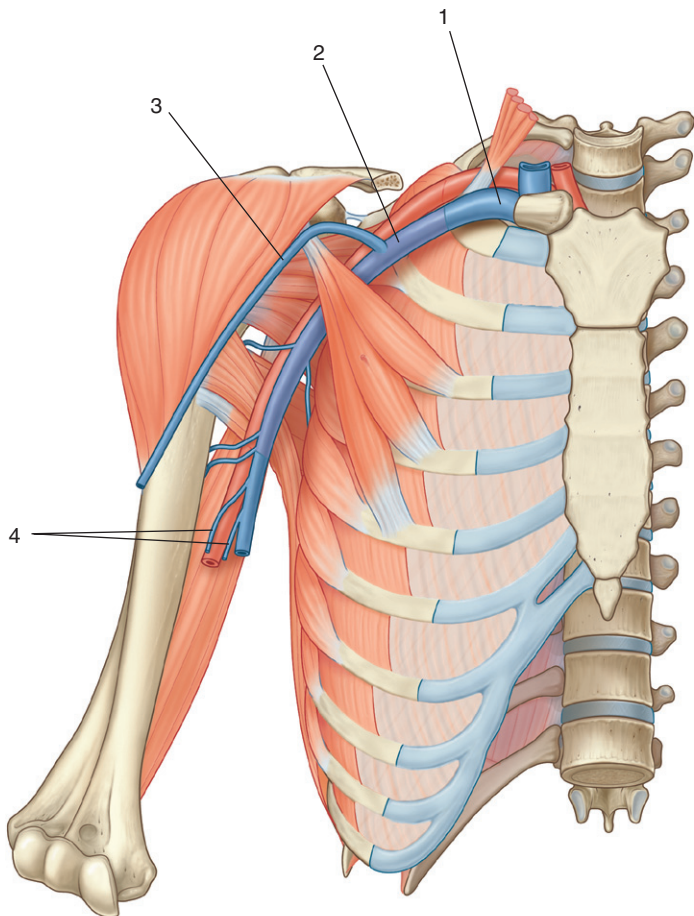
1. To deltoid muscle
2. To skin on lateral part of deltoid
3. Axillary nerve
4. Posterior circumflex humeral artery
5. Profunda brachii artery
6. Radial nerve
7. Cut edge of triceps brachii muscle
8. Circumflex scapular artery
9. Suprascapular artery
10. Suprascapular nerve
11. Superior transverse scapular ligament

IN THE CLINIC:

- A complete lesion to the suprascapular nerve at the suprascapular foramen results in an inability to initiate abduction of the arm at the shoulder joint and to a reduced ability to externally rotate the arm at the shoulder joint.
- Fracture of the surgical neck of the humerus can endanger the axillary nerve and posterior circumflex humeral artery. Complete loss of the axillary nerve results in sensory loss over a small area of skin covering the lateral surface of the deltoid (and loss of function of the deltoid and the teres minor muscles).
- Fracture to the shaft of the humerus can endanger the radial nerve. A lesion to the radial nerve in the spiral groove results in sensory loss from skin over the dorsolateral aspect of the hand and also in wristdrop and loss of the ability to supinate when the elbow is extended. Depending on the exact site of the lesion, triceps function can be spared.

Figure from Gray's Anatomy for Students, 3rd edition, p. 718.

Identify the indicated veins.





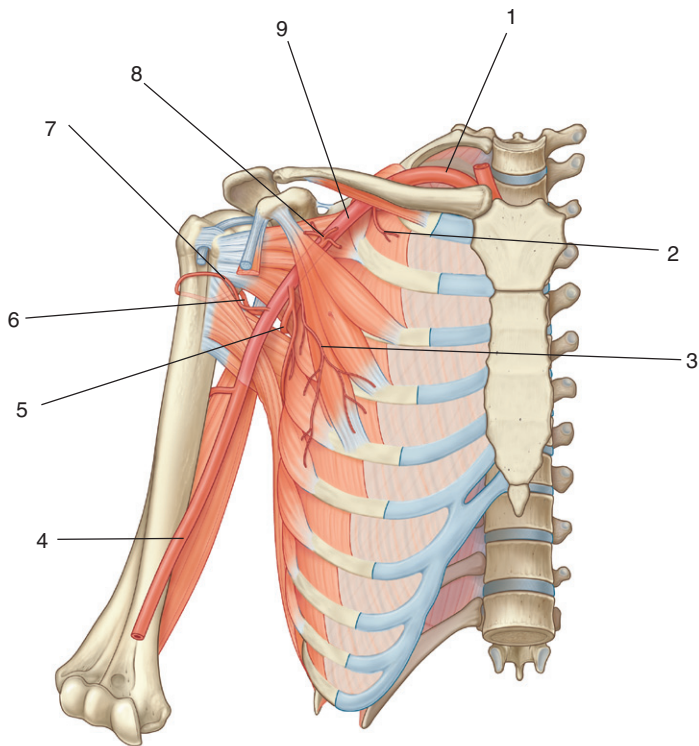
1. Subclavian vein
2. Axillary vein
3. Cephalic vein
4. Paired brachial veins

IN THE CLINIC:

- **The cephalic vein can be used to access the venous system. The vessel is located in the plane between the deltoid muscle and the pectoralis major muscle and passes deep through the clavipectoral triangle to join with the axillary vein.**

Figure from Gray's Anatomy for Students, 3rd edition, p. 736.

Identify the indicated arteries.



AXILLA: ARTERIES



1. Subclavian artery
2. Superior thoracic artery
3. Lateral thoracic artery
4. Brachial artery
5. Subscapular artery
6. Posterior circumflex humeral artery
7. Anterior circumflex humeral artery
8. Thoraco-acromial artery
9. Axillary artery

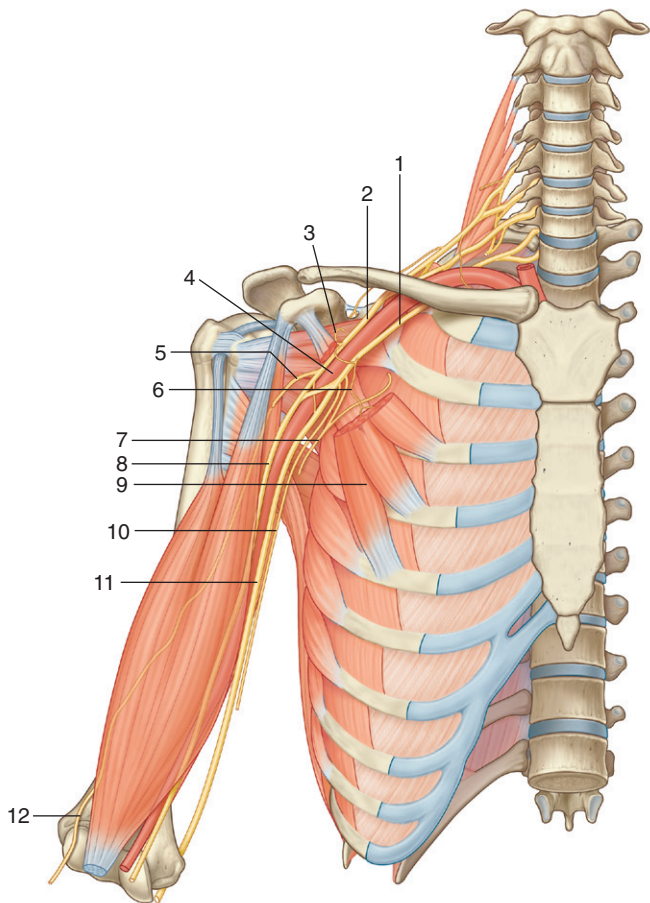
IN THE CLINIC:

- **Branches from the subclavian, axillary, and brachial artery form an anastomotic network of vessels around the scapula and upper end of the humerus. These connections can serve to maintain blood flow to the upper limb when the axillary artery is interrupted between the origin of the branches that contribute to the anastomoses.**

Figure from Gray's Anatomy for Students, 3rd edition, p. 734.



Identify the indicated nerves and associated structures.



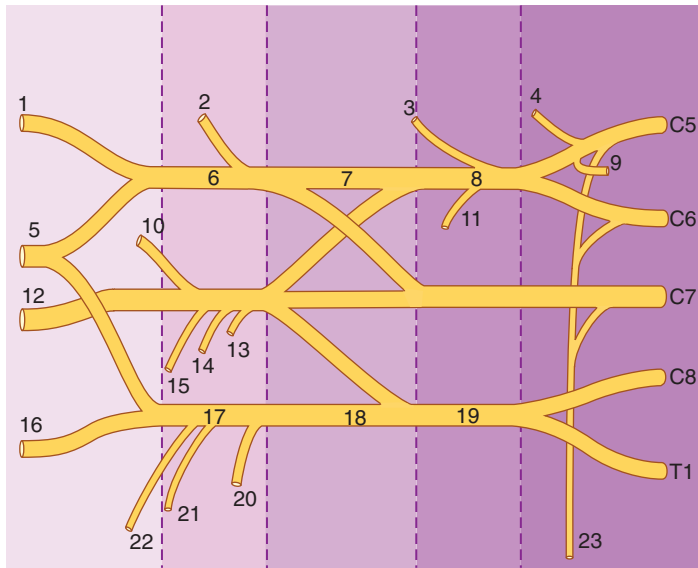
AXILLA: NERVES



1. Medial cord
2. Lateral cord
3. Lateral pectoral nerve
4. Axillary artery
5. Musculocutaneous nerve
6. Medial pectoral nerve
7. Medial cutaneous nerve of arm
8. Median nerve
9. Pectoralis minor muscle
10. Medial cutaneous nerve of forearm
11. Ulnar nerve
12. Lateral cutaneous nerve of forearm

Figure from Gray's Anatomy for Students, 3rd edition, p. 743.

Identify the indicated parts of the brachial plexus.

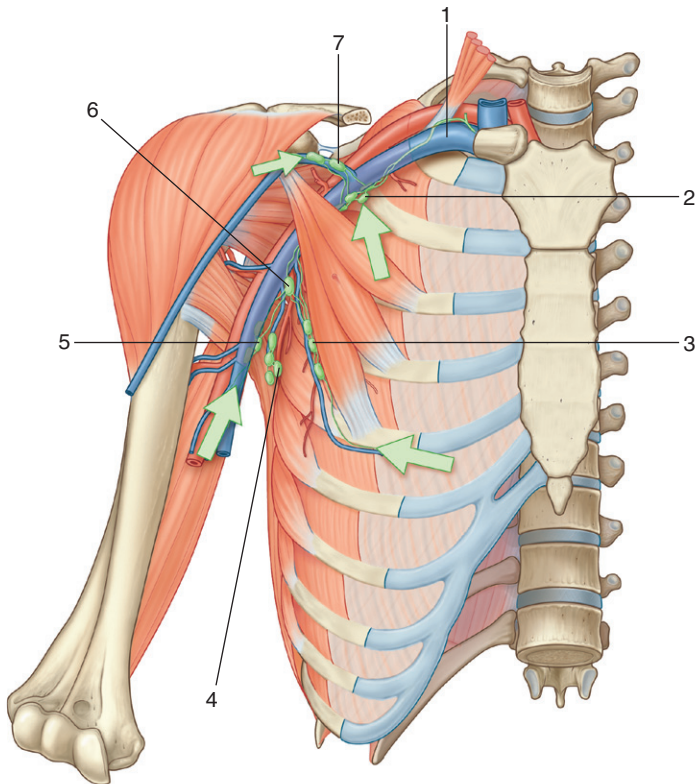


AXILLA: BRACHIAL PLEXUS

1. Musculocutaneous nerve
2. Lateral pectoral nerve
3. Suprascapular nerve
4. Dorsal scapular nerve
5. Median nerve
6. Lateral cord
7. Anterior division of superior trunk
8. Superior trunk
9. Contribution to phrenic nerve
10. Axillary nerve
11. Nerve to subclavius
12. Radial nerve
13. Superior subscapular nerve
14. Thoracodorsal nerve
15. Inferior subscapular nerve
16. Ulnar nerve
17. Medial cord
18. Anterior division of inferior trunk
19. Inferior trunk
20. Medial pectoral nerve
21. Medial cutaneous nerve of arm
22. Medial cutaneous nerve of forearm
23. Long thoracic nerve

Figure from Gray's Anatomy for Students, 3rd edition, p. 740.

Identify the indicated lymph nodes and vessels.



AXILLA: LYMPHATICS

1. Right subclavian vein
2. Apical nodes
3. Pectoral nodes
4. Subscapular nodes
5. Humeral nodes
6. Central nodes
7. Infraclavicular nodes

IN THE CLINIC:

- **Lymph from the upper limb drains into axillary lymph nodes. Therefore, infections and some other pathologies in the upper limb can be detected by assessing changes in the size and texture of nodes in the axilla. Importantly, axillary nodes receive lymph from the lateral and superior parts of the breast. As a consequence, changes in axillary nodes may indicate a pathologic process in the breast.**

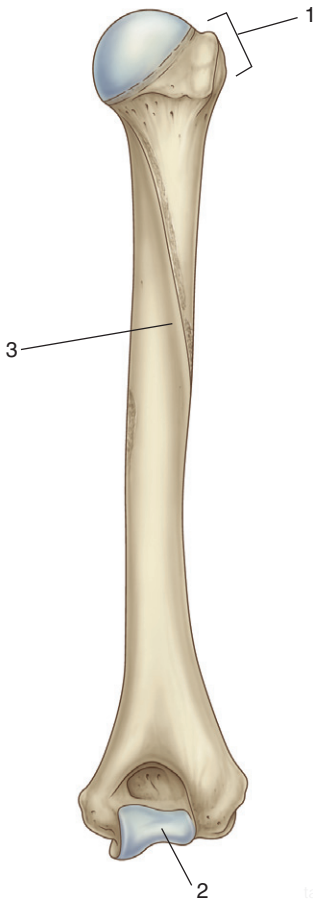
Figure from Gray's Anatomy for Students, 3rd edition, p. 748.



HUMERUS: POSTERIOR VIEW

212

*Is this humerus from the right or left side of the body?
Identify the indicated features.*



HUMERUS: POSTERIOR VIEW



It is from the right side of the body.

1. Greater tubercle
2. Trochlea
3. Radial groove

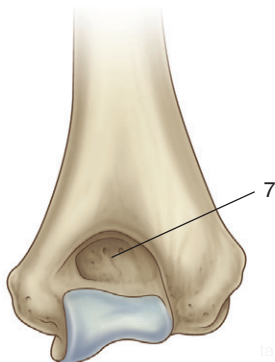
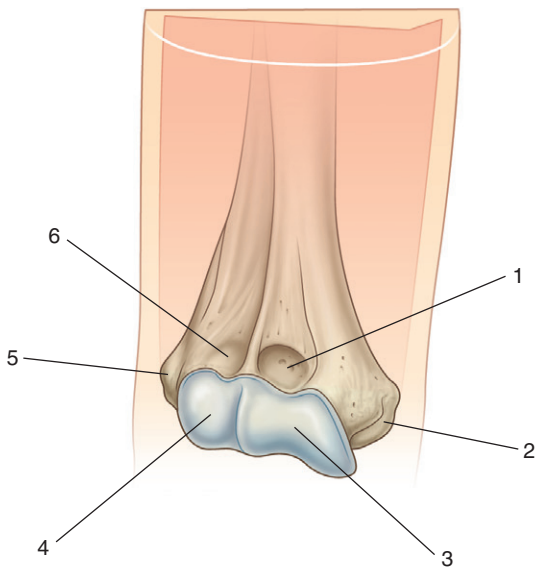
IN THE CLINIC:

- **The radial nerve lies in the radial groove on the posterior surface of the humerus. In this position, the nerve can be damaged when the shaft of the humerus is fractured.**

Figure from Gray's Anatomy for Students, 3rd edition, p. 751.



Identify the indicated features.



DISTAL HUMERUS



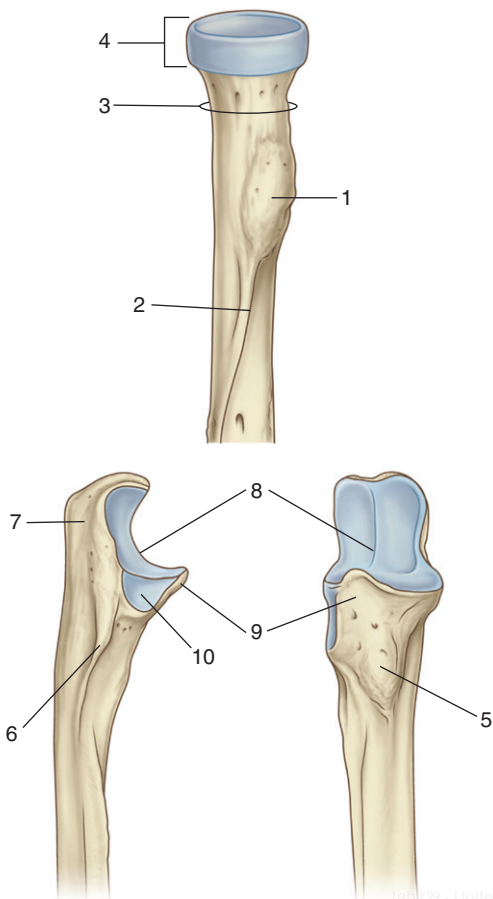
1. Coronoid fossa
2. Medial epicondyle
3. Trochlea
4. Capitulum
5. Lateral epicondyle
6. Radial fossa
7. Olecranon fossa

IN THE CLINIC:

- The lateral and medial epicondyles are palpable landmarks at the elbow. The ulnar nerve passes posterior to the medial epicondyle and can be “rolled” against the bone at this site. Impact of the nerve against the medial epicondyle leads to a “pins and needles” sensation on the medial side of the hand; hence the term *funny bone* often is applied to the medial epicondyle.

Figure from Gray's Anatomy for Students, 3rd edition, p. 751.

*Are these bones from the right or left side of the body?
Identify the bones. Identify the indicated features.*



PROXIMAL END OF RADIUS AND ULNA

These bones are from the right side of the body. The first (upper) bone is the radius, and the second (lower) two are views of the ulna.

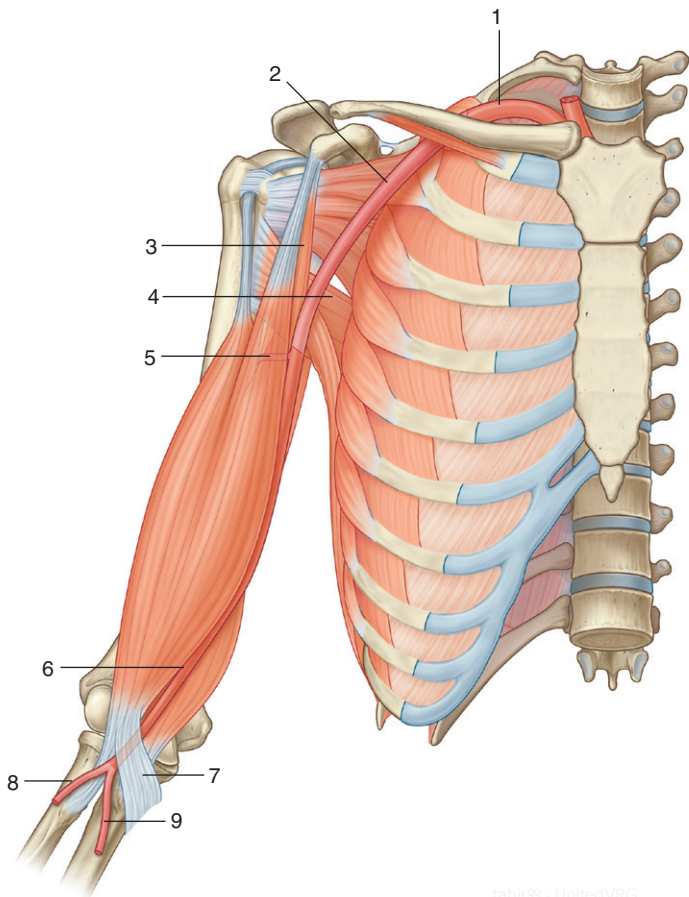
1. Radial tuberosity
2. Oblique line of radius
3. Neck of radius
4. Head of radius
5. Tuberosity of ulna
6. Supinator crest
7. Olecranon
8. Trochlear notch
9. Coronoid process
10. Radial notch

IN THE CLINIC:

- The neck of the radius is a weak point and is often fractured.

Figure from Gray's Anatomy for Students, 3rd edition, p. 753.

Identify the indicated arteries, muscles, and associated structures.



ARM ANTERIOR COMPARTMENT: BICEPS



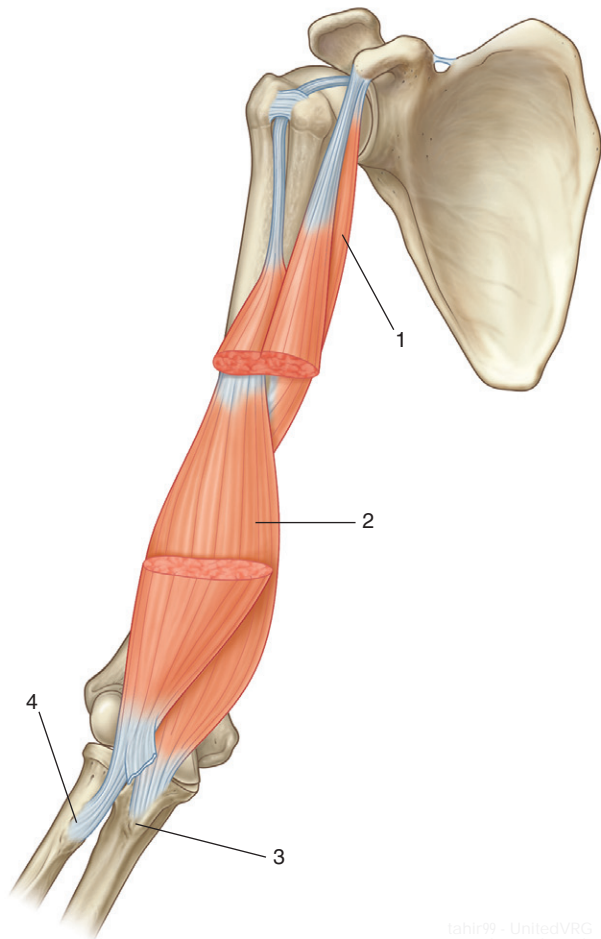
1. Subclavian artery
2. Axillary artery
3. Coracobrachialis muscle
4. Teres major muscle
5. Profunda brachii artery
6. Brachial artery
7. Bicipital aponeurosis
8. Radial artery
9. Ulnar artery

IN THE CLINIC:

- A “tap” on the tendon of the biceps brachii muscle at the elbow tests predominantly spinal cord segment C6.
- The biceps tendon is a palpable landmark at the elbow. Immediately medial to the inferior aspect of the muscle and to the tendon is the brachial artery. A stethoscope is placed over the brachial artery in the cubital fossa when taking a blood pressure reading.

Figure from Gray's Anatomy for Students, 3rd edition, p. 757.

Identify the indicated muscles and related features.



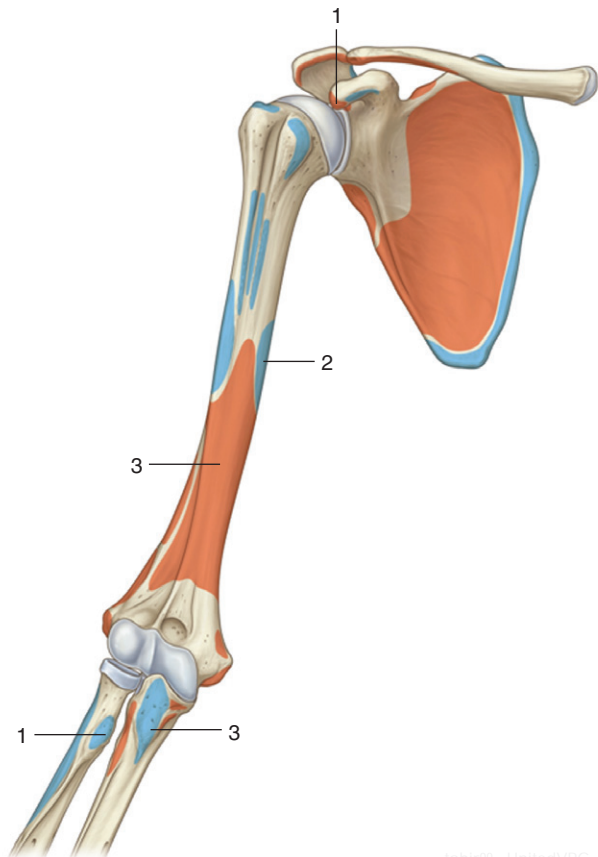
ARM ANTERIOR COMPARTMENT: MUSCLES



1. Coracobrachialis muscle
2. Brachialis muscle
3. Tuberosity of ulna
4. Radial tuberosity

Figure from Gray's Anatomy for Students, 3rd edition, p. 760.

*Identify the muscles that attach to the areas indicated.
What is the major function and innervation of
each muscle?*



ARM ANTERIOR COMPARTMENT: MUSCLE ATTACHMENTS

MUSCLES OF THE ANTERIOR COMPARTMENT OF THE ARM (SPINAL SEGMENTS IN BOLD ARE THE MAJOR SEGMENTS INNERVATING THE MUSCLE)

Muscle	Origin	Insertion	Innervation	Function
1. Biceps brachii	Long head—supraglenoid tubercle of scapula; short head—apex of coracoid process	Radial tuberosity	Musculocutaneous nerve (C5,C6)	Powerful flexor of the forearm at the elbow joint and supinator of the forearm; accessory flexor of the arm at the glenohumeral joint
2. Coracobrachialis	Apex of coracoid process	Linear roughening on mid-shaft of humerus on medial side	Musculocutaneous nerve (C5,C6,C7)	Flexor of the arm at the glenohumeral joint
3. Brachialis	Anterior aspect of humerus (medial and lateral surfaces) and adjacent intermuscular septae	Tuberosity of the ulna	Musculocutaneous nerve (C5,C6); (small contribution by the radial nerve [C7] to lateral part of muscle)	Powerful flexor of the forearm at the elbow joint

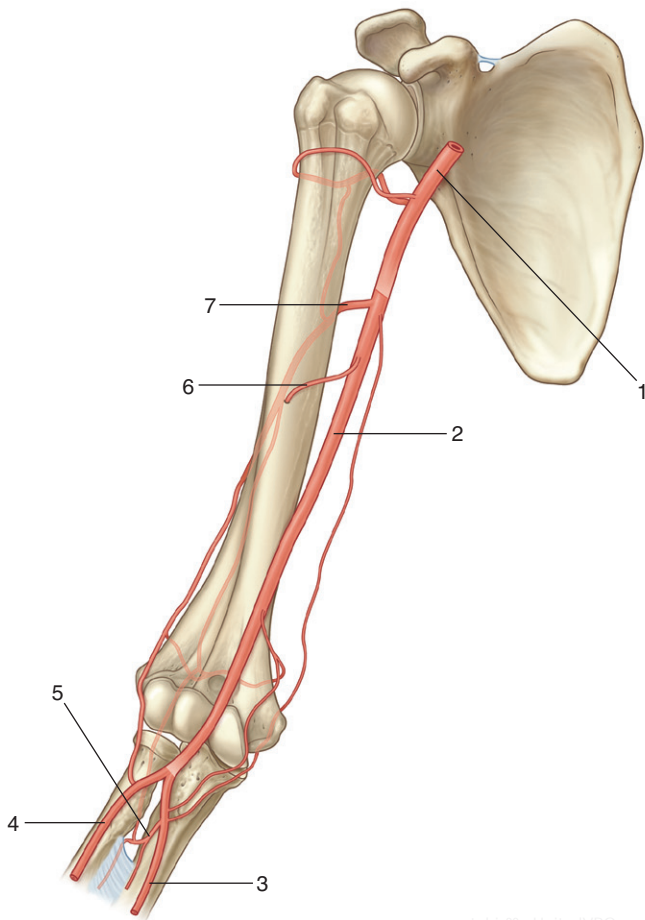
Figure from Gray's Atlas of Anatomy, 2nd edition, p. 407.



ARM ANTERIOR COMPARTMENT: ARTERIES

218

Identify the indicated arteries.



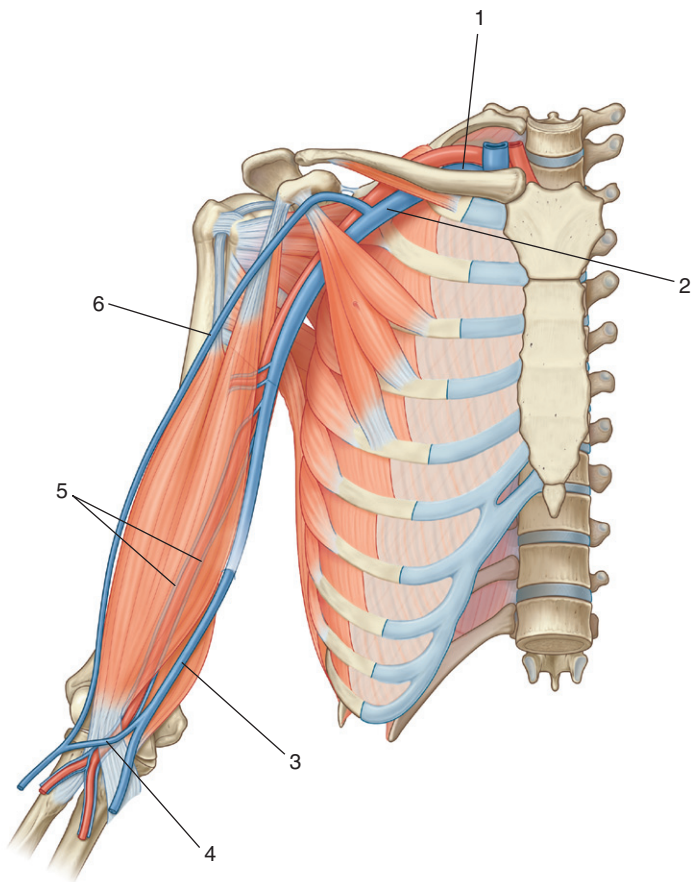
ARM ANTERIOR COMPARTMENT: ARTERIES



1. Axillary artery
2. Brachial artery
3. Ulnar artery
4. Radial artery
5. Common interosseous artery
6. Humeral nutrient artery
7. Profunda brachii artery

Figure from Gray's Anatomy for Students, 3rd edition, p. 758.

Identify the indicated veins.



ARM ANTERIOR COMPARTMENT: VEINS



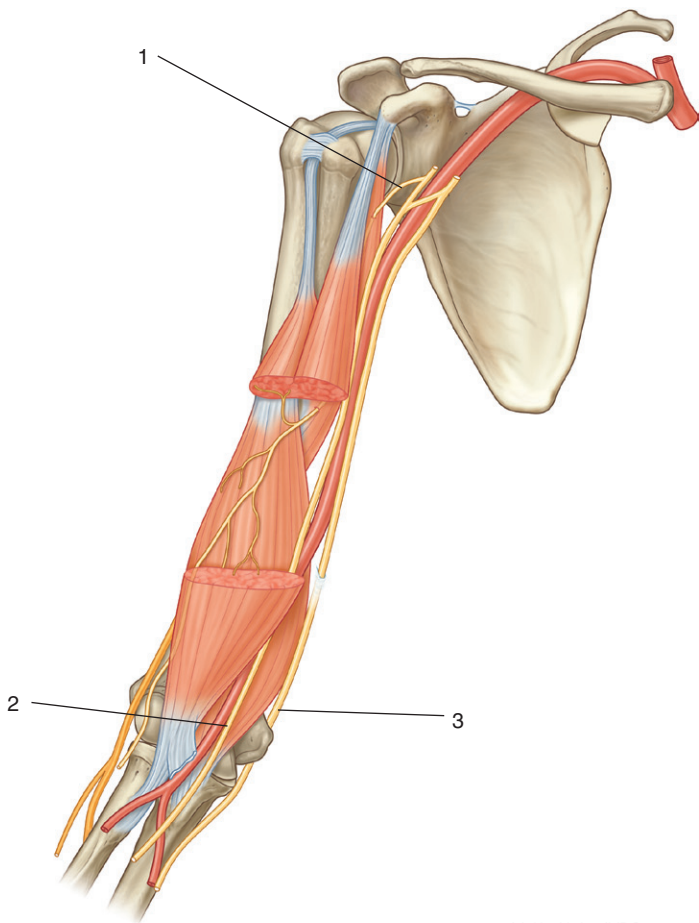
1. Subclavian vein
2. Axillary vein
3. Basilic vein
4. Median cubital vein
5. Paired brachial veins
6. Cephalic vein

IN THE CLINIC:

- **The median cubital vein is often used for taking blood samples.**

Figure from Gray's Anatomy for Students, 3rd edition, p. 759.

Identify the indicated nerves.



ARM ANTERIOR COMPARTMENT: NERVES



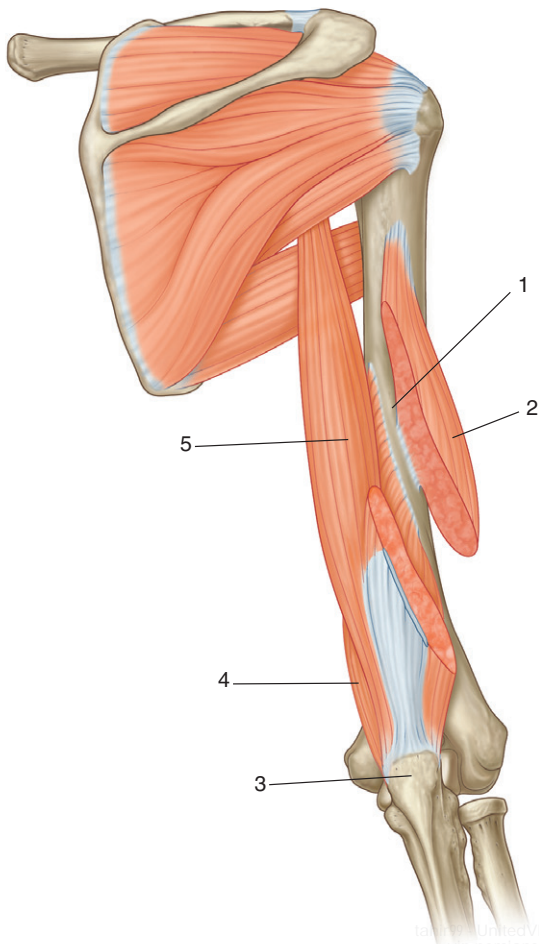
1. Musculocutaneous nerve
2. Median nerve
3. Ulnar nerve

IN THE CLINIC:

- **All muscles in the anterior compartment of the arm are supplied by the musculocutaneous nerve. The nerve ends as the lateral cutaneous nerve of the forearm.**
- **The musculocutaneous nerve originates from the lateral cord of the brachial plexus and contains nerve fibers from spinal cord segments C5, C6, and C7.**

Figure from Gray's Anatomy for Students, 3rd edition, p. 760.

Identify the indicated muscles and features.



ARM POSTERIOR COMPARTMENT: MUSCLES



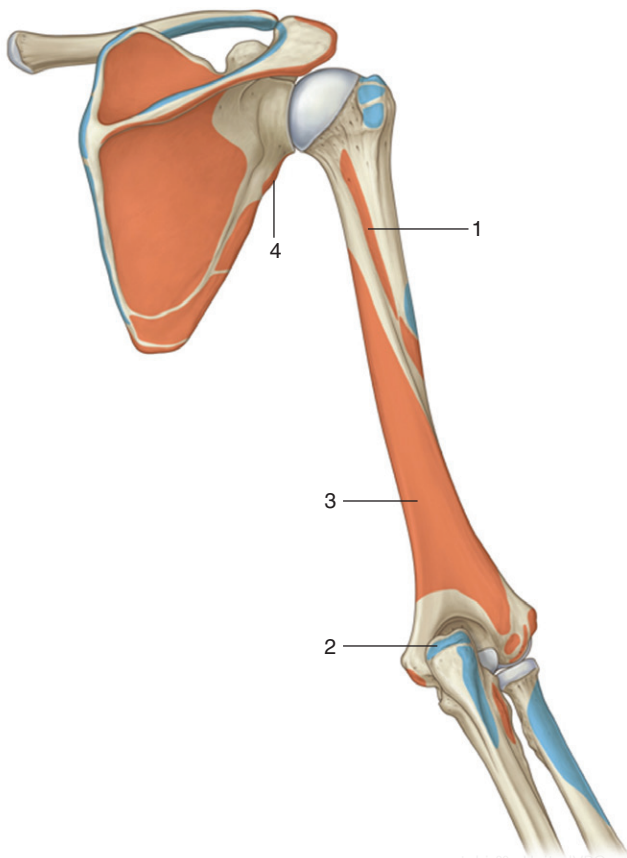
1. Radial groove
2. Lateral head of triceps brachii muscle
3. Olecranon
4. Medial head of triceps brachii muscle
5. Long head of triceps brachii muscle

IN THE CLINIC:

- A “tap” on the tendon of the triceps brachii muscle tests mainly spinal cord segment C7.

Figure from Gray's Anatomy for Students, 3rd edition, p. 755.

*Identify the muscles that attach to the areas indicated.
What is the major function and innervation of
each muscle?*



ARM POSTERIOR COMPARTMENT: MUSCLE ATTACHMENTS

MUSCLE OF THE POSTERIOR COMPARTMENT OF THE ARM (SPINAL SEGMENTS INDICATED IN BOLD ARE THE MAJOR SEGMENTS INNERVATING THE MUSCLE)

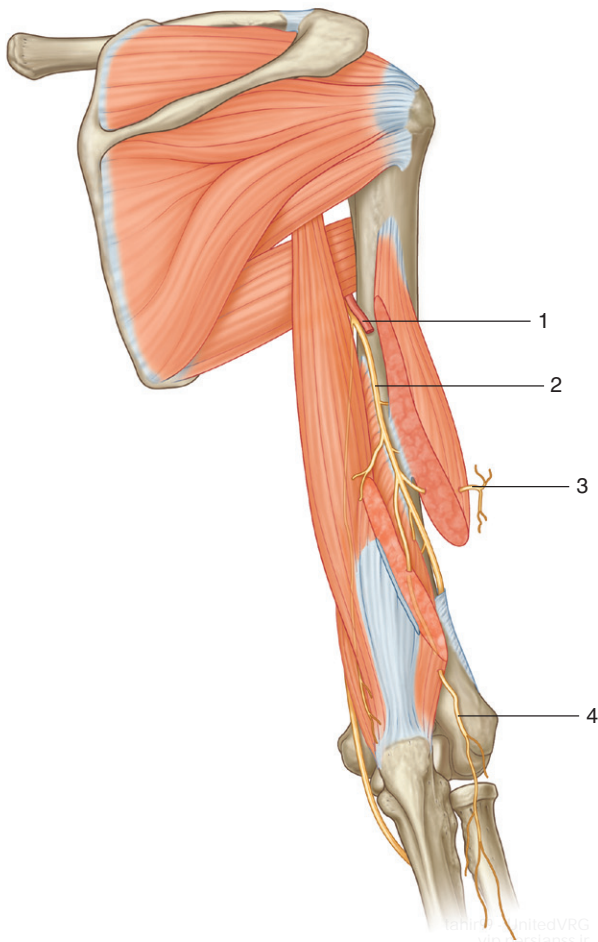
Muscle	Origin	Insertion	Innervation	Function
2. Triceps brachii	1. Lateral head: posterior surface of humerus 3. Medial head: posterior surface of humerus 4. Long head: infraglenoid tubercle of scapula	Olecranon	Radial nerve (C6, C7 ,C8)	Extension of the forearm at the elbow joint. Long head can also extend and adduct the arm at the shoulder joint

Figure from Gray's Atlas of Anatomy, 2nd edition, p. 407.

ARM POSTERIOR COMPARTMENT: NERVES AND VESSELS

223

Identify the indicated nerves and arteries.



ARM POSTERIOR COMPARTMENT: NERVES AND VESSELS



1. Profunda brachii artery
2. Radial nerve
3. Inferior lateral cutaneous nerve of arm
4. Posterior cutaneous nerve of forearm

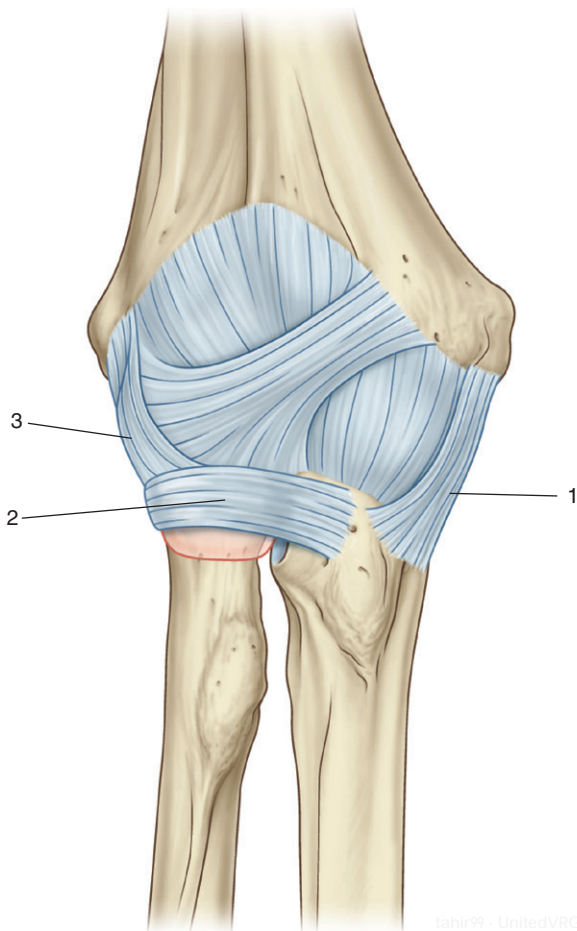
IN THE CLINIC:

- The radial nerve and profunda brachii artery lie in the radial groove on the posterior surface of the humerus. Fractures to the shaft of the humerus can damage the radial nerve and the associated artery. A lesion to the radial nerve in the radial groove leads to wristdrop and loss of sensation on the dorsolateral surface of the hand.

Figure from Gray's Anatomy for Students, 3rd edition, p. 762



Identify the indicated ligaments.



ELBOW JOINT



1. Ulnar collateral ligament
2. Annular ligament
3. Radial collateral ligament

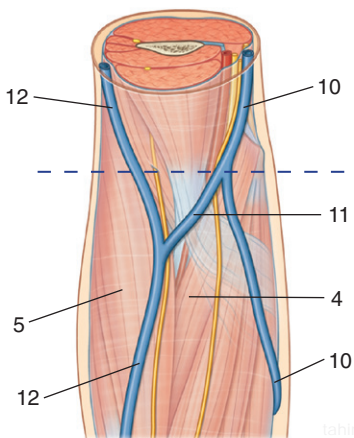
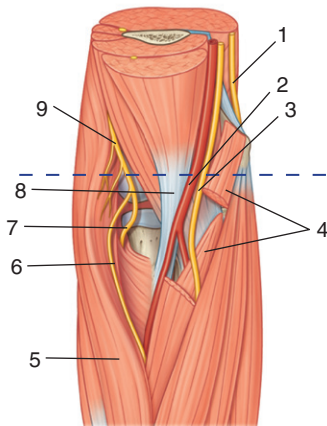
IN THE CLINIC:

- In children, a sharp “pull” on the forearm can dislocate the head of the radius from the annular ligament.
- The neck of the radius is a common site of fracture. Damage to the associated joint capsule and repair of the fracture can lead to a “tightening” of the capsule and a reduced range of movement of the elbow joint after recovery.

Figure from Gray's Anatomy for Students, 3rd edition, p. 765



Identify the indicated structures.



CUBITAL FOSSA



1. Ulnar nerve
2. Brachial artery
3. Median nerve
4. Pronator teres muscle
5. Brachioradialis muscle
6. Superficial branch of radial nerve
7. Deep branch of radial nerve
8. Tendon of biceps brachii muscle
9. Radial nerve
10. Basilic vein
11. Median cubital vein
12. Cephalic vein

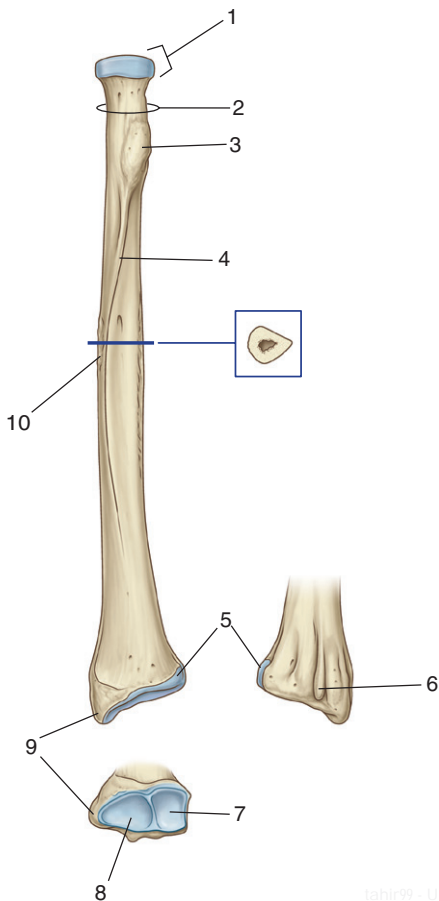
IN THE CLINIC:

- **The pulse of the brachial artery can be felt immediately medial to the tendon of biceps brachii muscle in the cubital fossa. This also is where a stethoscope is placed when taking a blood pressure measurement.**
- **Blood is often extracted from the median cubital vein. The vein is separated from the brachial artery and median nerve by the bicipital aponeurosis.**
- **The ulnar nerve is accessible to trauma as it passes posterior to the medial epicondyle.**
- **The radial nerve is covered by the medial edge of the brachioradialis muscle that forms the lateral boundary of the cubital fossa.**

Figure from Gray's Anatomy for Students, 3rd edition, p. 769.



*Is this radius from the right or left side of the body?
Identify the indicated features.*



RADIUS



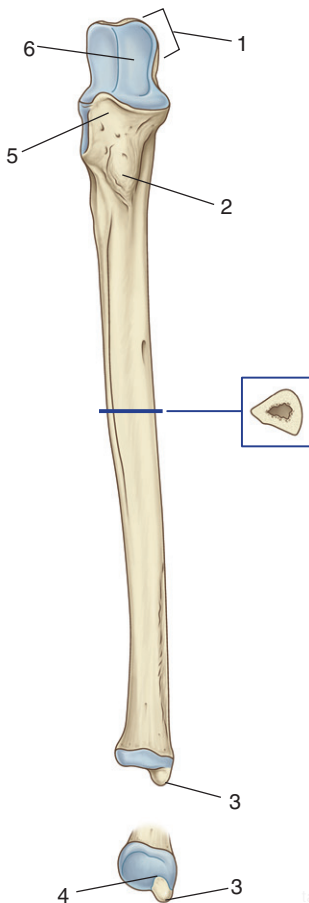
This bone is from the right side of the body.

1. Radial head
2. Radial neck
3. Radial tuberosity
4. Oblique line
5. Ulnar notch
6. Dorsal tubercle
7. Facet for articulation with lunate bone
8. Facet for articulation with scaphoid bone
9. Radial styloid process
10. Roughening for attachment of pronator teres

Figure from Gray's Anatomy for Students, 3rd edition, p. 772.



*Is this ulna from the right or the left side of the body?
Identify the indicated features.*



ULNA



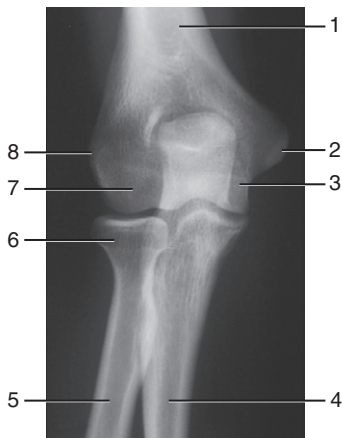
This bone is from the right side of the body.

1. Olecranon
2. Tuberosity of ulna
3. Ulnar styloid process
4. Attachment of articular disc
5. Coronoid process
6. Trochlear notch

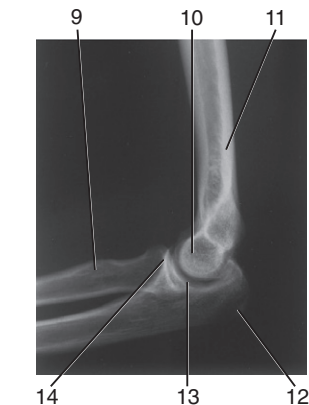Figure from Gray's Anatomy for Students, 3rd edition, p. 773.



Identify the indicated structures.



A



B

RADIOGRAPHS: ELBOW JOINT

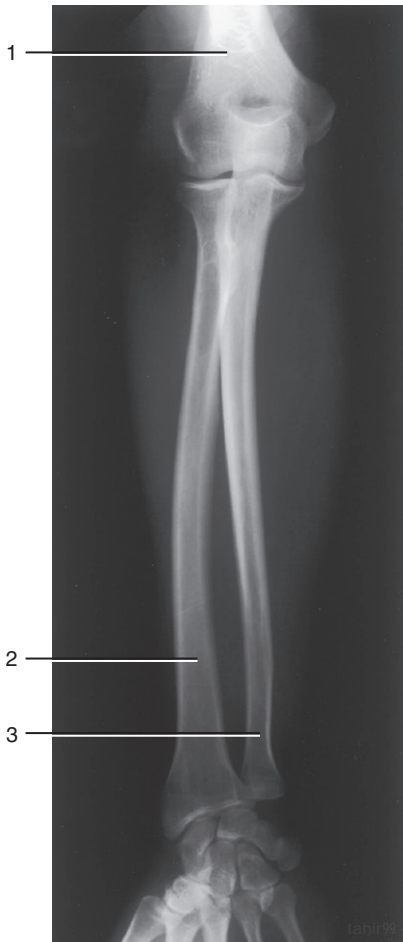

1. Humerus
2. Medial epicondyle
3. Trochlea
4. Ulna
5. Radius
6. Head of radius
7. Capitulum
8. Lateral epicondyle
9. Radial tuberosity
10. Capitulum
11. Humerus
12. Olecranon
13. Trochlear notch
14. Coronoid process

Figure from Gray's Basic Anatomy, p. 379.



Identify the indicated structures.



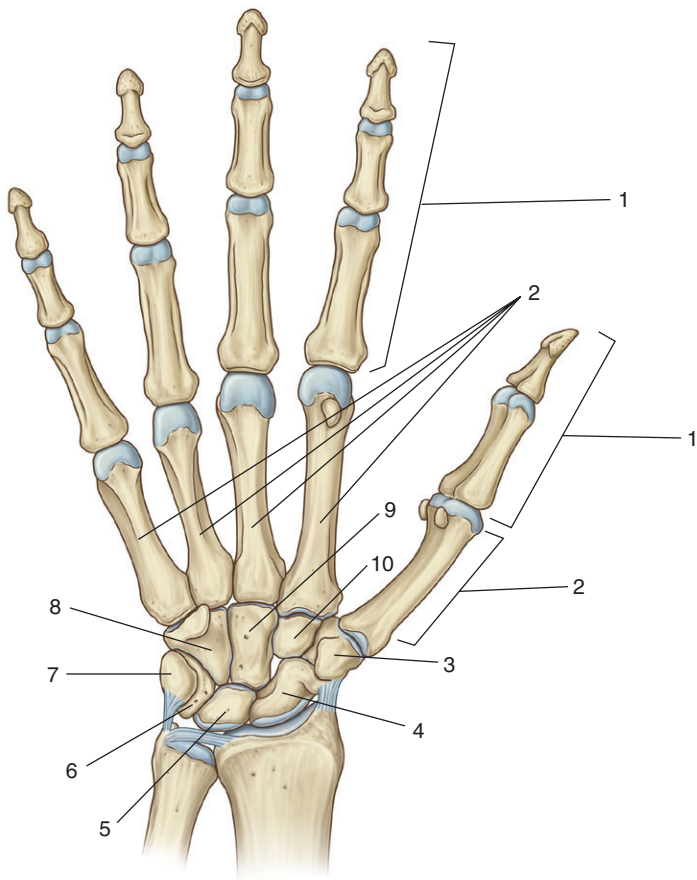
RADIOGRAPH: FOREARM



1. Humerus
2. Radius
3. Ulna

Figure from Gray's Basic Anatomy, p. 382.

Identify the indicated bones.



WRIST AND BONES OF HAND



1. Phalanges
2. Metacarpals
3. Trapezium
4. Scaphoid
5. Lunate
6. Triquetrum
7. Pisiform
8. Hamate
9. Capitate
10. Trapezoid

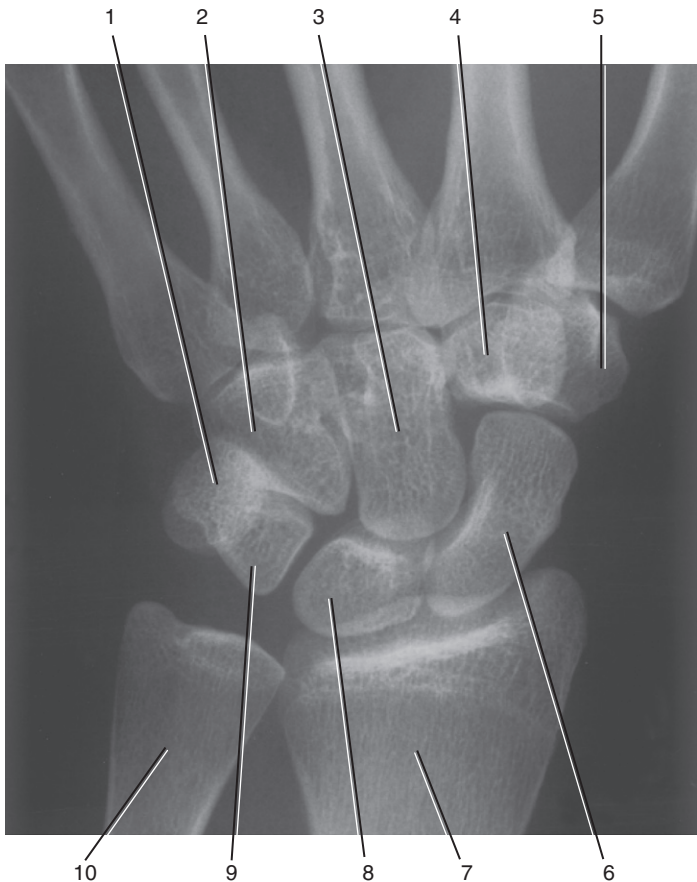IN THE CLINIC:

- **The most common carpal injury is a fracture across the waist of the scaphoid bone. In some individuals, this results in necrosis of the proximal part of the bone because blood supply to this region is via a branch from the radial artery that enters through the distal part of the bone.**

Figure from Gray's Anatomy for Students, 3rd edition, p. 794.



Identify the indicated structures.



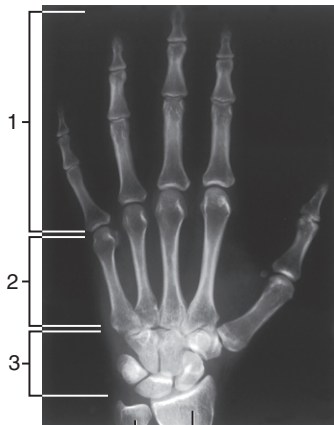RADIOGRAPH: WRIST



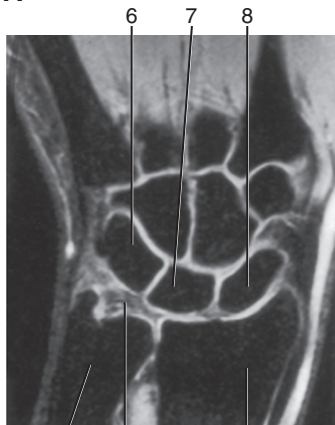
1. Pisiform
2. Hamate
3. Capitate
4. Trapezoid
5. Trapezium
6. Scaphoid
7. Radius
8. Lunate
9. Triquetrum
10. Ulna

Figure from Gray's Basic Anatomy, p. 398.

Identify the indicated structures.



A



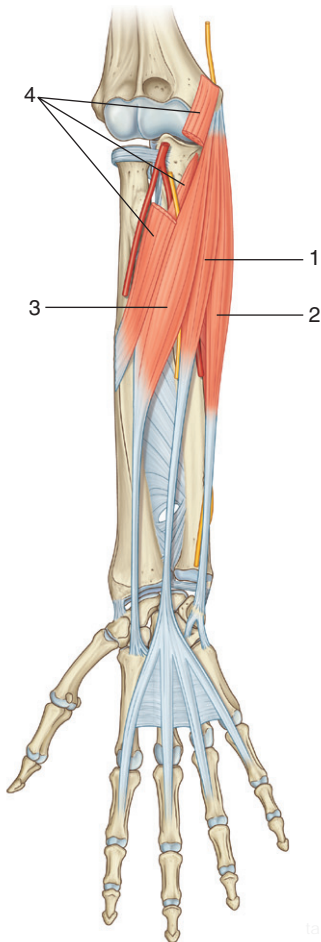
B

RADIOGRAPHS: HAND AND WRIST JOINT

1. Phalanges
2. Metacarpals
3. Carpal bones
4. Ulna
5. Radius
6. Triquetrum
7. Lunate
8. Scaphoid
9. Radius
10. Articular disc
11. Ulna

Figure from Gray's Basic Anatomy, p. 396.

Identify the indicated muscles.



FOREARM ANTERIOR COMPARTMENT: MUSCLES, FIRST LAYER



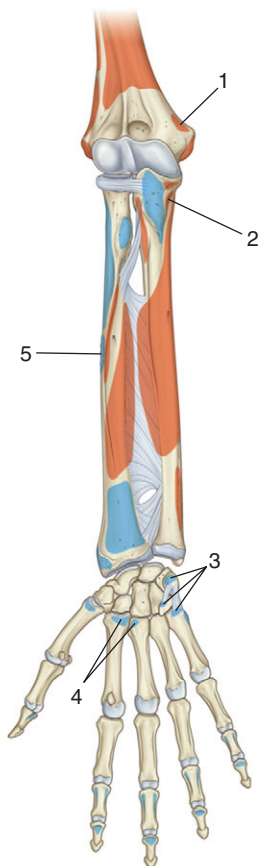
1. Palmaris longus muscle
2. Flexor carpi ulnaris muscle
3. Flexor carpi radialis muscle
4. Pronator teres muscle

IN THE CLINIC:

- The palmaris longus muscle is absent in about 15% of the population.
- The flexor carpi ulnaris muscle is innervated by the ulnar nerve. The three other muscles of the superficial layer of flexor muscles are innervated by the median nerve.

Figure from Gray's Anatomy for Students, 3rd edition, p. 778.

*Identify the muscles that attach to the areas indicated.
What is the major function and innervation of
each muscle?*



FOREARM ANTERIOR COMPARTMENT: MUSCLE ATTACHMENTS, SUPERFICIAL LAYER

SUPERFICIAL LAYER OF MUSCLES IN THE ANTERIOR COMPARTMENT OF THE FOREARM (SPINAL SEGMENTS INDICATED IN BOLD ARE THE MAJOR SEGMENTS INNERVATING THE MUSCLE)

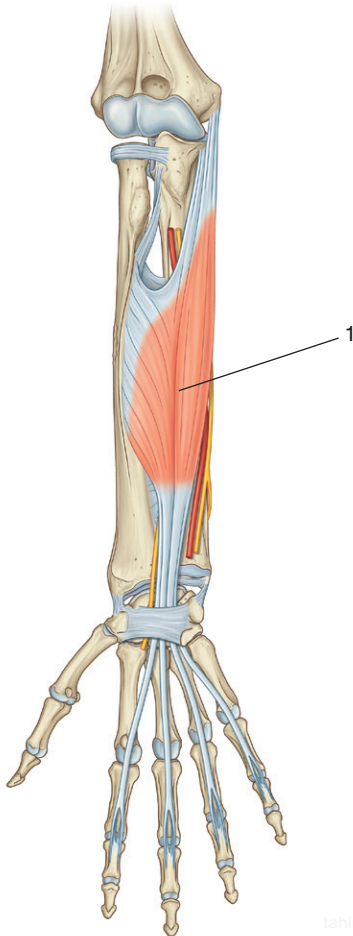
Muscle	Origin	Insertion	Innervation	Function
1-2 and 5. Pronator terres	Humeral head—medial epicondyle and adjacent supra-epicondylar ridge; ulnar head—medial side of coronoid process	Roughening on lateral surface, mid-shaft, of radius	Median nerve (C6,C7)	Pronation
3. Flexor carpi ulnaris	Humeral head—medial epicondyle of humerus; ulnar head—olecranon and posterior border of ulna	Pisiform bone, and then via pisohamate and pisometacarpal ligaments into the hamate and base of metacarpal V	Ulnar nerve (C7,C8, T1)	Flexes and adducts the wrist joint
4. Flexor carpi radialis	Medial epicondyle of humerus	Base of metacarpals II and III	Median nerve (C6,C7)	Flexes and abducts the wrist

Figure from Gray's Atlas of Anatomy, 2nd edition, p. 430.

**FOREARM ANTERIOR COMPARTMENT:
MUSCLES, SECOND LAYER**

235

Identify the indicated muscle.



FOREARM ANTERIOR COMPARTMENT: MUSCLES, SECOND LAYER



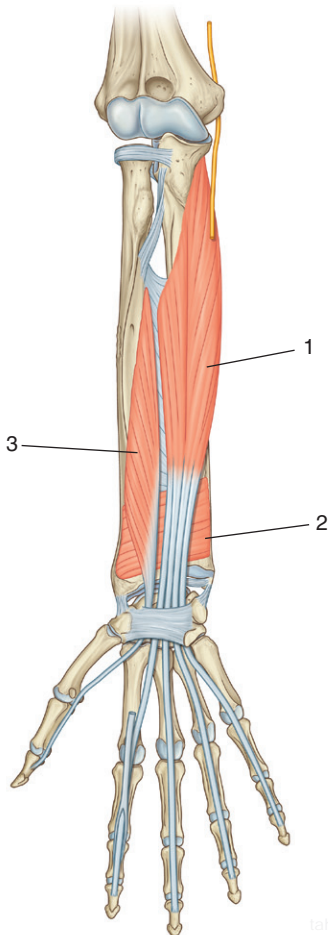
1. Flexor digitorum superficialis muscle

Figure from Gray's Anatomy for Students, 3rd edition, p.780.

FOREARM ANTERIOR COMPARTMENT: MUSCLES, THIRD LAYER

236

Identify the indicated muscles.





FOREARM ANTERIOR COMPARTMENT: MUSCLES, THIRD LAYER



1. Flexor digitorum profundus muscle
2. Pronator quadratus muscle
3. Flexor pollicis longus muscle

IN THE CLINIC:

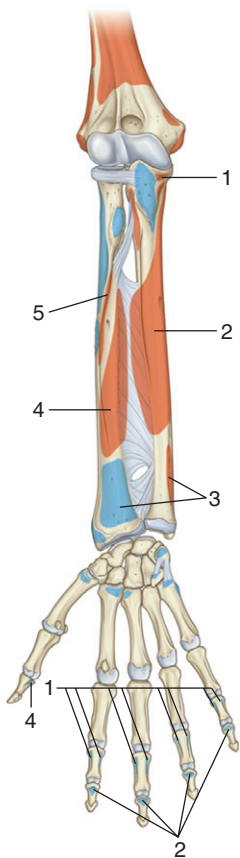
- **Loss of function of the flexor digitorum profundus muscle results in loss of the ability to flex the distal interphalangeal joints of digits two to five.**

Figure from Gray's Anatomy for Students, 3rd edition, p. 780.

**FOREARM ANTERIOR COMPARTMENT:
MUSCLE ATTACHMENTS, INTERMEDIATE
AND DEEP LAYERS**

237

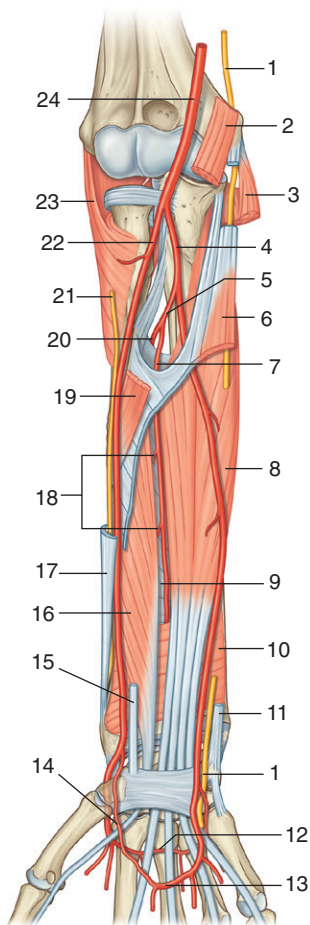
*Identify the muscles that attach to the areas indicated.
What is the major function and innervation of
each muscle?*



Muscle	Origin	Insertion	Innervation	Function
1 and 5. Flexor digitorum superficialis	1. Humero-ulnar head: medial epicondyle of humerus and adjacent margin of coronoid process 5. Radial head: oblique line of radius	Four tendons, which attach to the palmar surfaces of the middle phalanges of the index, middle, ring, and little fingers	Median nerve (C8,T1)	Flexes proximal interphalangeal joints of the index, middle, ring, and little fingers; can also flex metacarpophalangeal joints of the same fingers and the wrist joint
2. Flexor digitorum profundus	Anterior and medial surfaces of ulna and anterior medial half of interosseous membrane	Four tendons, which attach to the palmar surfaces of the distal phalanges of the index, middle, ring, and little fingers	Lateral half by median nerve (anterior interosseous nerve); medial half by ulnar nerve (C8,T1)	Flexes distal interphalangeal joints of the index, middle, ring, and little fingers; can also flex metacarpophalangeal joints of the same fingers and the wrist joint
3. Pronator quadratus	Linear ridge on distal anterior surface of ulna	Distal anterior surface of radius	Median nerve (anterior interosseous nerve) (C7,C8)	Pronation
4. Flexor pollicis longus	Anterior surface of radius and radial half of interosseous membrane	Palmar surface of base of distal phalanx of thumb	Median nerve (anterior interosseous nerve) (C7,C8)	Flexes interphalangeal joint of the thumb; can also flex metacarpophalangeal joint of the thumb

Figure from Gray's Atlas of Anatomy, 2nd edition, p. 430.

Identify the indicated structures.



FOREARM ANTERIOR COMPARTMENT: ARTERIES



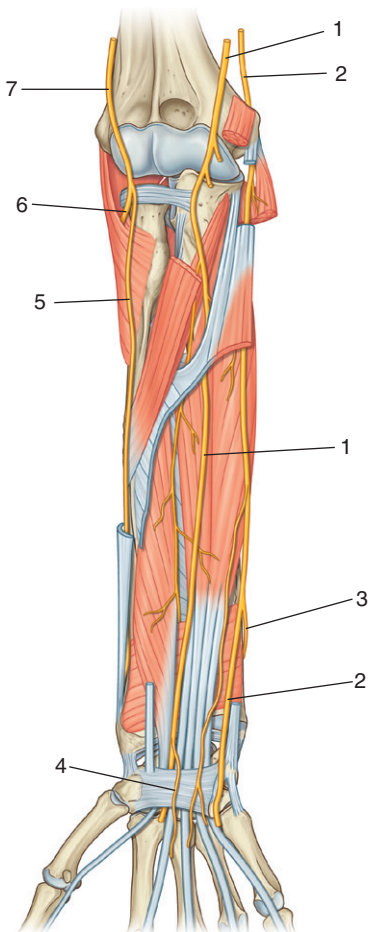
1. Ulnar nerve
2. Humeral head of pronator teres muscle
3. Flexor carpi ulnaris muscle (cut)
4. Ulnar artery
5. Common interosseous artery muscle
6. Flexor digitorum superficialis muscle (cut)
7. Anterior interosseous artery
8. Flexor digitorum profundus muscle
9. Interosseous membrane
10. Pronator quadratus muscle
11. Flexor carpi ulnaris tendon (cut)
12. Deep palmar arch
13. Superficial palmar arch
14. Superficial palmar branch of radial artery
15. Flexor carpi radialis tendon (cut)
16. Flexor pollicis longus muscle
17. Brachioradialis tendon (cut)
18. Perforating branches of anterior interosseous artery
19. Pronator teres muscle (cut)
20. Posterior interosseous artery
21. Superficial branch of radial nerve
22. Radial artery
23. Supinator muscle
24. Brachial artery

IN THE CLINIC:

- The pulse of the radial artery in the distal forearm can be felt immediately lateral to the tendon of the flexor carpi radialis.
- The pulse of the ulnar artery in the distal forearm is more difficult to palpate because it is under the lateral lip of the flexor carpi ulnaris muscle.

Figure from Gray's Anatomy for Students, 3rd edition, p. 782.

Identify the indicated nerves.



FOREARM ANTERIOR COMPARTMENT: NERVES



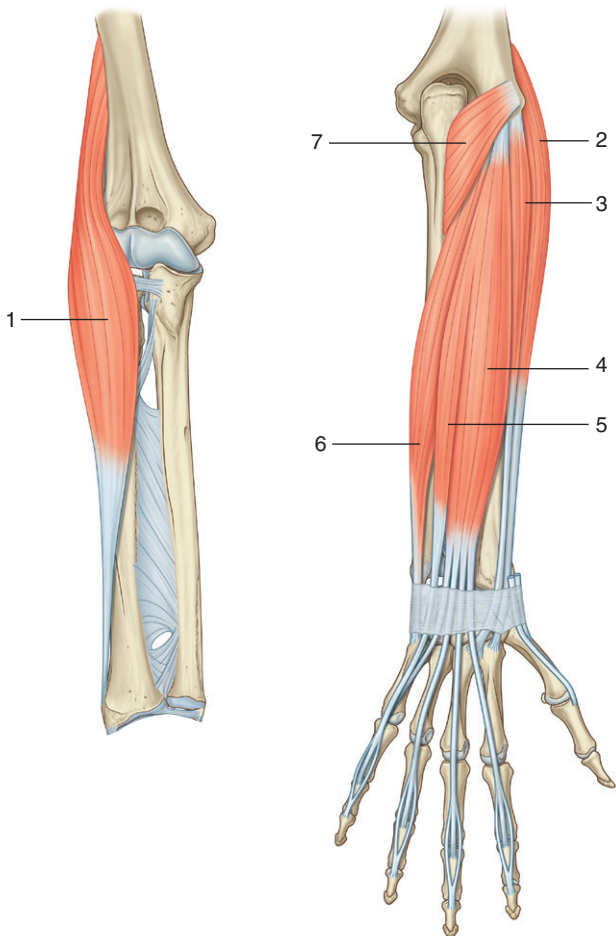
1. Median nerve
2. Ulnar nerve
3. Dorsal branch of ulnar nerve
4. Palmar branch of median nerve
5. Superficial branch of radial nerve
6. Deep branch of radial nerve
7. Radial nerve

IN THE CLINIC:

- All muscles in the anterior compartment of the forearm are innervated by the median nerve except for the flexor carpi ulnaris muscle and the medial half of the flexor digitorum profundus muscle.
- Carpal tunnel syndrome results from compression of the median nerve in the carpal tunnel. In this syndrome, the palmar branch is spared. If the function of the palmar branch is compromised, then the lesion to the median nerve is proximal to the wrist.

Figure from Gray's Anatomy for Students, 3rd edition, p. 784.

Identify the indicated muscles.





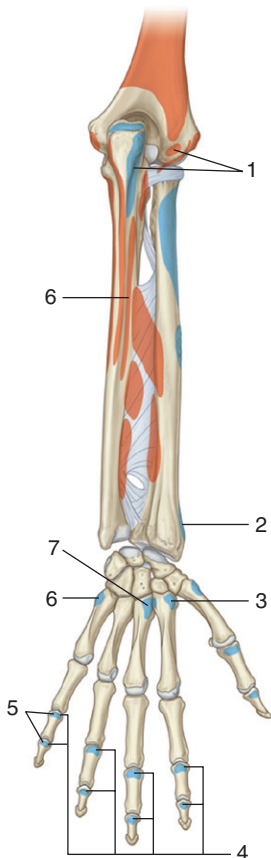
FOREARM POSTERIOR COMPARTMENT: MUSCLES, SUPERFICIAL LAYER



1. Brachioradialis muscle
2. Extensor carpi radialis longus muscle
3. Extensor carpi radialis brevis muscle
4. Extensor digitorum muscle
5. Extensor digiti minimi muscle
6. Extensor carpi ulnaris muscle
7. Anconeus muscle

Figure from Gray's Anatomy for Students, 3rd edition, p.7866.

*Identify the muscles that attach to the areas indicated.
What is the major function and innervation of
each muscle?*

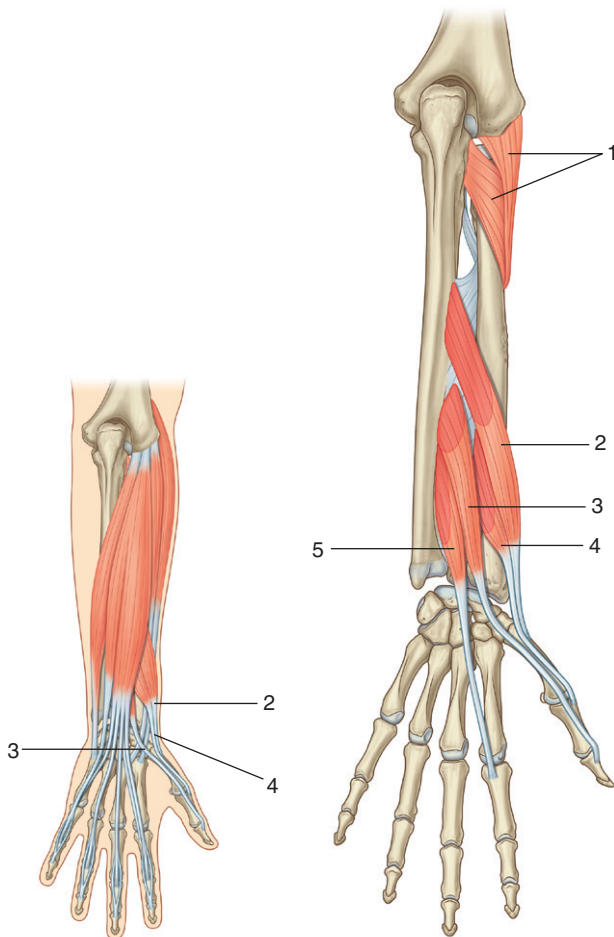


SUPERFICIAL LAYER OF MUSCLES IN THE POSTERIOR COMPARTMENT OF THE FOREARM (SPINAL SEGMENTS INDICATED IN BOLD ARE THE MAJOR SEGMENTS INNERVATING THE MUSCLE)

Muscle	Origin	Insertion	Innervation	Function
1. Anconeus	Lateral epicondyle of humerus	Olecranon and proximal posterior surface of ulna	Radial nerve (C6 to C8) (via branch to medial head of triceps brachii)	Abduction of the ulna in pronation; accessory extensor of the elbow joint
2. Brachioradialis	Proximal part of lateral supra-epicondylar ridge of humerus and adjacent intermuscular septum	Lateral surface of distal end of radius	Radial nerve (C5, C6) before division into superficial and deep branches	Accessory flexor of elbow joint when forearm is midpronated
3. Extensor carpi radialis longus	Distal part of lateral supra-epicondylar ridge of humerus and adjacent intermuscular septum	Dorsal surface of base of metacarpal II	Radial nerve (C6, C7) before division into superficial and deep branches	Extends and abducts the wrist
4. Extensor digitorum	Lateral epicondyle of humerus and adjacent intermuscular septum and deep fascia	Four tendons, which insert via "extensor hoods" into the dorsal aspects of the bases of the middle and distal phalanges of the index, middle, ring, and little fingers	Posterior interosseous nerve (C7, C8)	Extends the index, middle, ring, and little fingers; can also extend the wrist
5. Extensor digiti minimi	Lateral epicondyle of humerus and adjacent intermuscular septum together with extensor digitorum	Extensor hood of the little finger	Posterior interosseous nerve (C7, C8)	Extends the little finger
6. Extensor carpi ulnaris	Lateral epicondyle of humerus and posterior border of ulna	Tubercle on the base of the medial side of metacarpal V	Posterior interosseous nerve (C7, C8)	Extends and adducts the wrist
7. Extensor carpi radialis brevis	Lateral epicondyle of humerus and adjacent intermuscular septum	Dorsal surface of base of metacarpals II and III	Deep branch of radial nerve (C7, C8) before penetrating supinator muscle	Extends and abducts the wrist

Figure from Gray's Atlas of Anatomy, 2nd edition, p. 430.

Identify the indicated muscles.





FOREARM POSTERIOR COMPARTMENT: OUTCROPPING MUSCLES



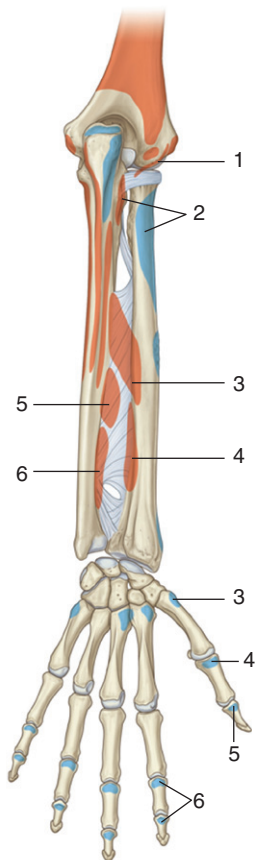
1. Supinator muscle
2. Abductor pollicis longus muscle
3. Extensor pollicis longus muscle
4. Extensor pollicis brevis muscle
5. Extensor indicis muscle

IN THE CLINIC:

- **The tendons of the abductor pollicis longus, extensor pollicis brevis, and extensor pollicis longus demarcate the anatomical snuffbox.**

Figure from Gray's Anatomy for Students, 3rd edition, p. 789.

*Identify the muscles that attach to the areas indicated.
What is the major function and innervation of
each muscle?*



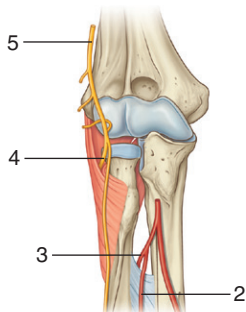
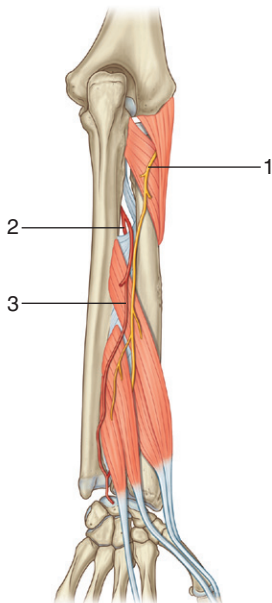
FOREARM POSTERIOR COMPARTMENT: MUSCLE ATTACHMENTS, DEEP LAYER

DEEP LAYER OF MUSCLES IN THE POSTERIOR COMPARTMENT OF THE FOREARM (SPINAL SEGMENTS INDICATED IN BOLD> ARE THE MAJOR SEGMENTS INNERVATING THE MUSCLE)

Muscle	Origin	Insertion	Innervation	Function
1 and 2. Supinator	1. Superficial part: lateral epicondyle of humerus, radial collateral and annular ligaments 2. Deep part: supinator crest of the ulna	Lateral surface of radius superior to the anterior oblique line	Posterior interosseous nerve (C6,C7)	Supination
3. Abductor pollicis longus	Posterior surfaces of ulna and radius (distal to the attachments of supinator and anconeus), and intervening interosseous membrane	Lateral side of base of metacarpal I	Posterior interosseous nerve (C7,C8)	Abducts carpometaacarpal joint of thumb; accessory extensor of the thumb
4. Extensor pollicis brevis	Posterior surface of radius (distal to abductor pollicis longus) and the adjacent interosseous membrane	Dorsal surface of base of proximal phalanx of the thumb	Posterior interosseous nerve (C7,C8)	Extends metacarpophalangeal joint of the thumb; can also extend the carpometaacarpal joint of the thumb
5. Extensor pollicis longus	Posterior surface of ulna (distal to the abductor pollicis longus) and the adjacent interosseous membrane	Dorsal surface of base of distal phalanx of thumb	Posterior interosseous nerve (C7,C8)	Extends interphalangeal joint of the thumb; can also extend carpometaacarpal and metacarpophalangeal joints of the thumb
6. Extensor indicis	Posterior surface of ulna (distal to extensor pollicis longus) and adjacent interosseous membrane	Extensor hood of index finger	Posterior interosseous nerve (C7,C8)	Extends index finger

Figure from Gray's Atlas of Anatomy, 2nd edition, p. 430.

Identify the indicated nerves and arteries.



FOREARM POSTERIOR COMPARTMENT: NERVES AND ARTERIES



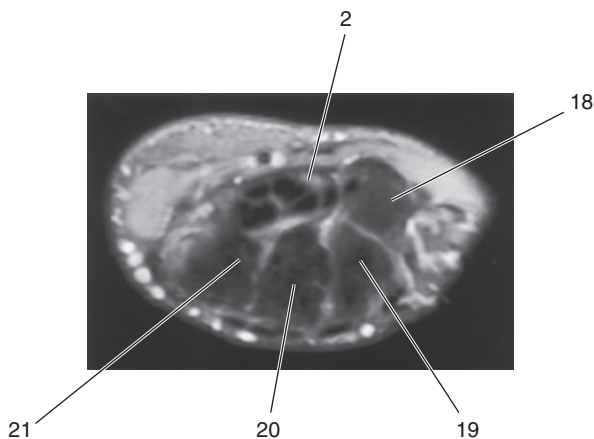
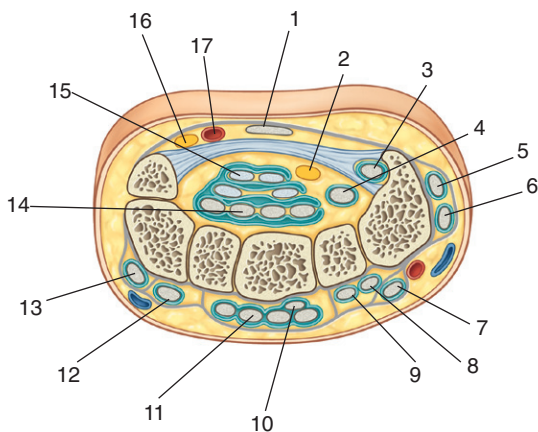
1. Posterior interosseous nerve
2. Anterior interosseous artery
3. Posterior interosseous artery
4. Deep branch of radial nerve
5. Radial nerve

IN THE CLINIC:

- **A lesion to the radial nerve in the radial groove of the humerus results in wristdrop.**

Figure from Gray's Anatomy for Students, 3rd edition, p. 791.

Identify the indicated tendons, vessels, nerves, and carpal bones.



HAND: CROSS SECTION THROUGH WRIST

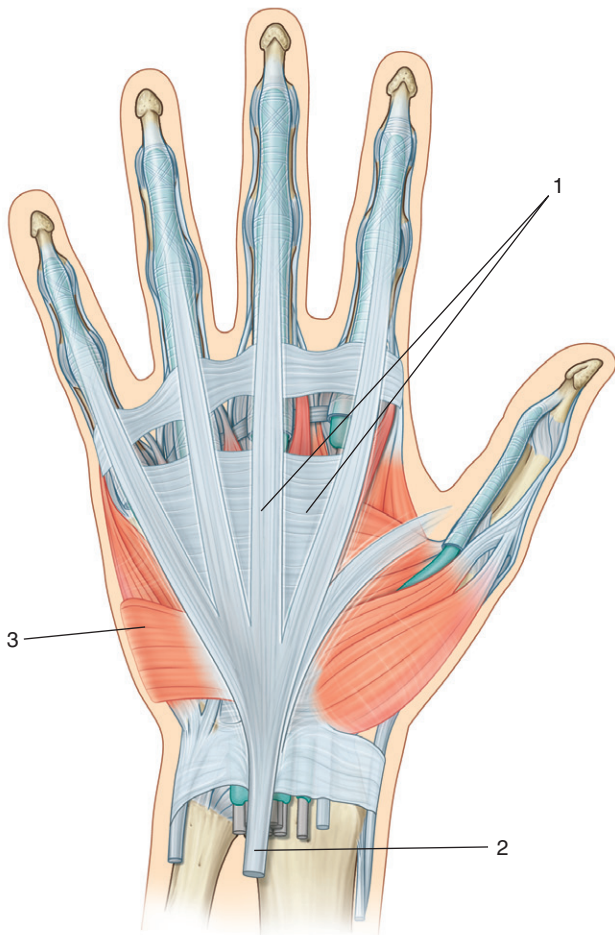
1. Palmaris longus
2. Median nerve
3. Flexor carpi radialis
4. Flexor pollicis longus
5. Abductor pollicis longus
6. Extensor pollicis brevis
7. Extensor pollicis longus
8. Extensor carpi radialis longus
9. Extensor carpi radialis brevis
10. Extensor indicis
11. Extensor digitorum
12. Extensor digiti minimi
13. Extensor carpi ulnaris
14. Flexor digitorum profundus
15. Flexor digitorum superficialis
16. Ulnar nerve
17. Ulnar artery
18. Trapezium
19. Trapezoid
20. Capitate
21. Hamate

IN THE CLINIC:

- **Nine tendons and the median nerve pass through the carpal tunnel. Compression of the median nerve in the carpal tunnel leads to carpal tunnel syndrome.**

Figure from Gray's Anatomy for Students, 3rd edition, p. 799.

Identify the indicated structures.



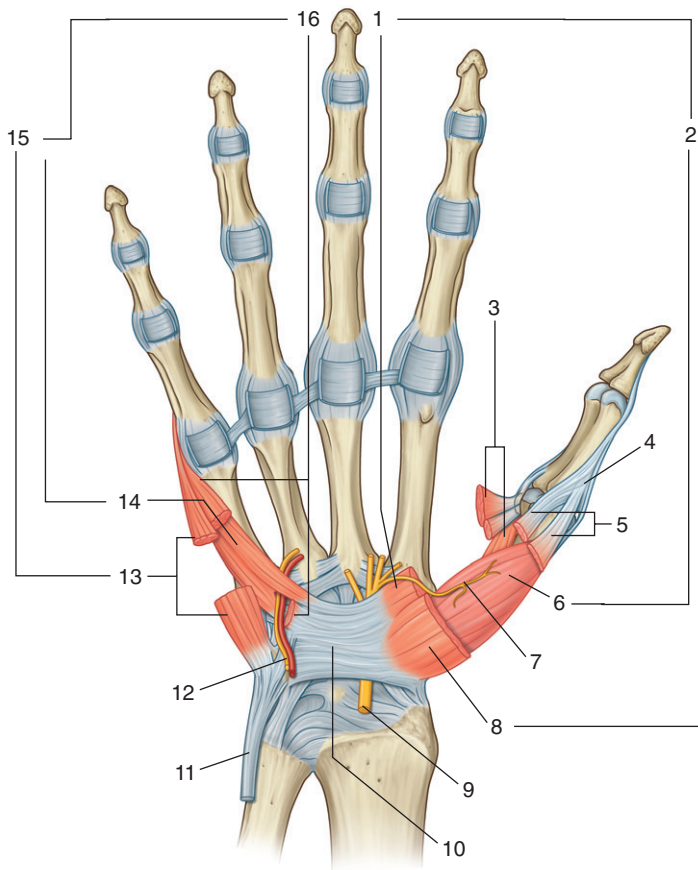
HAND: SUPERFICIAL PALM



1. Palmar aponeurosis
2. Palmaris longus tendon
3. Palmaris brevis muscle

Figure from Gray's Anatomy for Students, 3rd edition, p. 800.

Identify the indicated muscles and nerves.



HAND: THENAR AND HYPOTHENAR MUSCLES



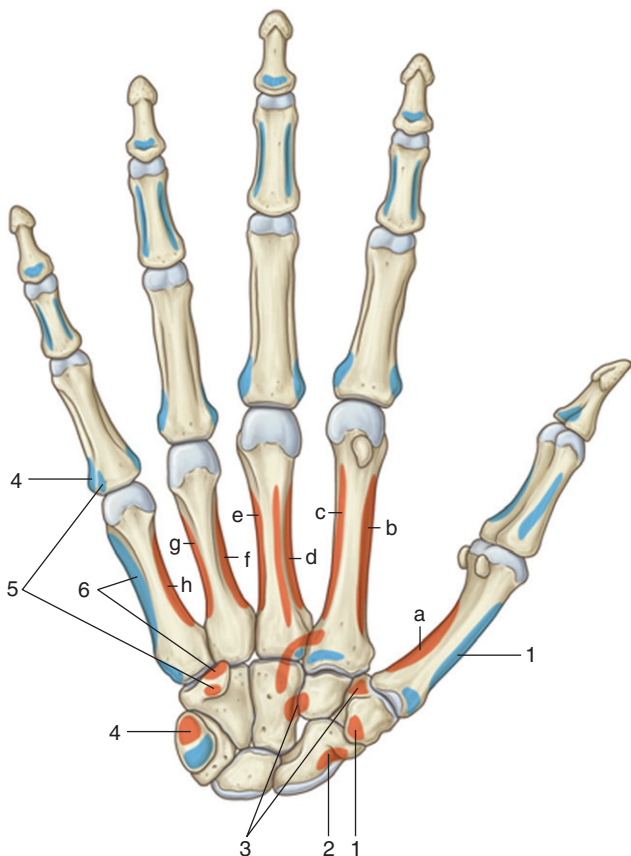
1. Flexor pollicis brevis muscle
2. Three thenar muscles
3. Adductor pollicis and first palmar interosseous muscles insert into medial side of extensor hood
4. Extensor hood
5. Flexor pollicis brevis and abductor pollicis brevis muscles insert into lateral side of extensor hood
6. Opponens pollicis muscle
7. Recurrent branch of median nerve
8. Abductor pollicis brevis muscle
9. Median nerve
10. Flexor retinaculum
11. Flexor carpi ulnaris muscle
12. Deep branch of ulnar nerve
13. Abductor digiti minimi muscle
14. Opponens digiti minimi muscle
15. Three hypthenar muscles
16. Flexor digiti minimi brevis muscle

IN THE CLINIC:

- **The three thenar muscles are innervated by the recurrent branch of the median nerve. In carpal tunnel syndrome, the thenar eminence becomes reduced in size and function of the muscles is compromised.**
- **The recurrent branch of the median nerve can be severed in knife wounds in which the blade cuts across the base of the thenar eminence.**

Figure from Gray's Anatomy for Students, 3rd edition, p. 806.

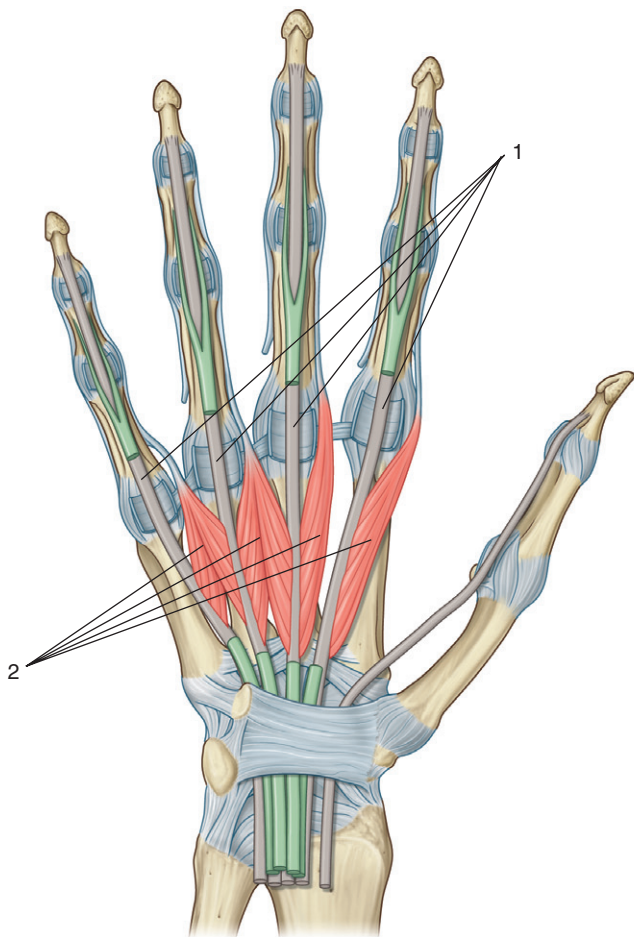
*Identify the muscles that attach to the areas indicated.
What is the major function and innervation of
each muscle?*



Muscles	Origin	Insertion	Innervation	Function
Thenar Muscles				
1. Opponens pollicis	Tubercle of trapezium and flexor retinaculum	Lateral margin and adjacent palmar surface of metacarpal I	Recurrent branch of median nerve (C8, T1)	Medially rotates thumb
2. Abductor pollicis brevis	Tubercles of scaphoid and trapezium and adjacent flexor retinaculum	Proximal phalanx and extensor hood of thumb	Recurrent branch of median nerve (C8, T1)	Abducts thumb at metacarpophalangeal joint
3. Flexor pollicis brevis	Tubercle of the trapezium and flexor retinaculum	Proximal phalanx of the thumb	Recurrent branch of median nerve (C8, T1)	Flexes thumb at metacarpophalangeal joint
Hypothenar Muscles				
4. Abductor digiti minimi	Pisiform, the pisohamate ligament, and tendon of flexor carpi ulnaris	Proximal phalanx of little finger	Deep branch of ulnar nerve (C8, T1)	Abducts little finger at metacarpophalangeal joint
5. Flexor digiti minimi brevis	Hook of the hamate and flexor retinaculum	Proximal phalanx of little finger	Deep branch of ulnar nerve (C8, T1)	Flexes little finger at metacarpophalangeal joint
6. Opponens digiti minimi	Hook of hamate and flexor retinaculum	Medial aspect of metacarpal V	Deep branch of ulnar nerve (C8, T1)	Laterally rotates metacarpal V

Figure from Gray's Atlas of Anatomy, 2nd edition, p. 442.

Identify the indicated muscles and tendons.



LUMBRICALS



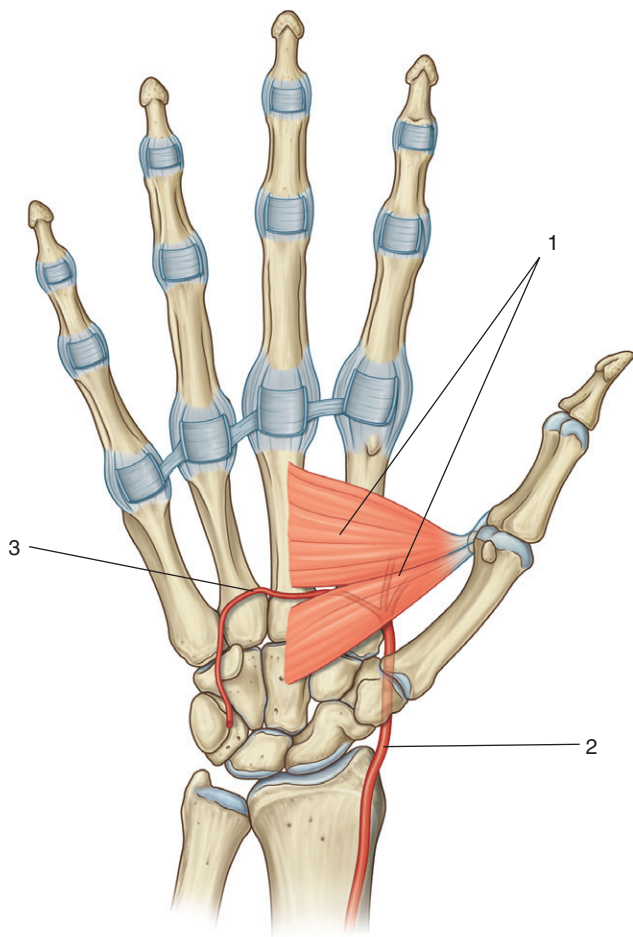
1. Tendons of flexor digitorum profundus muscle
2. Lumbrical muscles

IN THE CLINIC:

- **The lumbrical muscles flex the metacarpophalangeal joints and extend the interphalangeal joints. Loss of function of the lumbrical muscles contributes to “clawing” of the hand.**

Figure from Gray's Anatomy for Students, 3rd edition, p. 807.

Identify the indicated muscle and arteries.



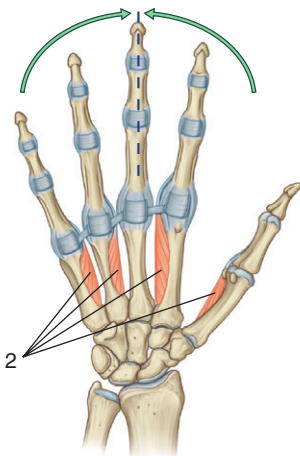
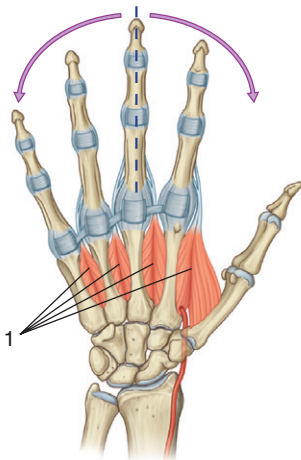
ADDUCTOR MUSCLES

1. Adductor pollicis muscle
2. Radial artery
3. Deep palmar arch

Figure from Gray's Anatomy for Students, 3rd edition, p. 811.



Identify the indicated muscles.





INTEROSSEOUS MUSCLES



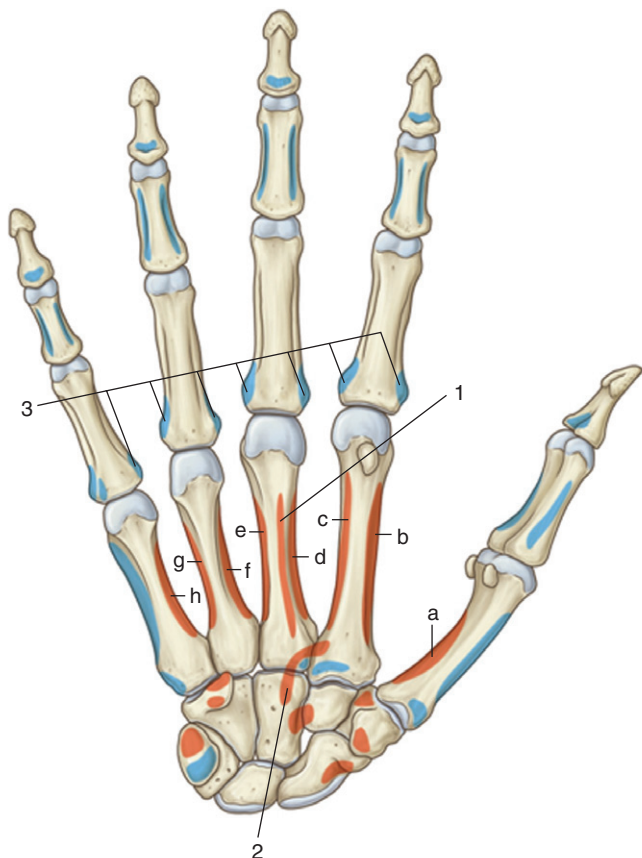
1. Dorsal interossei
2. Palmar interossei

IN THE CLINIC:

- The dorsal interossei abduct the second to fourth digits, and the palmar interossei adduct the second, fourth, and fifth digits relative to the third digit. All are innervated by the deep branch of the ulnar nerve. The ability to adduct the digits against resistance is used as a test motor function of the deep branch of the ulnar nerve.
- The palmar interosseous muscle associated with the thumb is rudimentary. When present it is often considered part of either adductor pollicis or flexor pollicis brevis.

Figure from Gray's Anatomy for Students, 3rd edition, p. 804.

*Identify the muscles that attach to the areas indicated.
What is the major function and innervation of
each muscle?*



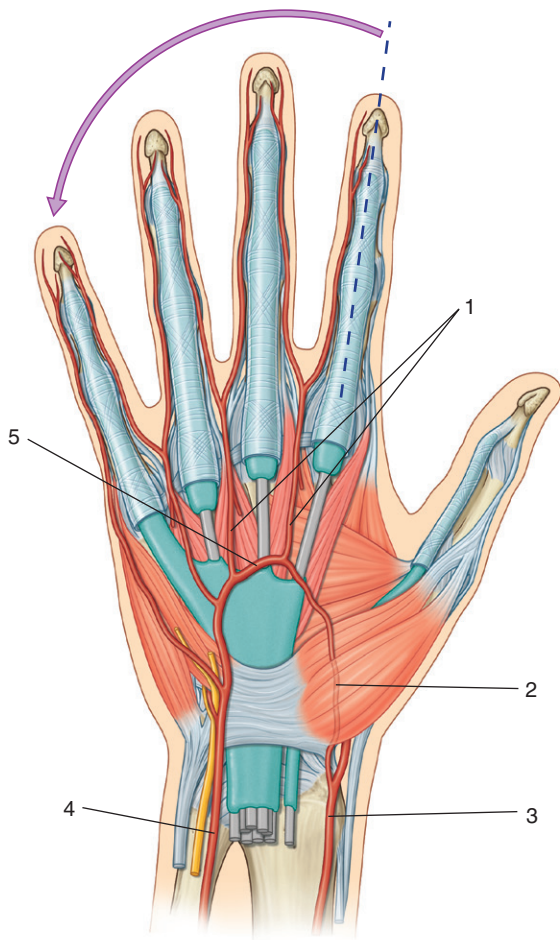
PALM OF HAND: MUSCLE ATTACHMENTS

INTRINSIC MUSCLES OF THE HAND (SPINAL SEGMENTS INDICATED IN BOLD ARE THE MAJOR SEGMENTS INNERVATING THE MUSCLE)

Muscles	Origin	Insertion	Innervation	Function
1 and 2. Adductor pollicis	1. Transverse head: metacarpal III 2. Oblique head: capitate and bases of metacarpals II and III	Base of proximal phalanx and extensor hood of thumb	Deep branch of ulnar nerve (C8, T1)	Adducts thumb
3. Dorsal interossei (four muscles)	Adjacent sides of metacarpals	Extensor hood and base of proximal phalanges of index, middle, and ring fingers	Deep branch of ulnar nerve (C8, T1)	Abduction of index, middle, and ring fingers at the metacarpophalangeal joints
3. Palmar interossei (four muscles)	Sides of metacarpals	Extensor hoods of the thumb, index, ring, and little fingers and the proximal phalanx of thumb	Deep branch of ulnar nerve (C8, T1)	Adduction of the thumb, index, ring, and little fingers at the metacarpophalangeal joints

Figure from Gray's Atlas of Anatomy, 2nd edition, p. 442.

Identify the indicated arteries.





SUPERFICIAL PALMAR ARCH



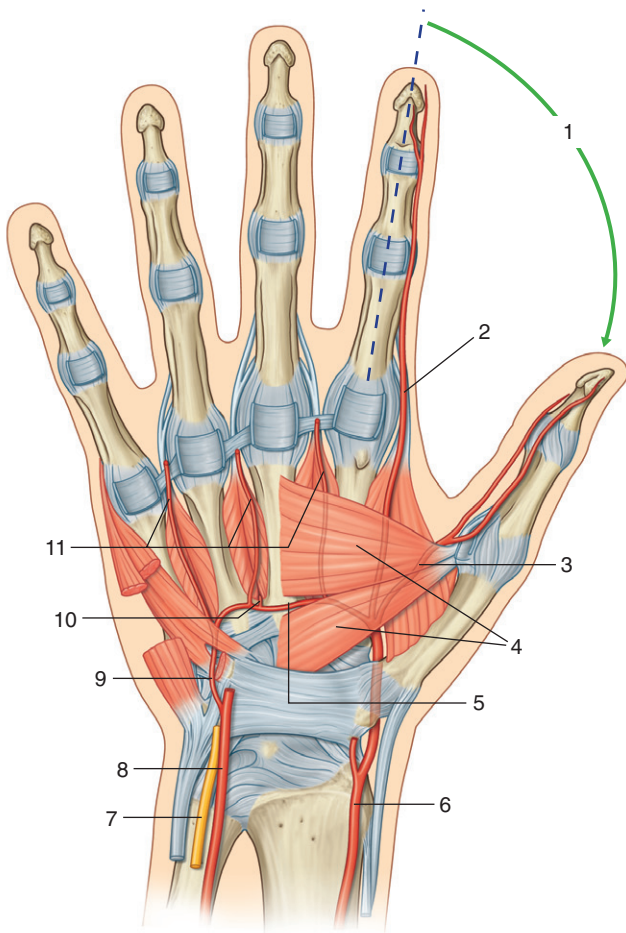
1. Common palmar digital arteries
2. Palmar branch of radial artery
3. Radial artery
4. Ulnar artery
5. Superficial palmar arch

IN THE CLINIC:

- **The ulnar artery is the predominant supply of the medial three and one-half digits via the superficial palmar arch. The radial artery supplies mainly the thumb and lateral half of the index finger.**
- **Allen's test is used to assess adequate anastomoses between the radial and ulnar arteries.**

Figure from Gray's Anatomy for Students, 3rd edition, p. 812.

Identify the indicated arteries and associated features.



DEEP PALMAR ARCH



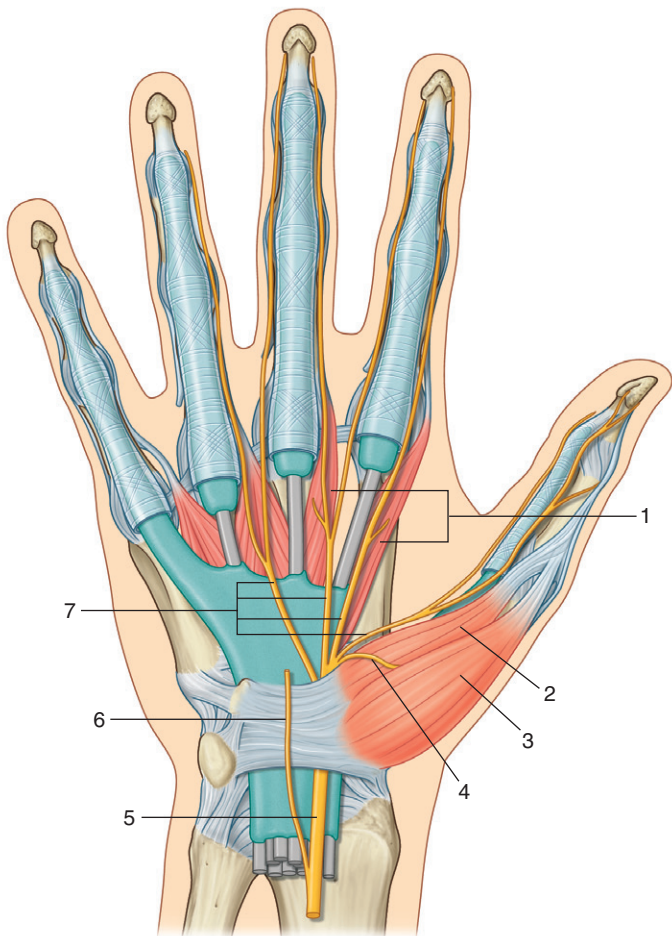
1. Region supplied mainly by radial artery
2. Radialis indicis artery
3. Princeps pollicis artery
4. Adductor pollicis muscle
5. Deep palmar arch
6. Radial artery
7. Ulnar nerve
8. Ulnar artery
9. Deep branch of ulnar artery
10. Perforating artery
11. Palmar metacarpal arteries

IN THE CLINIC:

- Interruption of the radial artery could lead to loss of blood supply to the thumb and lateral half of the index finger if anastomoses with the ulnar artery are not sufficient to maintain supply.

Figure from Gray's Anatomy for Students, 3rd edition, p. 813.

Identify the indicated nerves and muscles.



MEDIAN NERVE



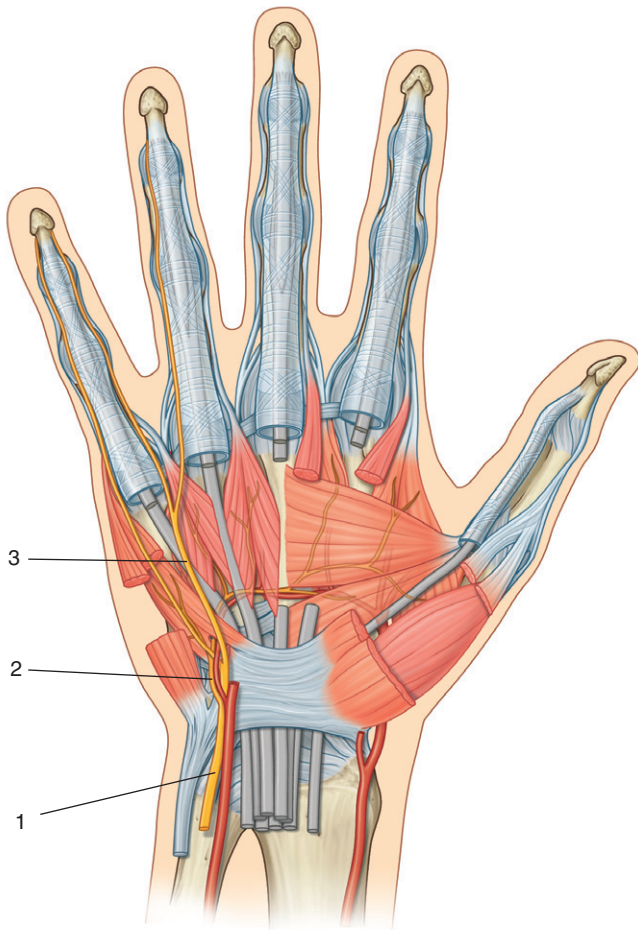
1. Lateral two lumbrical muscles
2. Flexor pollicis brevis muscle
3. Abductor pollicis brevis muscle
4. Recurrent branch (of median nerve)
5. Median nerve
6. Palmar branch (of median nerve)
7. Common palmar digital nerves

IN THE CLINIC:

- In the hand, the median nerve supplies motor innervation to the three thenar muscles and the two lateral lumbricals. It also carries general sensory information from the palmar aspect of the lateral three and one-half digits.
- In carpal tunnel syndrome, general sensory innervation from the central area of the palm and wrist is spared because the nerve (palmar branch of the median nerve) that innervates this region originates from the median nerve in the distal forearm and travels into the hand superficial to the carpal tunnel.

Figure from Gray's Anatomy for Students, 3rd edition, p. 817.

Identify the indicated nerves.





ULNAR NERVE



1. Ulnar nerve
2. Deep branch of the ulnar nerve
3. Superficial branch of the ulnar nerve

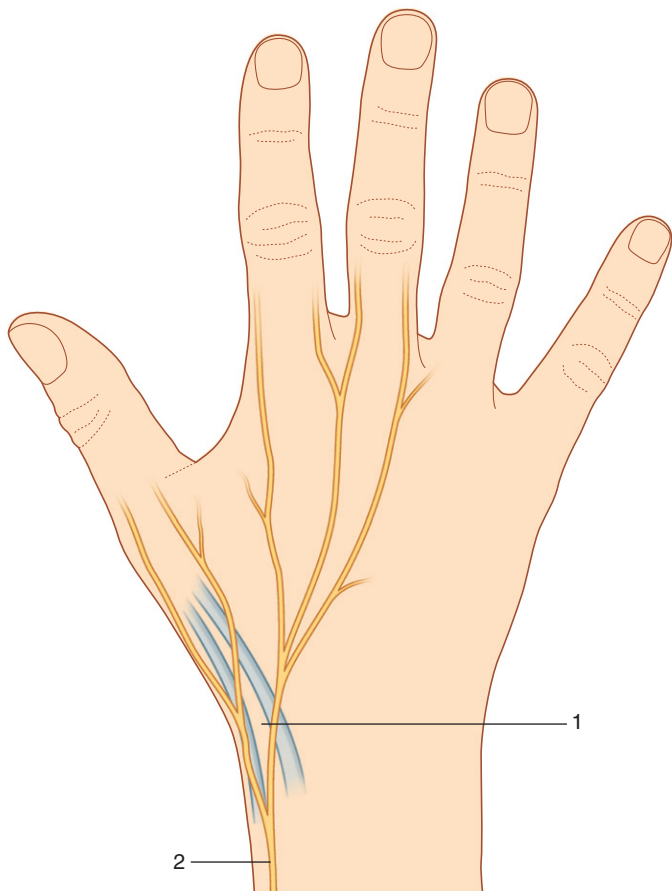
IN THE CLINIC:

- All intrinsic muscles of the hand are innervated by the ulnar nerve, except for the three thenar muscles and two lateral lumbricals, which are innervated by the median nerve. The deep branch of the ulnar nerve supplies most of the muscles except for the palmaris brevis muscle, which is supplied by the superficial branch. The ulnar nerve (via the superficial branch) carries cutaneous innervation from the palmar aspect of the medial one and one-half digits.
- Loss of function of the ulnar nerve leads to “clawing” of the hand, particularly of the medial digits.

Figure from Gray's Anatomy for Students, 3rd edition, p. 815.



Identify the indicated region and nerve.



RADIAL NERVE



1. Anatomical snuffbox
2. Superficial branch (of radial nerve)

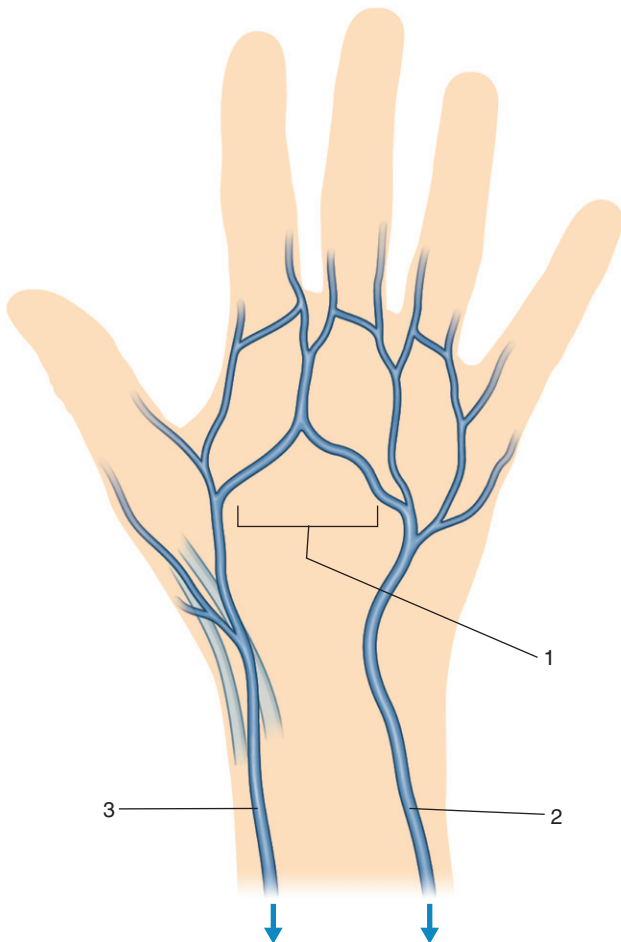
IN THE CLINIC:

- **A lesion of the superficial branch of the radial nerve results in loss of cutaneous innervation over the lateral side of the dorsal surface of the hand and over the thenar eminence. The radial nerve does not supply any of the intrinsic muscles in the hand.**

Figure from Gray's Anatomy for Students, 3rd edition, p. 818.



Identify the indicated veins.



DORSAL VENOUS ARCH



1. Dorsal venous network
2. Basilic vein
3. Cephalic vein

IN THE CLINIC:

- **Superficial veins on the dorsal aspect of the hand are often visible and can be accessed for numerous procedures.**

Figure from Gray's Anatomy for Students, 3rd edition, p. 814.



SECTION 8: HEAD AND NECK



- 259. Skull: Anterior View
- 260. Multidetector CT: Anterior View of Skull
- 261. Skull: Lateral View
- 262. Multidetector CT: Lateral View of Skull
- 263. Skull: Posterior View
- 264. Skull: Superior View
- 265. Skull: Inferior View
- 266. Skull: Anterior Cranial Fossa
- 267. Skull: Middle Cranial Fossa
- 268. Skull: Posterior Cranial Fossa
- 269. Meninges
- 270. Dural Septa
- 271. Meningeal Arteries
- 272. Blood Supply to Brain
- 273. Magnetic Resonance Angiogram: Carotid and Vertebral Arteries
- 274. Circle of Willis
- 275. Dural Venous Sinuses
- 276. Cavernous Sinus
- 277. Cranial Nerves: Floor of Cranial Cavity
- 278. Facial Muscles
- 279. Lateral Face
- 280. Sensory Nerves of the Head
- 281. Vessels of the Lateral Face
- 282. Scalp
- 283. Orbit: Bones
- 284. Lacrimal Apparatus
- 285. Orbit: Extra-ocular Muscles
- 286. MRI: Muscles of the Eyeball
- 287. Superior Orbital Fissure and Optic Canal
- 288. Orbit: Superficial Nerves
- 289. Orbit: Deep Nerves
- 290. Eyeball
- 291. Visceral Efferent (Motor) Innervation: Lacrimal Gland
- 292. Visceral Efferent (Motor) Innervation: Eyeball (Iris and Ciliary Body)
- 293. Visceral Efferent (Motor) Pathways through Pterygopalatine Fossa
- 294. External Ear
- 295. External, Middle, and Internal Ear
- 296. Tympanic Membrane



297. Middle Ear: Schematic View
298. Internal Ear
299. Infratemporal Region: Muscles of Mastication
300. Infratemporal Region: Muscles
301. Infratemporal Region: Arteries
302. Infratemporal Region: Nerves, Part 1
303. Infratemporal Region: Nerves, Part 2
304. Parasympathetic Innervation of Salivary Glands
305. Pterygopalatine Fossa: Gateways
306. Pterygopalatine Fossa: Nerves
307. Pharynx: Posterior View of Muscles
308. Pharynx: Lateral View of Muscles
309. Pharynx: Midsagittal Section
310. Pharynx: Posterior View, Opened
311. Larynx: Overview
312. Larynx: Cartilage and Ligaments
313. Larynx: Superior View of Vocal Ligaments
314. Larynx: Posterior View
315. Larynx: Laryngoscopic Images
316. Larynx: Intrinsic Muscles
317. Larynx: Nerves
318. Nasal Cavity: Paranasal Sinuses
319. Radiographs: Nasal Cavities and Paranasal Sinuses
320. CT: Nasal Cavities and Paranasal Sinuses
321. Nasal Cavity: Nasal Septum
322. Nasal Cavity: Lateral Wall, Bones
323. Nasal Cavity: Lateral Wall, Mucosa, and Openings
324. Nasal Cavity: Arteries
325. Nasal Cavity: Nerves
326. Oral Cavity: Overview
327. Oral Cavity: Floor
328. Oral Cavity: Tongue
329. Oral Cavity: Sublingual Glands
330. Oral Cavity: Glands
331. Oral Cavity: Salivary Gland Nerves
332. Oral Cavity: Soft Palate (Overview)
333. Oral Cavity: Palate, Arteries, and Nerves

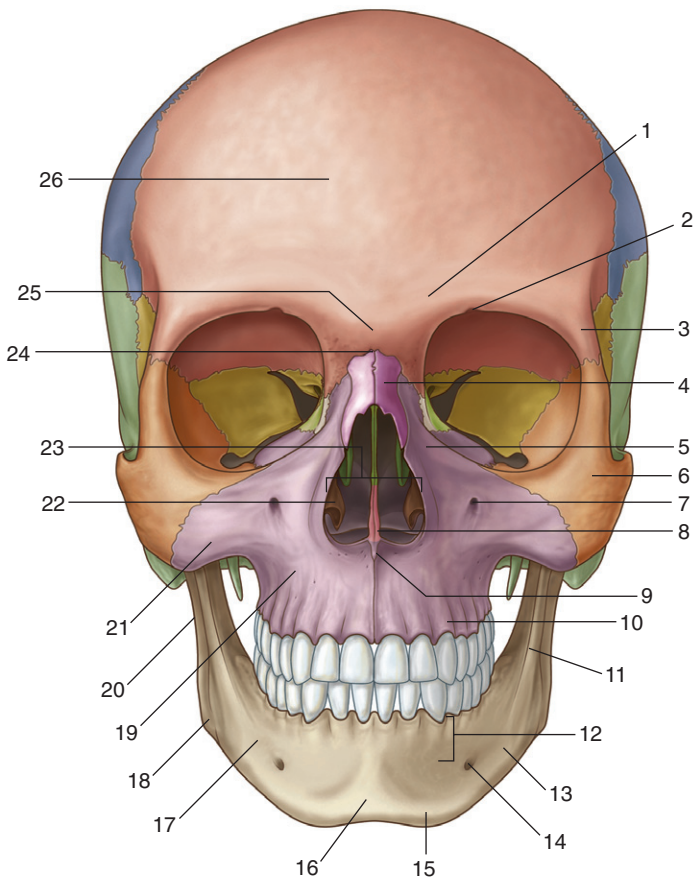


- 334. Oral Cavity: Teeth
- 335. Neck: Triangles
- 336. Neck: Fascia
- 337. Neck: Superficial Veins
- 338. Neck: Anterior Triangle, Infrahyoid Muscles
- 339. Neck: Anterior Triangle, Carotid System
- 340. Neck: Anterior Triangle, Glossopharyngeal Nerve
- 341. Neck: Anterior Triangle, Vagus Nerve
- 342. Neck: Anterior Triangle, Hypoglossal Nerve, and Ansa Cervicalis
- 343. Neck: Anterior Triangle, Anterior View Thyroid
- 344. Neck: Anterior Triangle, Posterior View Thyroid
- 345. Neck: Posterior Triangle, Muscles
- 346. Neck: Posterior Triangle, Nerves
- 347. Base of Neck
- 348. Base of Neck: Arteries
- 349. Base of Neck: Lymphatics





Identify the indicated features and bones in this anterior view of the skull.





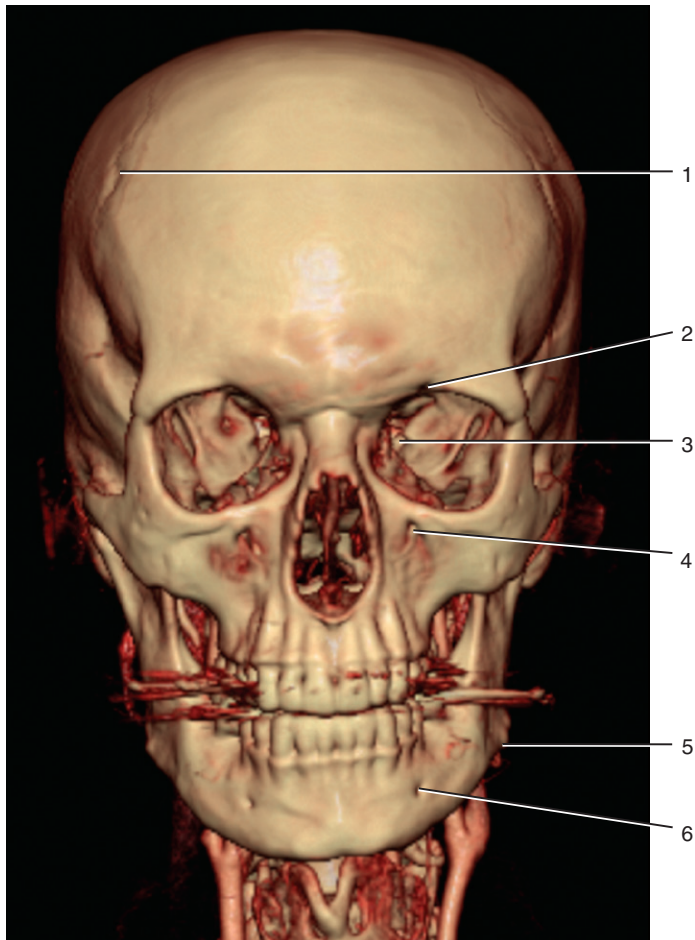
SKULL: ANTERIOR VIEW



1. Superciliary arch
2. Supra-orbital notch (foramen)
3. Zygomatic process (of frontal bone)
4. Nasal bone
5. Frontal process (of maxilla)
6. Zygomatic bone
7. Infra-orbital foramen
8. Nasal crest
9. Anterior nasal spine
10. Alveolar process (of maxilla)
11. Oblique line (of mandible)
12. Alveolar part (of mandible)
13. Mandible
14. Mental foramen
15. Mental tubercle
16. Mental protuberance
17. Body of mandible
18. Angle of mandible
19. Maxilla
20. Ramus of mandible
21. Zygomatic process (of maxilla)
22. Inferior nasal concha
23. Piriform aperture
24. Nasion
25. Glabella
26. Frontal bone

Figure from Gray's Anatomy for Students, 3rd edition, p. 855.

Identify the indicated structures.





MULTIDETECTOR CT: ANTERIOR VIEW OF SKULL

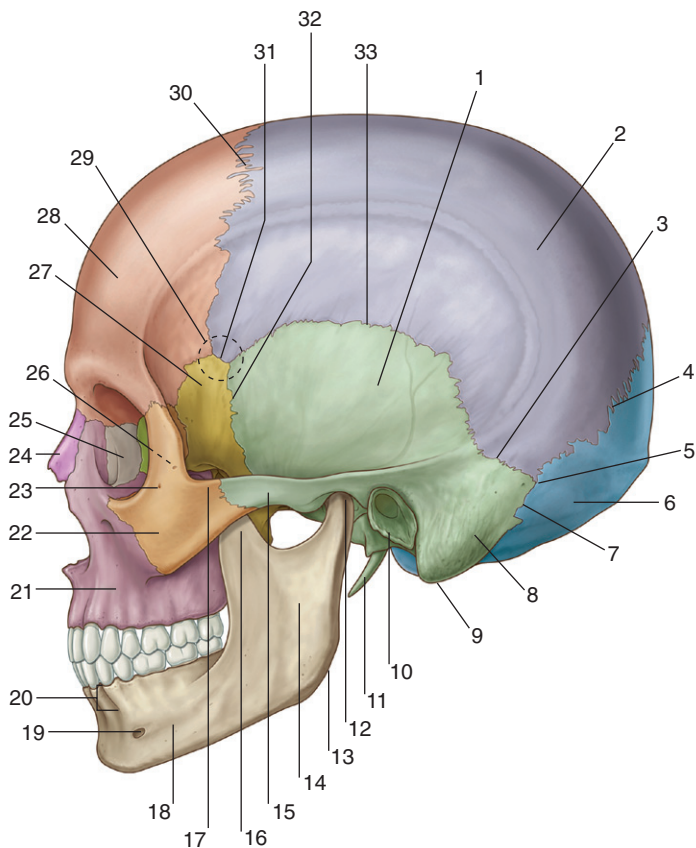


1. Coronal suture
2. Supra-orbital notch (foramen)
3. Superior orbital fissure
4. Infra-orbital foramen
5. Angle of mandible
6. Mental foramen

Figure from Gray's Basic Anatomy, p. 417.



Identify the indicated features and bones in this lateral view of the skull.





SKULL: LATERAL VIEW



1. Squamous part (of temporal bone)
2. Parietal bone
3. Parietomastoid suture
4. Lambdoid suture
5. Asterion
6. Occipital bone
7. Occipitomastoid suture
8. Mastoid part of temporal bone
9. Mastoid process
10. Tympanic part (of temporal bone)
11. Styloid process
12. Condylar process (of mandible)
13. Angle (of mandible)
14. Ramus of mandible
15. Zygomatic process (of temporal bone)
16. Coronoid process (of mandible)
17. Temporal process (of zygomatic bone)
18. Body of mandible
19. Mental foramen
20. Alveolar part (of mandible)
21. Maxilla
22. Zygomatic bone
23. Zygomaticofacial foramen
24. Nasal bone
25. Lacrimal bone
26. Zygomaticotemporal foramen (on deep surface of zygomatic bone)
27. Greater wing (of sphenoid bone)
28. Frontal bone
29. Pterion
30. Coronal suture
31. Sphenoparietal suture
32. Sphenosquamous suture
33. Squamous suture

Figure from Gray's Anatomy for Students, 3rd edition, p. 857.

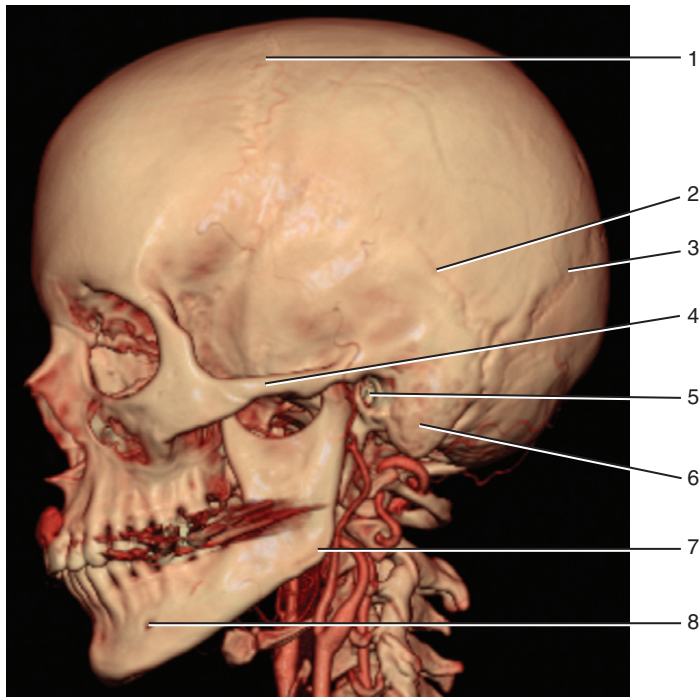


MULTIDETECTOR CT: LATERAL VIEW OF SKULL



262

Identify the indicated structures.





MULTIDETECTOR CT: LATERAL VIEW OF SKULL



1. Coronal suture
2. Squamous suture
3. Lamboid suture
4. Zygomatic arch
5. External acoustic meatus
6. Mastoid process
7. Angle of mandible
8. Mental foramen

Figure from Gray's Basic Anatomy, p. 419.

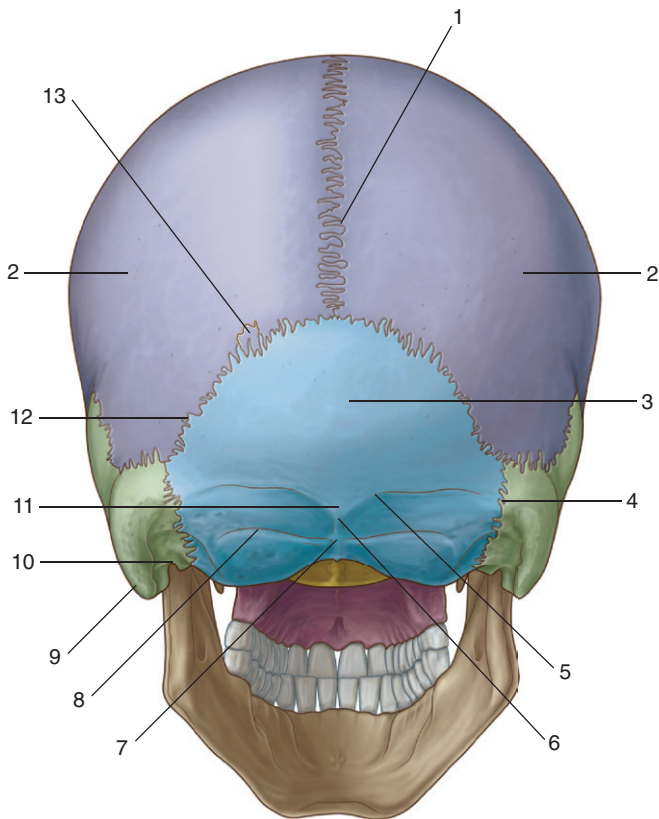


SKULL: POSTERIOR VIEW



263

Identify the indicated features and bones in this posterior view of the skull.





SKULL: POSTERIOR VIEW

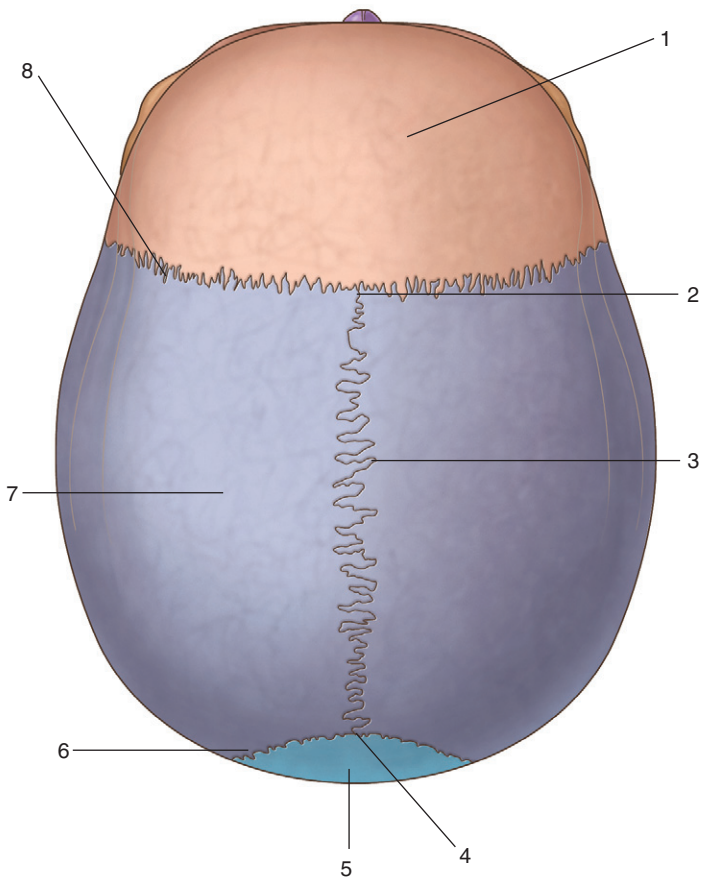


1. Sagittal suture
2. Parietal bone
3. Squamous part (of occipital bone)
4. Occipitomastoid suture
5. Superior nuchal line
6. Inion
7. External occipital crest
8. Inferior nuchal line
9. Mastoid process
10. Mastoid notch
11. External occipital protuberance
12. Lambdoid suture
13. Sutural bone

Figure from Gray's Anatomy for Students, 3rd edition, p. 859.



Identify the indicated features and bones in this superior view of the skull.





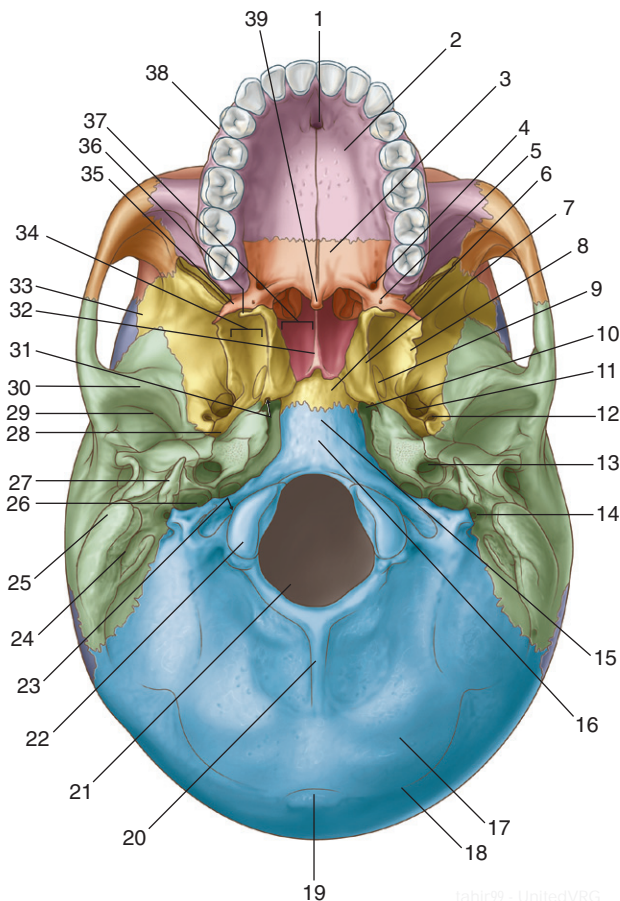
SKULL: SUPERIOR VIEW



1. Frontal bone
2. Bregma
3. Sagittal suture
4. Lambda
5. Occipital bone
6. Lambdoid suture
7. Parietal bone
8. Coronal suture

Figure from Gray's Anatomy for Students, 3rd edition, p. 860.

Identify the indicated structures in this inferior view of the skull.





SKULL: INFERIOR VIEW

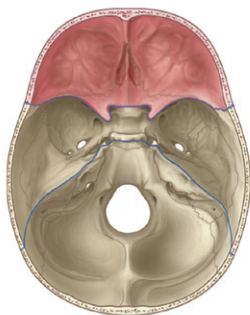
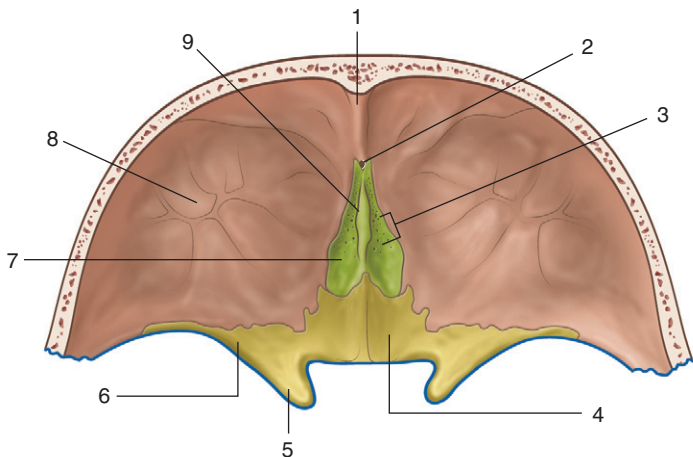


1. Incisive fossa
2. Hard palate (palatine process of maxilla)
3. Hard palate (horizontal plate of palatine bone)
4. Greater palatine foramen
5. Lesser palatine foramen
6. Body of sphenoid
7. Medial plate of pterygoid process
8. Lateral plate of pterygoid process
9. Scaphoid fossa
10. Foramen lacerum
11. Foramen ovale
12. Foramen spinosum
13. Carotid canal
14. Stylomastoid foramen
15. Basilar part of occipital bone
16. Pharyngeal tubercle
17. Inferior nuchal line
18. Superior nuchal line
19. External occipital protuberance
20. External occipital crest
21. Foramen magnum
22. Occipital condyle
23. Hypoglossal canal
24. Mastoid notch
25. Mastoid process
26. Jugular foramen
27. Styloid process
28. Groove for auditory tube
29. Mandibular fossa
30. Articular tubercle
31. Opening of pterygoid canal
32. Vomer
33. Greater wing (of sphenoid bone)
34. Pterygoid fossa
35. Pyramidal process of palatine bone
36. Pterygoid hamulus
37. Posterior nasal aperture (choana)
38. Alveolar arch
39. Posterior nasal spine

Figure from Gray's Anatomy for Students, 3rd edition, p. 861.



Identify the indicated structures in the anterior cranial fossa.





SKULL: ANTERIOR CRANIAL FOSSA



1. Frontal crest
2. Foramen caecum
3. Foramina of cribriform plate
4. Body of sphenoid
5. Anterior clinoid process
6. Lesser wing of sphenoid
7. Cribriform plate
8. Orbital part of frontal bone
9. Crista galli

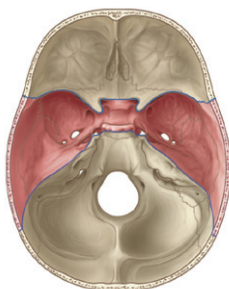
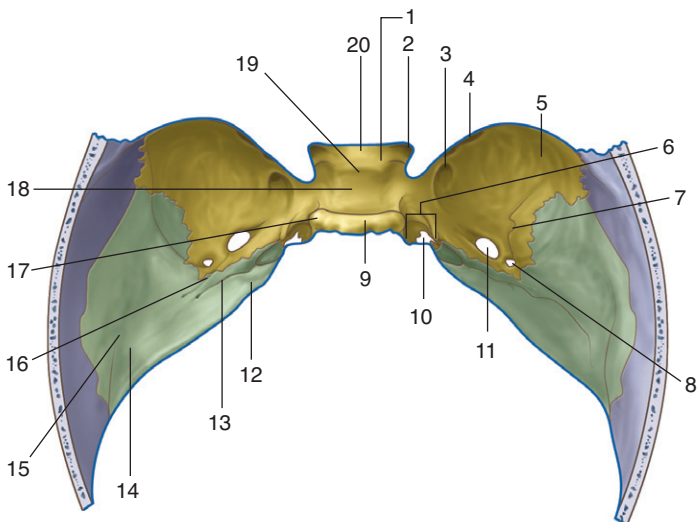
IN THE CLINIC:

- **Treatment of primary brain injury is extremely limited. Axonal disruption and cellular death are generally irrecoverable. When the brain is injured, it tends to swell; however, it is encased in a fixed space (cranial cavity), and this swelling impairs cerebral function. Furthermore, it decreases venous return, necessitating a higher arterial pressure. This causes the brain to swell further, causing compression of the brain. Compression of the brain may result in extrusion of the brainstem (coning) through the foramen magnum.**

Figure from Gray's Anatomy for Students, 3rd edition, p. 865.



Identify the indicated structures in the middle cranial fossa.





SKULL: MIDDLE CRANIAL FOSSA



1. Middle clinoid process
2. Optic canal
3. Foramen rotundum
4. Superior orbital fissure
5. Greater wing (of sphenoid)
6. Groove for internal carotid artery
7. Groove for middle meningeal artery
8. Foramen spinosum
9. Dorsum sellae
10. Foramen lacerum
11. Foramen ovale
12. Trigeminal impression
13. Groove and hiatus for greater petrosal nerve
14. Arcuate eminence
15. Tegmen tympani
16. Groove and hiatus for lesser petrosal nerve
17. Posterior clinoid process
18. Hypophysial fossa
19. Tuberculum sellae
20. Chiasmatic sulcus

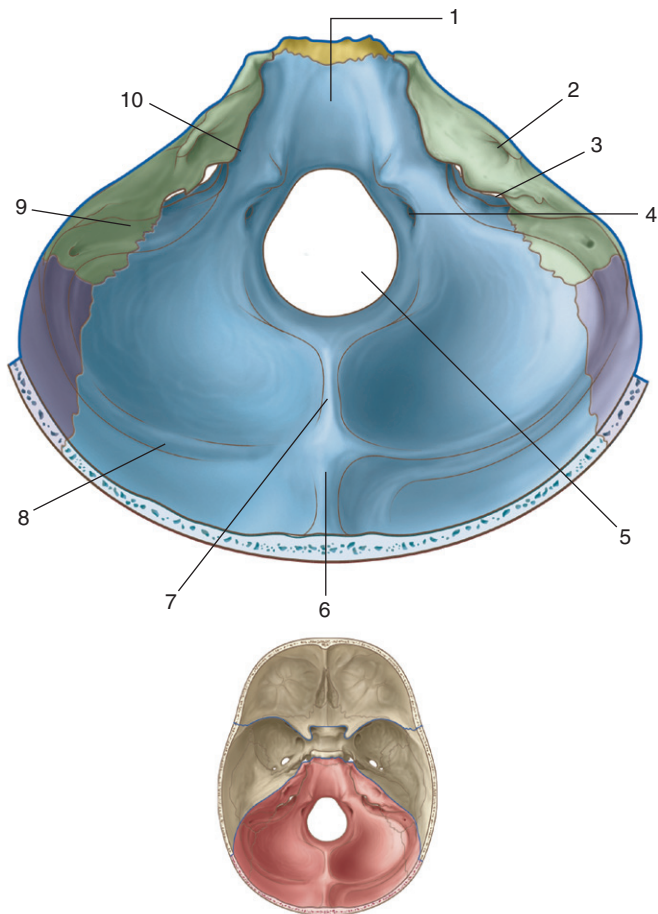
IN THE CLINIC:

- **Determination of the site from which a tumor arises is important because misinterpretation of the location can have serious consequences for the patient. When assessing any tumor in the brain, it is important to determine whether it is within the brain or outside the brain. Tumors outside the brain include meningiomas, typically found around the falx cerebri, and acoustic neuromas, typically found around the cerebellopontine angle associated with the vestibulocochlear nerve (VIII).**

Figure from Gray's Anatomy for Students, 3rd edition, p. 867.



Identify the indicated structures in the posterior cranial fossa.





SKULL: POSTERIOR CRANIAL FOSSA



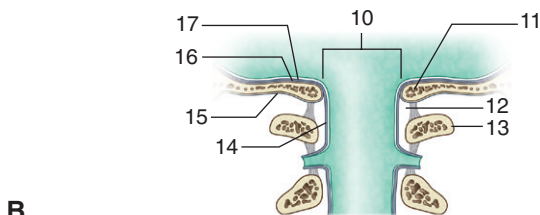
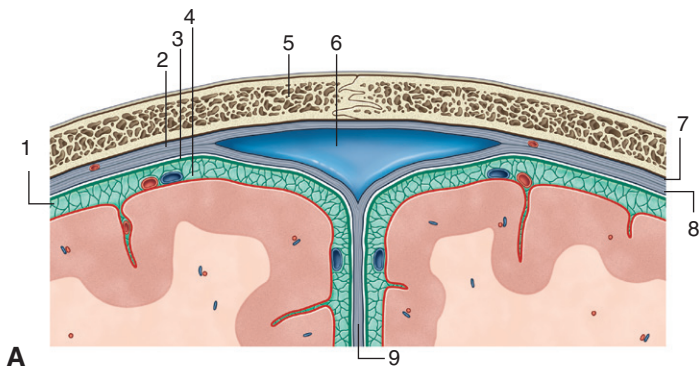
1. Clivus
2. Internal acoustic meatus
3. Jugular foramen
4. Hypoglossal canal
5. Foramen magnum
6. Internal occipital protuberance
7. Internal occipital crest
8. Groove for transverse sinus
9. Groove for sigmoidal sinus
10. Groove for inferior petrosal sinus

IN THE CLINIC:

- **The Glasgow Coma Scale is used to assess the level of consciousness in head-injured patients. There is a total score of 15 points. A score of 15/15 indicates a patient is alert and fully oriented, whereas 3/15 indicates a deep coma. The points score consists of the best motor response, 6 points best score; best verbal response, 5 points best score; and best eye movement response, 4 points best score.**

Figure from Gray's Anatomy for Students, 3rd edition, p. 869.

Identify the indicated structures.





MENINGES



1. Subarachnoid space
2. Dura mater
3. Arachnoid mater
4. Pia mater
5. Skull
6. Superior sagittal sinus
7. Outer periosteal layer of dura mater
8. Inner meningeal layer of dura mater
9. Dural partition—falx cerebri
10. Foramen magnum
11. Skull
12. Spinal extradural space
13. Vertebra C1
14. Spinal dura mater
15. Periosteum
16. Periosteal Layer of dura mater
17. Meningeal layer of dura mater

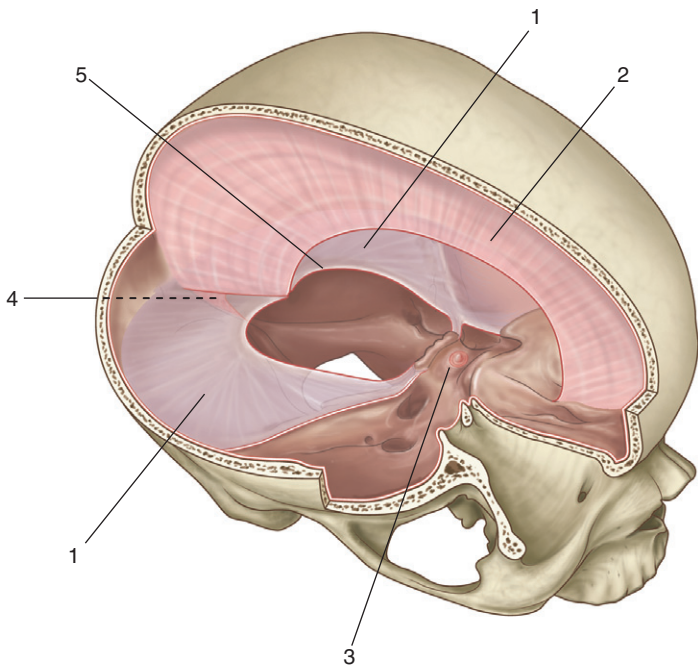
IN THE CLINIC:

- **Extradural hemorrhage results from tearing of the branches of the middle meningeal artery and typically occurs in the region of the pterion. Arterial blood collects between the periosteal layer of the dura and the calvaria.**
- **Subdural hemorrhage develops between the dura and the arachnoid. It results from venous bleeding, usually from a torn cerebral vein where it enters the superior sagittal sinus.**
- **Subarachnoid hemorrhage usually results from a ruptured intracerebral aneurysm arising from the vessels supplying and associated with the arterial circle of Willis.**

Figure from Gray's Anatomy for Students, 3rd edition, p. 873.



Identify the indicated dural partitions and related features.





DURAL SEPTA



1. Tentorium cerebelli
2. Falx cerebri
3. Diaphragma sellae
4. Falx cerebelli
5. Tentorial notch

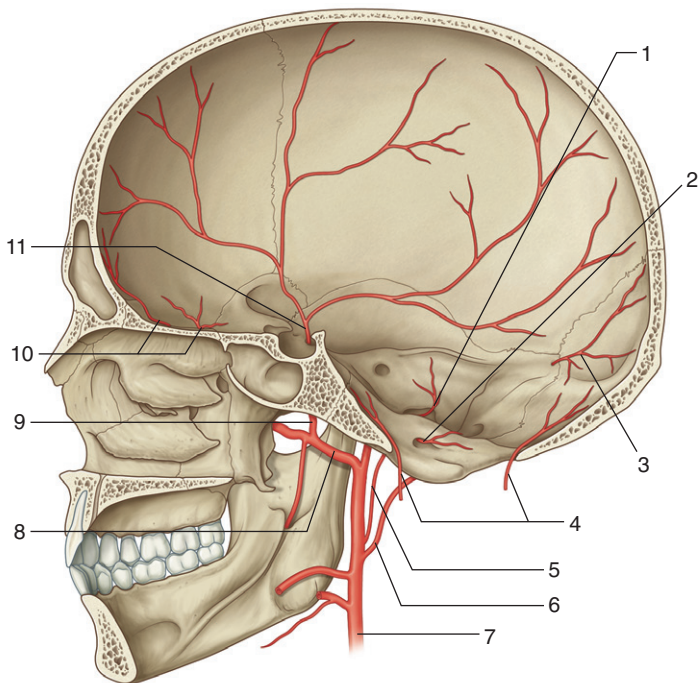
IN THE CLINIC:

- **Meningitis is an uncommon infection involving the arachnoid mater and pia mater. Infection typically occurs via a bloodborne route, but it can be by direct spread, as might occur in trauma or from the nasal cavities through the cribriform plate. The patient may have mild headaches, fever, drowsiness, and nausea progressing to photophobia and neck pain with straight-leg raises.**

Figure from Gray's Anatomy for Students, 3rd edition, p. 874.



Identify the indicated structures related to the arterial supply of the dura mater.





MENINGEAL ARTERIES



1. Posterior meningeal artery (from ascending pharyngeal artery)
2. Meningeal branch (from ascending pharyngeal artery)
3. Meningeal branch (from occipital artery)
4. Meningeal branches (from vertebral artery)
5. Ascending pharyngeal artery
6. Occipital artery
7. External carotid artery
8. Maxillary artery
9. Middle meningeal artery
10. Anterior meningeal arteries (from ethmoidal arteries)
11. Middle meningeal artery

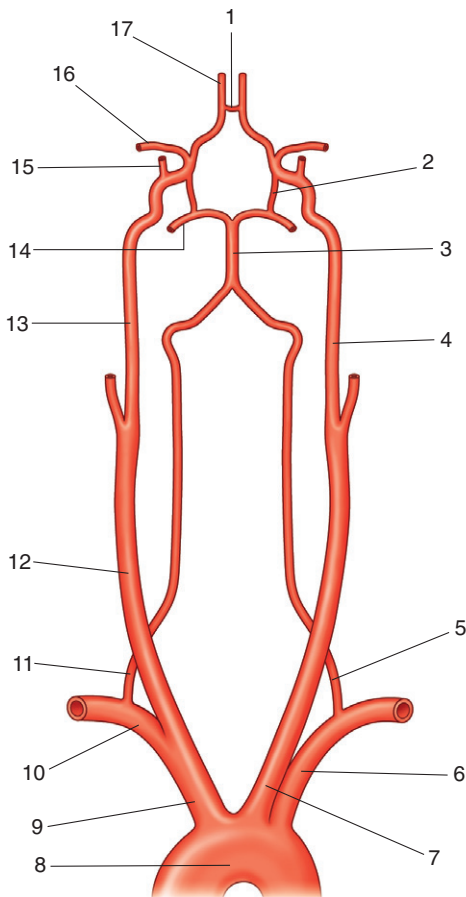
IN THE CLINIC:

- **The pterion is an important clinical point on the lateral aspect of the skull. At the pterion the frontal, parietal, greater wing of the sphenoid, and temporal bones come together. Deep to this structure is the middle meningeal artery. An injury to this point of the skull is extremely serious because damage to this vessel may produce a significant extradural hematoma, which can be fatal.**

Figure from Gray's Anatomy for Students, 3rd edition, p. 875.



Identify the indicated arteries related to the blood supply to the brain.





BLOOD SUPPLY TO BRAIN



1. Anterior communicating
2. Posterior communicating
3. Basilar
4. Left internal carotid
5. Left vertebral
6. Left subclavian
7. Left common carotid
8. Aortic arch
9. Brachiocephalic trunk
10. Right subclavian
11. Right vertebral
12. Right common carotid
13. Right internal carotid
14. Posterior cerebral
15. Ophthalmic
16. Middle cerebral
17. Anterior cerebral

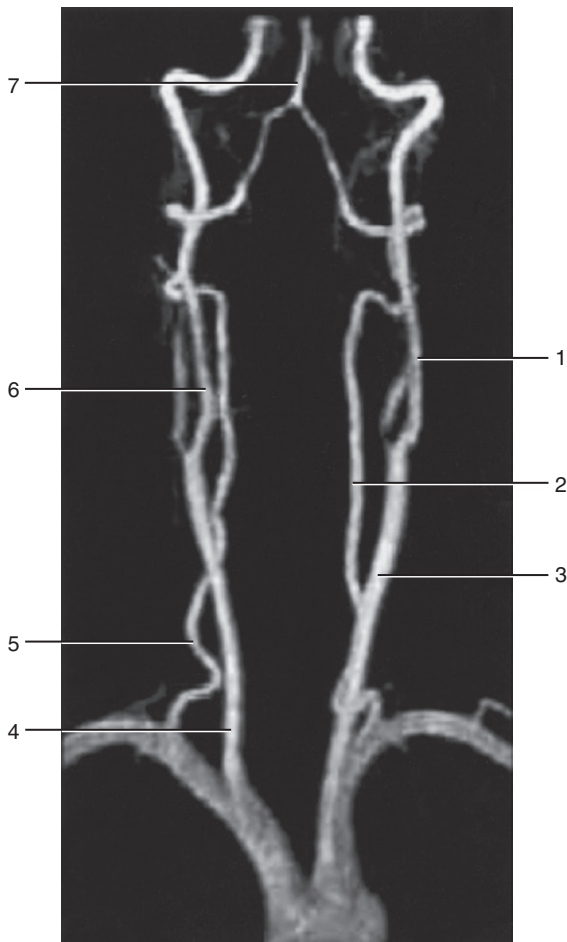IN THE CLINIC:

- **A stroke is the acute development of a neurologic deficit as a result of localized or diffuse cerebral hypoperfusion. The causes include cerebral thrombosis, cerebral hemorrhage, subarachnoid hemorrhage, and cerebral embolus. In many cases, small vessel cerebral vascular obstruction is caused by emboli from an atherosclerotic plaque within more proximal vessels in the neck and thorax. Transient ischemic attacks have exactly the same etiology and clinical findings as strokes, with the exception that recovery is total within 24 hours.**

Figure from Gray's Anatomy for Students, 3rd edition, p. 881.



Identify the indicated structures.





MAGNETIC RESONANCE ANGIOGRAM: CAROTID AND VERTEBRAL ARTERIES

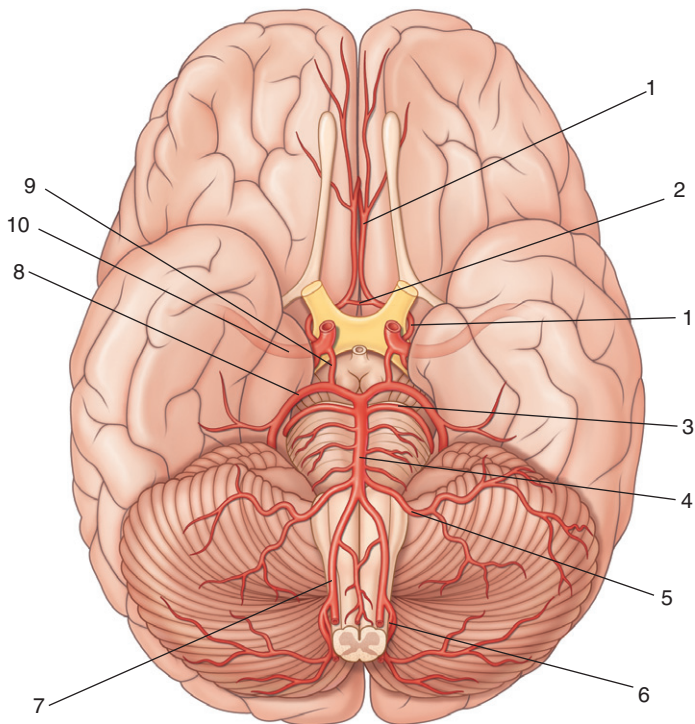


1. Left internal carotid
2. Left vertebral
3. Left common carotid
4. Right common carotid
5. Right vertebral
6. Right internal carotid
7. Basilar

Figure from Gray's Basic Anatomy, p. 435.



Identify the indicated arteries on this inferior view of the brain.





CIRCLE OF WILLIS



1. Anterior cerebral
2. Anterior communicating
3. Superior cerebellar
4. Basilar
5. Anterior inferior cerebellar
6. Posterior inferior cerebellar
7. Vertebral
8. Posterior cerebral
9. Posterior communicating
10. Middle cerebral

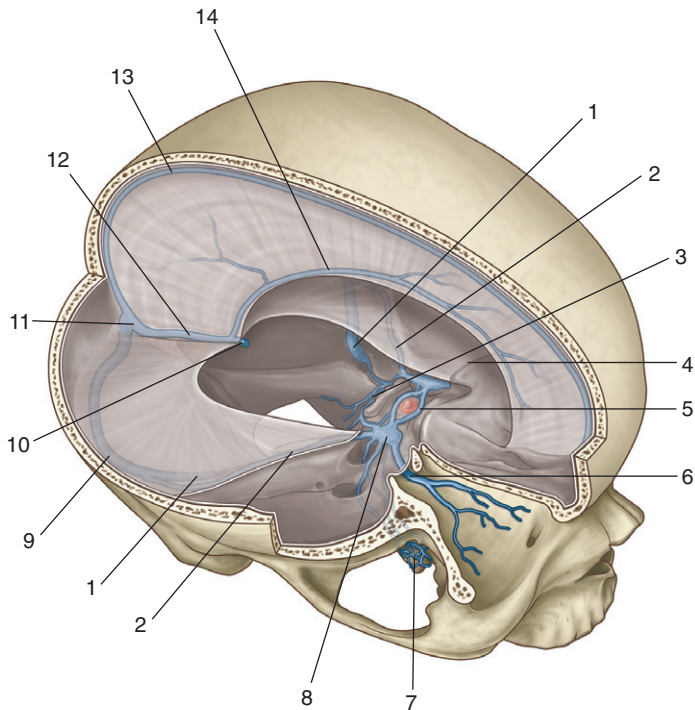
IN THE CLINIC:

- **Cerebral aneurysms arise from the vessels in and around the cerebral arterial circle of Willis, typically the anterior communicating artery, posterior communicating artery, the branches of the middle cerebral artery, the distal end of the basilar artery, and the posterior inferior cerebellar artery. As the aneurysm ruptures, the patient complains of a sudden-onset “thunderclap” headache that produces neck stiffness and possibly vomiting.**

Figure from Gray’s Anatomy for Students, 3rd edition, p. 882.



Identify the indicated veins and dural venous sinuses.





DURAL VENOUS SINUSES



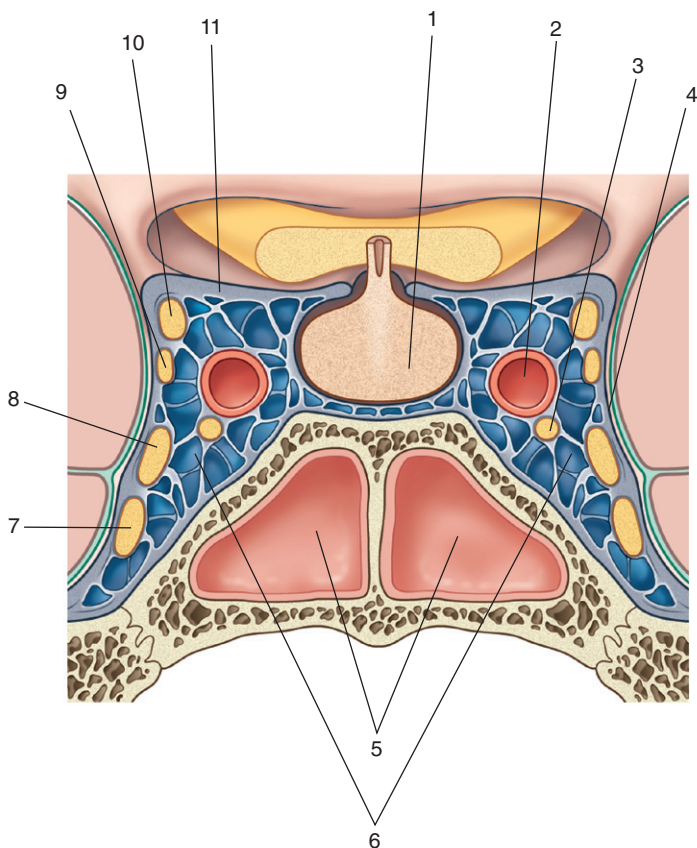
1. Sigmoid sinus
2. Superior petrosal sinus
3. Basilar sinus
4. Sphenoparietal sinus
5. Intercavernous sinus
6. Superior ophthalmic vein
7. Pterygoid plexus of veins
8. Cavernous sinus
9. Right transverse sinus
10. Great cerebral vein
11. Confluence of sinuses
12. Straight sinus
13. Superior sagittal sinus
14. Inferior sagittal sinus

IN THE CLINIC:

- **Diploic veins, which run between the internal and external tables of compact bone in the roof of the cranial cavity, and emissary veins, which pass from outside the cranial cavity to inside, both empty into dural venous sinuses. The emissary veins are most important clinically because they can be a conduit for infections to enter the cranial cavity. The largest emissary veins are the superior ophthalmic veins that drain the orbit.**

Figure from Gray's Anatomy for Students, 3rd edition, p. 887.

Identify the indicated structures related to the cavernous sinus.





CAVERNOUS SINUS



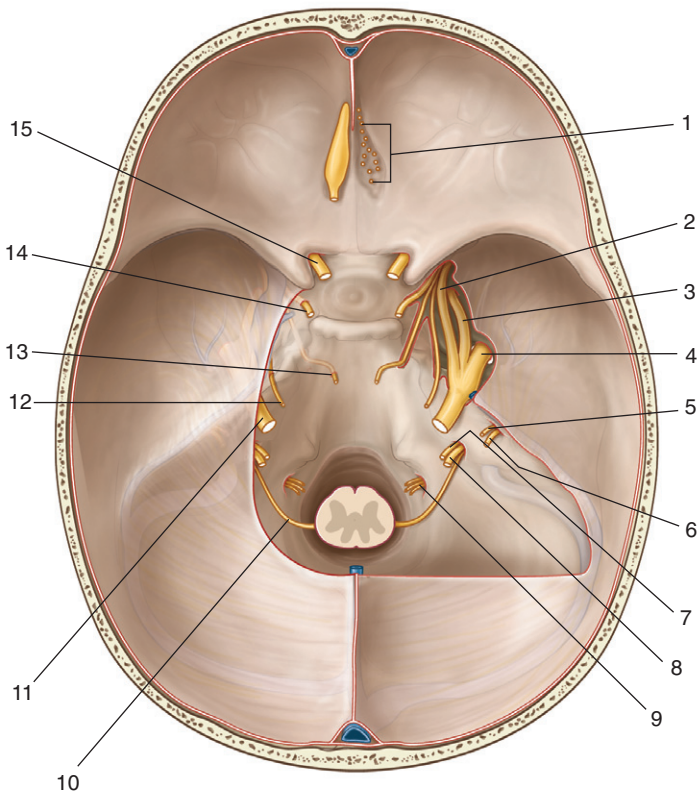
1. Pituitary gland
2. Internal carotid artery
3. Abducent nerve (VI)
4. Dura mater
5. Sphenoidal sinus
6. Cavernous sinus
7. Maxillary division of trigeminal nerve (V_2)
8. Ophthalmic division of trigeminal nerve (V_1)
9. Trochlear nerve (IV)
10. Oculomotor nerve (III)
11. Diaphragma sellae

IN THE CLINIC:

- **The cavernous sinuses receive blood not only from cerebral veins but also from ophthalmic veins and emissary veins (from the pterygoid plexus of veins). These connections provide pathways for infections to pass from extracranial sites into intracranial locations. In addition, because structures pass through the cavernous sinuses and are located in the walls of these sinuses, they are vulnerable to injury due to inflammation.**

Figure from Gray's Anatomy for Students, 3rd edition, p. 888.

Identify the indicated cranial nerves as they leave the cranial cavity.





CRANIAL NERVES: FLOOR OF CRANIAL CAVITY

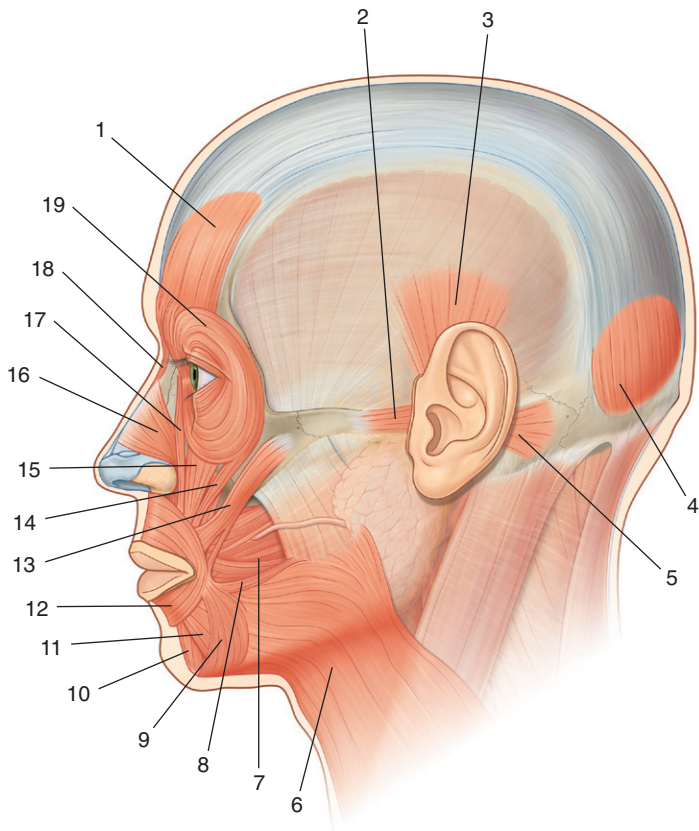


1. Olfactory nerve (I)
2. Ophthalmic nerve (V_1)
3. Maxillary nerve (V_2)
4. Mandibular nerve (V_3)
5. Facial nerve (VII)
6. Vestibulocochlear nerve (VIII)
7. Glossopharyngeal nerve (IX)
8. Vagus nerve (X)
9. Hypoglossal nerve (XII)
10. Accessory nerve (XI)
11. Trigeminal nerve (V)
12. Trochlear nerve (IV)
13. Abducent nerve (VI)
14. Oculomotor nerve (III)
15. Optic nerve (II)

Figure from Gray's Anatomy for Students, 3rd edition, p. 896.



Identify the indicated facial muscles.





FACIAL MUSCLES



1. Frontal belly of occipitofrontalis
2. Anterior auricular
3. Superior auricular
4. Occipital belly of occipitofrontalis
5. Posterior auricular
6. Platysma
7. Buccinator
8. Risorius
9. Depressor anguli oris
10. Mentalis
11. Depressor labii inferioris
12. Orbicularis oris
13. Zygomaticus major
14. Zygomaticus minor
15. Levator labii superioris
16. Nasalis
17. Levator labii superioris alaeque nasi
18. Procerus
19. Orbicularis oculi

IN THE CLINIC:

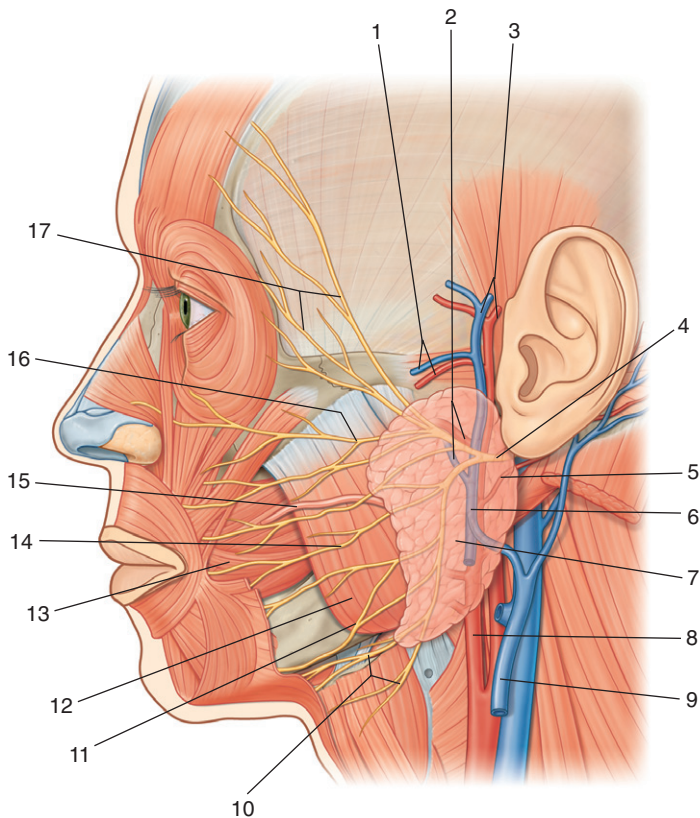
All muscles of facial expressions are innervated by the facial nerve (VII). The complexity of the facial nerve (VII) is demonstrated by the different pathologic processes and sites at which these processes occur. Common sites of pathology that involve the facial nerve include the following:

- **Central lesions:** a primary brainstem lesion affecting sensory and motor functions of the nerve, including its special components.
- **At and around the geniculate ganglion:** accompanied by loss of motor function on the same side of the face, taste to the anterior two thirds of the tongue, lacrimation, and some salivation.
- **At and around the stylomastoid foramen:** loss of motor function on the same side of the face.

Figure from Gray's Anatomy for Students, 3rd edition, p. 904.



Identify the indicated structures in this lateral view of the face.





LATERAL FACE



1. Transverse facial artery and vein
2. Maxillary artery and vein
3. Superficial temporal artery and vein
4. Facial nerve (VII)
5. Posterior auricular artery
6. Retromandibular vein
7. Parotid gland
8. External carotid artery
9. External jugular vein
10. Cervical branches of the facial nerve (VII)
11. Marginal mandibular branches of the facial nerve (VII)
12. Masseter muscle
13. Buccinator muscle
14. Buccal branches of the facial nerve (VII)
15. Parotid duct
16. Zygomatic branches of the facial nerve (VII)
17. Temporal branches of the facial nerve (VII)

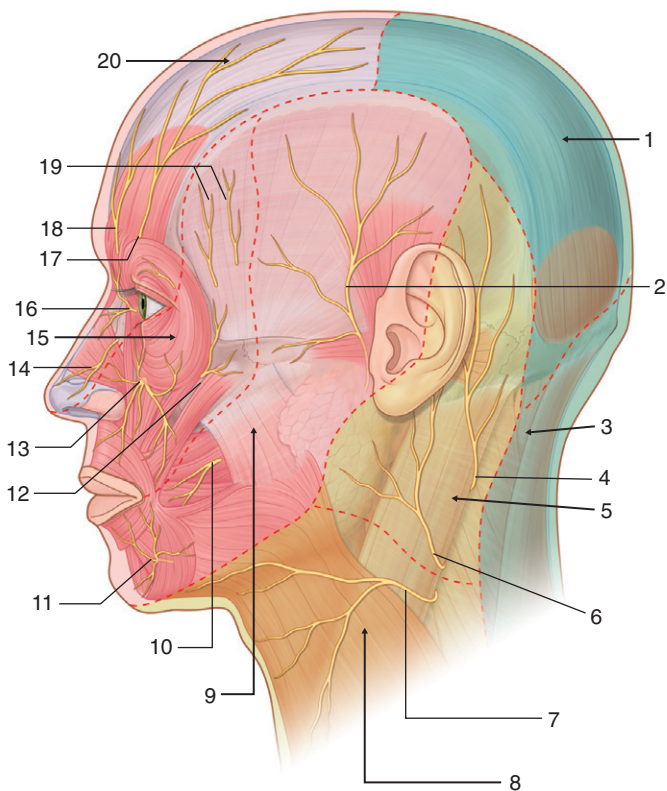
IN THE CLINIC:

- **The most common tumors of the parotid gland are benign. Their importance is in relation to their anatomic position. The relationship of the tumor to the branches of the facial nerve (VII) must be defined because resection may damage the facial nerve (VII).**

Figure from Gray's Anatomy for Students, 3rd edition, p. 911.



Identify the indicated branches of the trigeminal nerve or the nerve supply to the area indicated in this lateral view of the face and neck.





SENSORY NERVES OF THE HEAD



1. Greater occipital
2. Auriculotemporal
3. Third occipital
4. Lesser occipital
5. Lesser occipital and greater auricular
6. Greater auricular
7. Transverse cervical
8. Transverse cervical
9. Mandibular [V_3]
10. Buccal
11. Mental
12. Zygomaticofacial
13. Infra-orbital
14. External nasal
15. Maxillary [V_2]
16. Infratrochlear
17. Supra-orbital
18. Supratrochlear
19. Zygomaticotemporal
20. Ophthalmic [V_1]

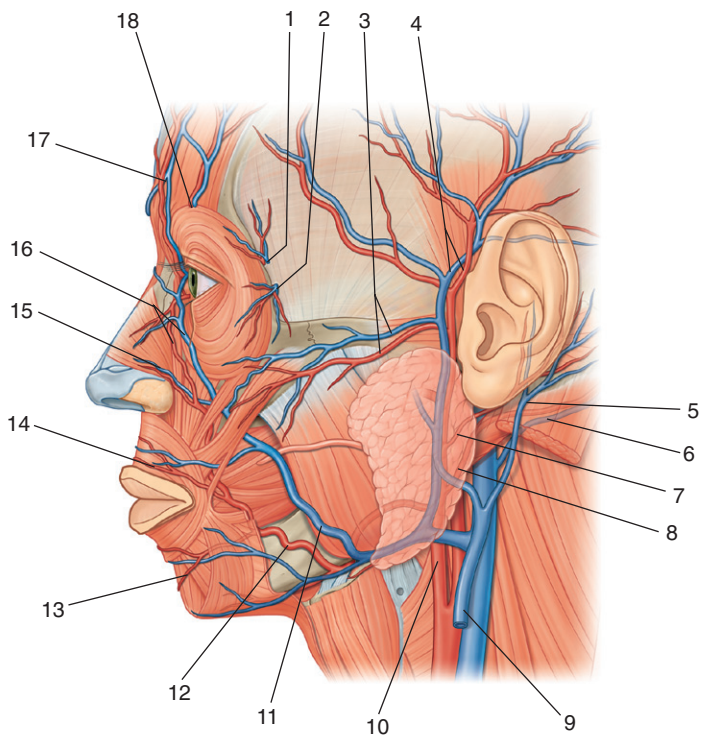
IN THE CLINIC:

- **Trigeminal neuralgia (tic douloureux)** is a complex sensory disorder of the sensory portion of the trigeminal nerve (V). Typically the pain is in the region of the mandibular (V_3) and maxillary (V_2) nerves and is of sudden onset, is excruciating, and may be triggered by touching a sensitive region of skin.

Figure from Gray's Anatomy for Students, 3rd edition, p. 915.



Identify the indicated arteries and veins in this lateral view of the face.





VESSELS OF THE LATERAL FACE



1. Zygomaticotemporal artery and vein
2. Zygomaticofacial artery and vein
3. Transverse facial artery and vein
4. Superficial temporal artery and vein
5. Posterior auricular vein
6. Occipital vein
7. Posterior auricular artery
8. Occipital artery
9. External jugular vein
10. External carotid artery
11. Facial vein
12. Facial artery
13. Inferior labial artery and vein
14. Superior labial artery and vein
15. Lateral nasal artery and vein
16. Angular artery and vein
17. Supratrochlear artery and vein
18. Supra-orbital artery and vein

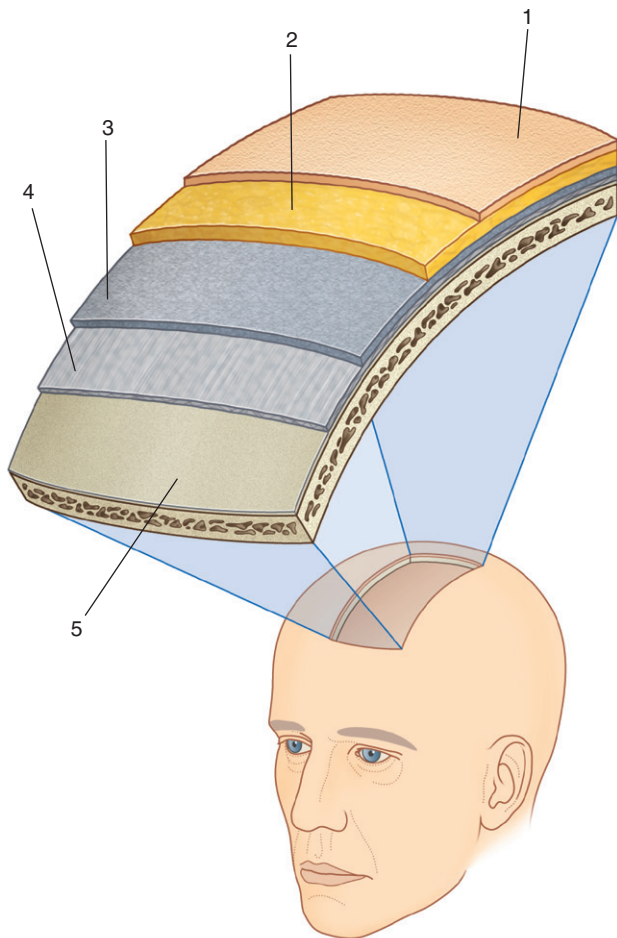
IN THE CLINIC:

- **As it crosses the face, the facial vein has numerous connections with venous channels passing into deeper regions of the head. Near the medial corner of the orbit it communicates with ophthalmic veins. In the area of the cheek it communicates with veins passing into the infra-orbital foramen. It also communicates with veins passing into deeper regions of the face. Because of these possible connections, infection of the face, primarily above the mouth, should be handled with great care to prevent the spread of infections in an intracranial direction.**

Figure from Gray's Anatomy for Students, 3rd edition, p. 917.



Identify the indicated layers of the scalp.





SCALP



1. Skin
2. Dense connective tissue
3. Aponeurotic layer
4. Loose connective tissue
5. Pericranium

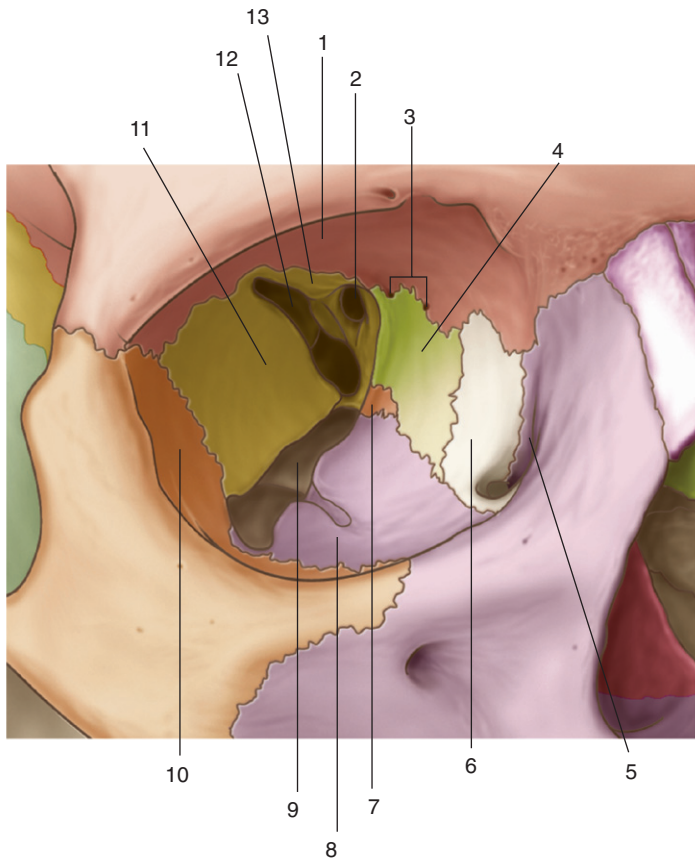
IN THE CLINIC:

- **The first three layers of the scalp form a single unit. This unit is sometimes referred to as the scalp proper and is the tissue torn away during serious scalping injuries.**
- **When the scalp is cut, the dense connective tissue surrounding the vessels tends to hold the cut vessels open. This results in profuse bleeding.**
- **Because of the consistency of the loose connective tissue, infections tend to localize and spread through this layer.**

Figure from Gray's Anatomy for Students, 3rd edition, p. 922.



Identify the indicated bones and openings of the orbit.





ORBIT: BONES

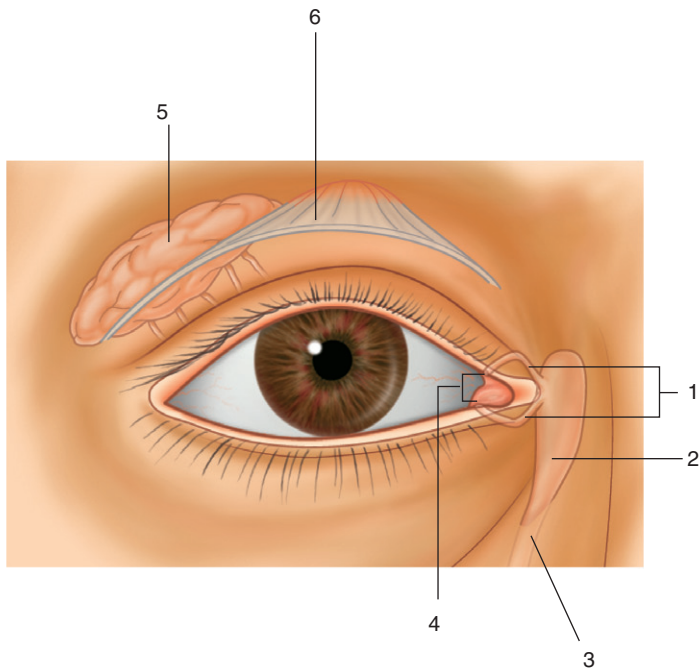


1. Frontal bone
2. Optic canal
3. Ethmoidal foramina
4. Ethmoid bone
5. Lacrimal groove
6. Lacrimal bone
7. Palatine bone
8. Maxilla
9. Inferior orbital fissure
10. Zygomatic bone
11. Greater wing of sphenoid
12. Superior orbital fissure
13. Lesser wing of sphenoid

Figure from Gray's Anatomy for Students, 3rd edition, p. 927.



Identify the indicated parts of the lacrimal apparatus and the related structures.





LACRIMAL APPARATUS

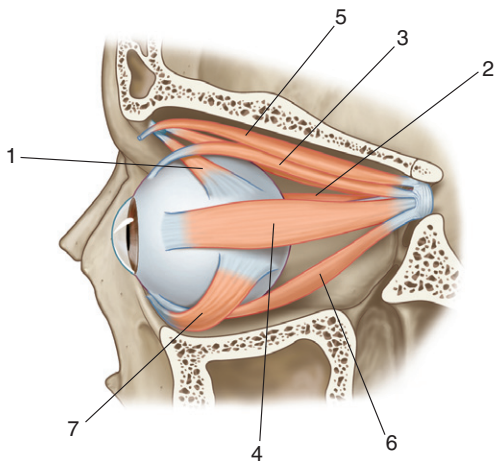
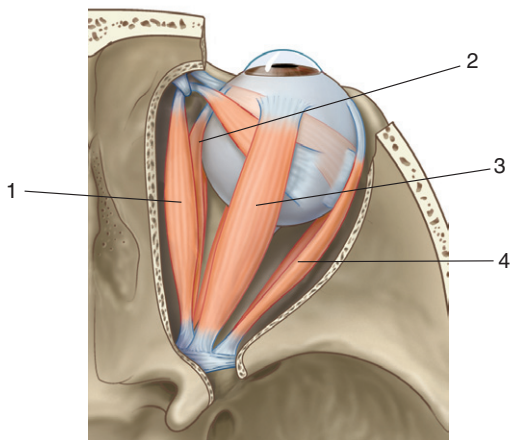


1. Lacrimal canaliculi
2. Lacrimal sac
3. Nasolacrimal duct
4. Puncta
5. Lacrimal gland
6. Tendon of levator palpebrae superioris muscle

Figure from Gray's Anatomy for Students, 3rd edition, p. 932.



Identify the indicated extra-ocular muscles.





ORBIT: EXTRA-OCULAR MUSCLES



1. Superior oblique
2. Medial rectus
3. Superior rectus
4. Lateral rectus
5. Levator palpebrae superioris
6. Inferior rectus
7. Inferior oblique

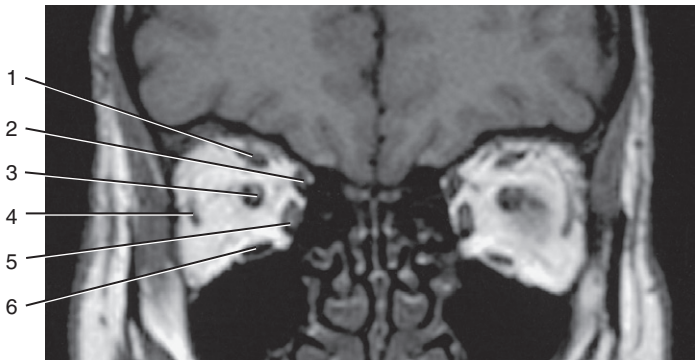
IN THE CLINIC:

- To isolate the function of and test the superior and inferior rectus muscles, a patient is asked to track a physician's finger laterally and then either upward (superior rectus) or downward (inferior rectus).
- To isolate the function of and test the medial and lateral rectus muscles, a patient is asked to track a physician's finger medially and laterally, respectively, in the horizontal plane.
- To isolate the function of and test the superior oblique, a patient is asked to track a physician's finger medially and then downward.
- To isolate the function of and test the inferior oblique, a patient is asked to track a physician's finger medially and then upward.

Figure from Gray's Anatomy for Students, 3rd edition, p. 938.



Identify the indicated structures.





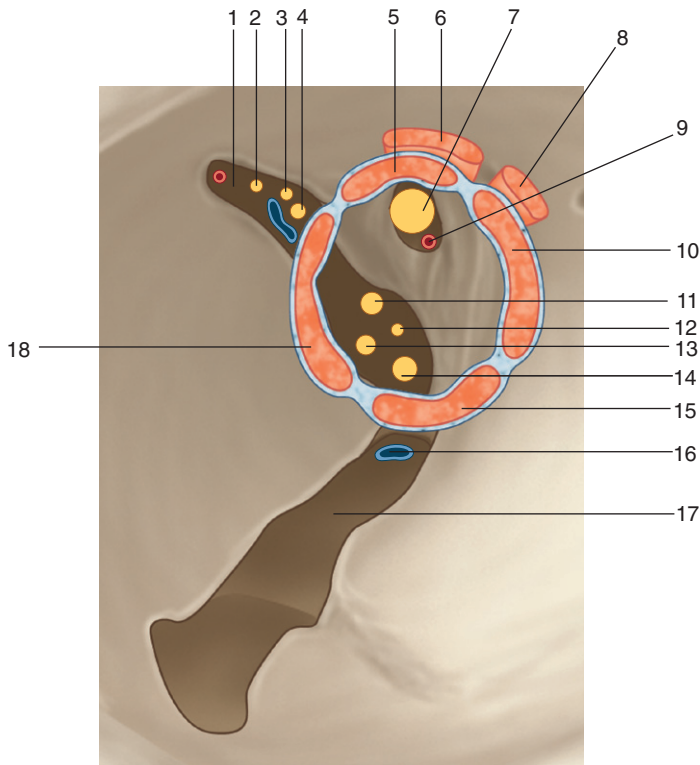
MRI: MUSCLES OF THE EYEBALL



1. Superior rectus
2. Superior oblique
3. Optic nerve
4. Lateral rectus
5. Medial rectus
6. Inferior rectus

Figure from Gray's Basic Anatomy, p. 473.

Identify the indicated structures.





SUPERIOR ORBITAL FISSURE AND OPTIC CANAL

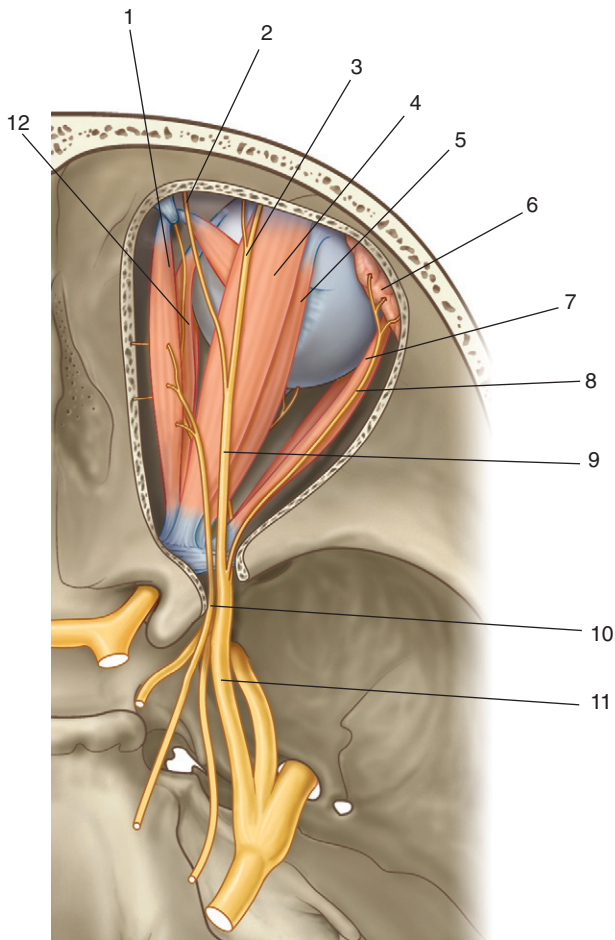


1. Superior orbital fissure
2. Lacrimal nerve
3. Frontal nerve
4. Trochlear nerve (IV)
5. Superior rectus
6. Levator palpebrae superioris
7. Optic nerve (II)
8. Superior oblique
9. Ophthalmic artery
10. Medial rectus
11. Superior division of oculomotor nerve (III)
12. Nasociliary nerve
13. Abducent nerve (VI)
14. Inferior division of oculomotor nerve (III)
15. Inferior rectus
16. Inferior ophthalmic vein
17. Inferior orbital fissure
18. Lateral rectus

Figure from Gray's Anatomy for Students, 3rd edition, p. 939.



Identify the indicated structures.





ORBIT: SUPERFICIAL NERVES



1. Superior oblique muscle
2. Supratrochlear nerve
3. Supra-orbital nerve
4. Levator palpebrae superioris muscle
5. Superior rectus muscle
6. Lacrimal gland
7. Lateral rectus muscle
8. Lacrimal nerve
9. Frontal nerve
10. Trochlear nerve (IV)
11. Ophthalmic nerve (V_1)
12. Medial rectus muscle

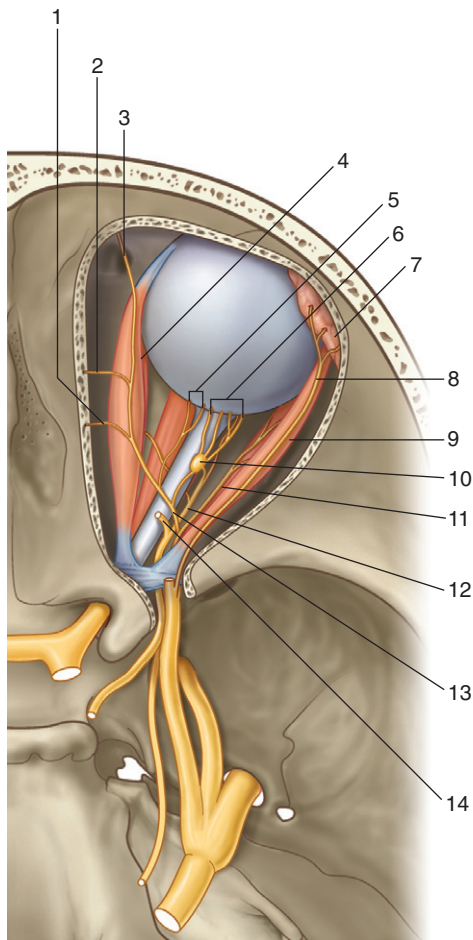
IN THE CLINIC:

- **Loss of innervation of the orbicularis oculi by the facial nerve (VII) causes an inability to close the eyelids tightly, and the lower eyelid droops away, resulting in a spillage of tears.**
- **Loss of innervation of the levator palpebrae superioris by the oculomotor nerve (III) causes an inability to open the superior eyelid voluntarily, producing a complete ptosis.**
- **Loss of innervation of the superior tarsal muscle by sympathetic fibers causes a constant partial ptosis.**

Figure from Gray's Anatomy for Students, 3rd edition, p. 945.



Identify the indicated structures.





ORBIT: DEEP NERVES

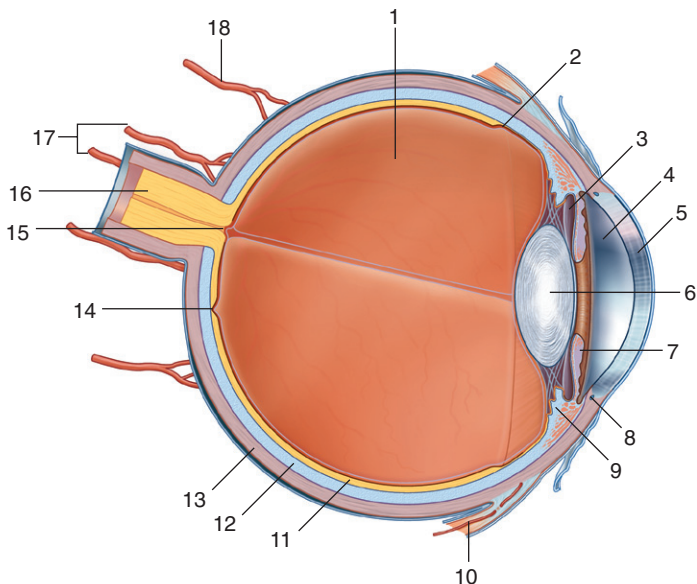


1. Posterior ethmoidal nerve
2. Anterior ethmoidal nerve
3. Infratrochlear nerve
4. Medial rectus muscle
5. Long ciliary nerves
6. Short ciliary nerves
7. Lacrimal gland
8. Lacrimal nerve (from [V₁])
9. Lateral rectus
10. Ciliary ganglion
11. Abducent nerve (VI)
12. Inferior branch of the oculomotor nerve (III)
13. Nasociliary nerve (from [V₁])
14. Superior branch of the oculomotor nerve [III]

Figure from Gray's Anatomy for Students, 3rd edition, p. 945.



Identify the indicated structures related to the eyeball.





EYEBALL



1. Postremal (vitreous) chamber
2. Ora serrata
3. Posterior chamber
4. Anterior chamber
5. Cornea
6. Lens
7. Iris
8. Scleral venous sinus
9. Ciliary body
10. Anterior ciliary artery
11. Retina
12. Choroid
13. Sclera
14. Fovea centralis
15. Optic disc
16. Optic nerve [II]
17. Short posterior ciliary arteries
18. Long posterior ciliary artery

IN THE CLINIC:

- **Intraocular pressure will rise if the normal cycle of aqueous humor fluid production and absorption is disturbed so that the amount of fluid increases. This condition is called glaucoma and can lead to a variety of visual problems, including blindness, which results from compression of the retina and its blood supply.**

Figure from Gray's Anatomy for Students, 3rd edition, p. 947.

This anatomical diagram illustrates the human lacrimal drainage system. The lacrimal gland is shown at the top left, with its duct (1) leading to the upper eyelid margin. The duct continues as the canaliculus (2) and then the lacrimal canaliculus (3). The canaliculus joins the lacrimal sac (4) at the lacrimal caruncle (5). The lacrimal sac is connected to the lacrimal tube (6) and the lacrimal duct (7). The lacrimal duct leads to the lacrimal sac (8) and the lacrimal tube (9). The lacrimal tube leads to the lacrimal sac (10) and the lacrimal tube (11). The lacrimal tube leads to the lacrimal sac (12) and the lacrimal tube (13). The lacrimal tube leads to the lacrimal sac (14) and the lacrimal tube (15). The lacrimal tube leads to the lacrimal sac (16) and the lacrimal tube (17).

- Preganglionic parasympathetic
- - - Postganglionic parasympathetic
- - - Postganglionic sympathetic



VISCERAL EFFERENT (MOTOR) INNERVATION: LACRIMAL GLAND



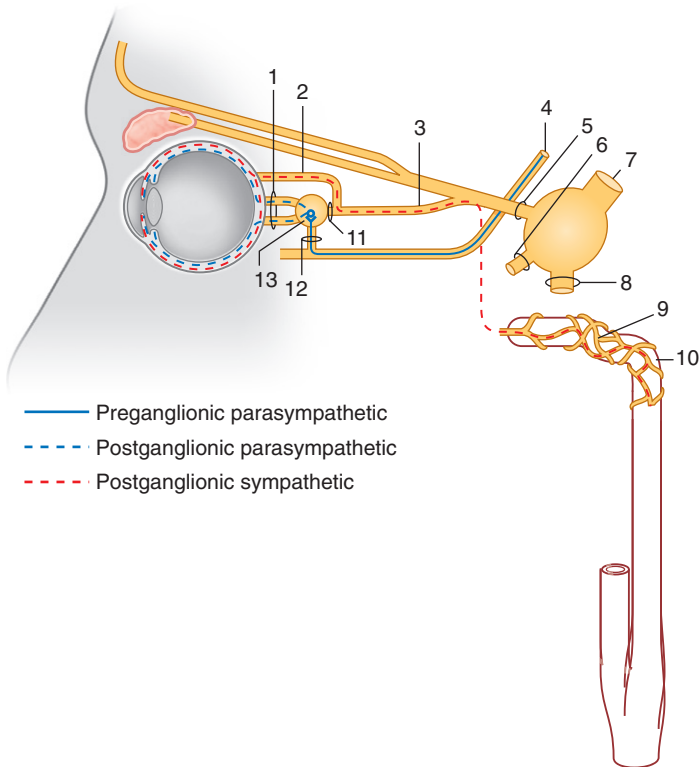
1. Supra-orbital nerve
2. Lacrimal nerve
3. Communicating branch
4. Zygomaticotemporal nerve
5. Ophthalmic nerve (V_1)
6. Maxillary nerve (V_2)
7. Trigeminal nerve (V)
8. Mandibular nerve (V_3)
9. Facial nerve (VII)
10. Zygomatic nerve
11. Pterygopalatine ganglion
12. Nerve of pterygoid canal
13. Deep petrosal nerve
14. Greater petrosal nerve
15. Internal carotid plexus (sympathetic)
16. Internal carotid artery

Figure from Gray's Atlas of Anatomy, 2nd edition, p. 511.

VISCERAL EFFERENT (MOTOR) INNERVATION: EYEBALL (IRIS AND CILIARY BODY)

292

Identify the indicated structures.





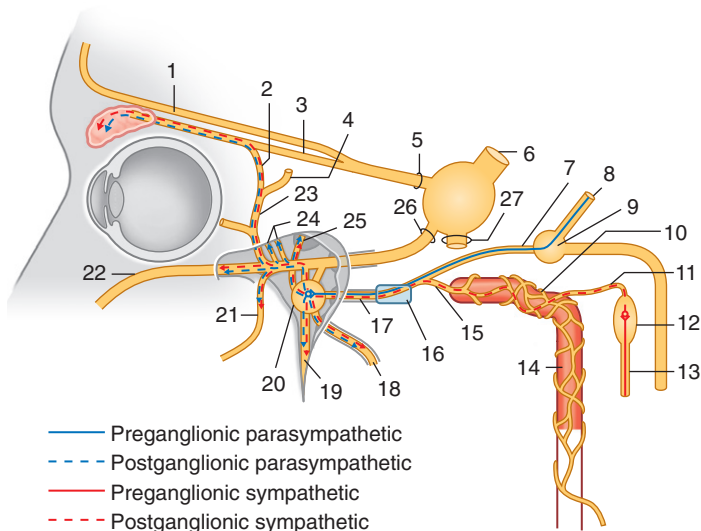
VISCERAL EFFERENT (MOTOR) INNERVATION: EYEBALL (IRIS AND CILIARY BODY)



1. Short ciliary nerves
2. Long ciliary nerves
3. Nasociliary nerve
4. Oculomotor nerve (III)
5. Ophthalmic nerve (V_1)
6. Maxillary nerve (V_2)
7. Trigeminal nerve (V)
8. Mandibular nerve (V_3)
9. Internal carotid plexus (sympathetic)
10. Internal carotid artery
11. Nasociliary root of ciliary ganglion (sensory)
12. Oculomotor root of ciliary ganglion (preganglionic parasympathetic)
13. Ciliary ganglion

Figure from Gray's Atlas of Anatomy, 2nd edition, p. 517.

Identify the indicated structures.





VISCERAL EFFERENT (MOTOR) PATHWAYS THROUGH PTERYGOPALATINE FOSSA

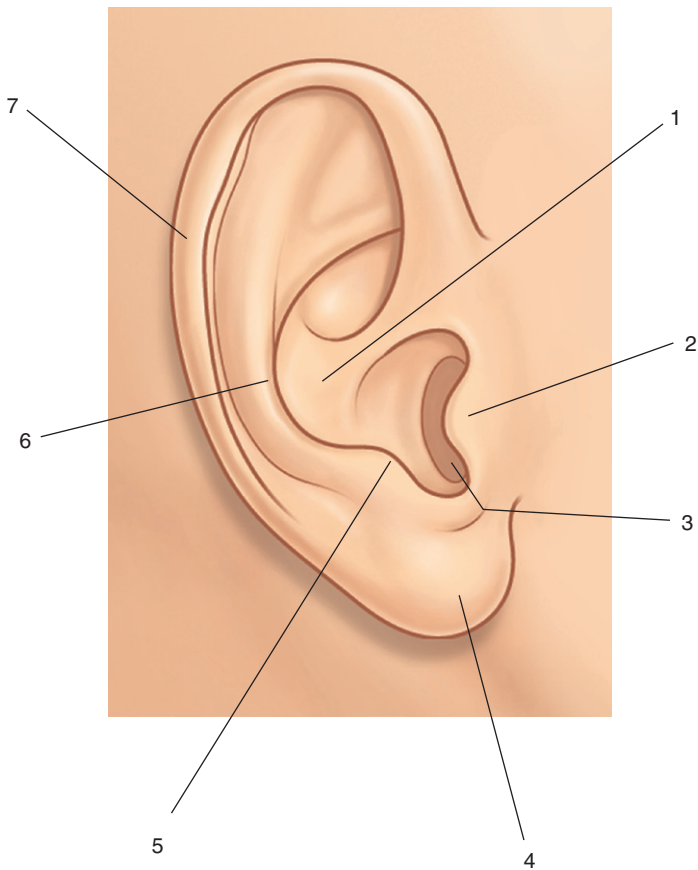


1. Supra-orbital nerve
2. Communicating branch
3. Lacrimal nerve
4. Zygomaticotemporal nerve
5. Ophthalmic nerve (V_1)
6. Trigeminal nerve (V)
7. Greater petrosal nerve
8. Facial nerve (VII)
9. Geniculate ganglion
10. Internal carotid plexus (sympathetic)
11. Internal carotid nerve
12. Superior cervical ganglion
13. Sympathetic trunk
14. Internal carotid artery
15. Deep petrosal nerve
16. Cartilage-filling foramen lacerum
17. Nerve of pterygoid canal
18. Pharyngeal nerve
19. Palatine nerves
20. Pterygopalatine ganglion
21. Posterior superior alveolar nerve
22. Infra-orbital nerve
23. Zygomatic nerve
24. Orbital branches
25. Nasal nerves
26. Maxillary nerve (V_2)
27. Mandibular nerve (V_3)

Figure from Gray's Atlas of Anatomy, 2nd edition, p. 535.



Identify the indicated parts of the external ear.





EXTERNAL EAR



1. Concha
2. Tragus
3. External acoustic meatus
4. Lobule
5. Antitragus
6. Antihelix
7. Helix

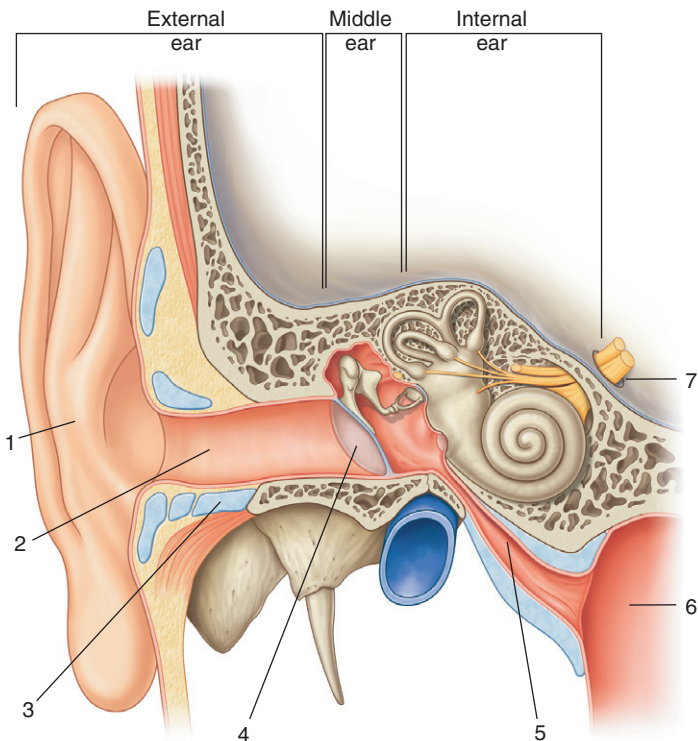
IN THE CLINIC:

- **The external acoustic meatus does not follow a straight course. From the external opening it passes upward in an anterior direction and then turns slightly posteriorly, still passing in an upward direction, and finally turns again in an anterior direction with a slight descent. For examination purposes, observation of the external acoustic meatus and tympanic membrane can be improved by pulling the ear superiorly, posteriorly, and slightly laterally.**

Figure from Gray's Anatomy for Students, 3rd edition, p. 954.



Identify the indicated parts of the external, middle, and internal ear.





EXTERNAL, MIDDLE, AND INTERNAL EAR



1. Auricle
2. External acoustic meatus
3. Cartilage
4. Tympanic membrane
5. Pharyngotympanic tube
6. Pharynx
7. Internal acoustic meatus

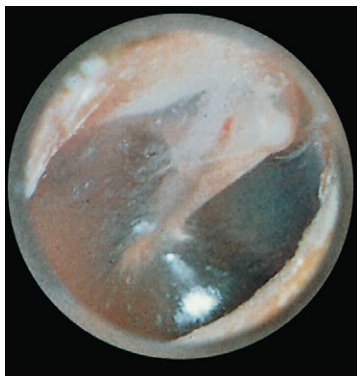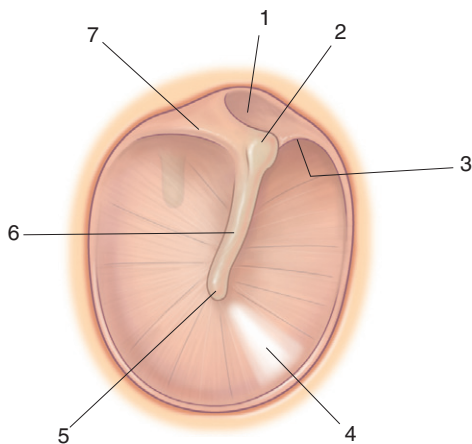
IN THE CLINIC:

- The ear comprises three components: the external, middle, and internal ear. The external ear is easily examined. The external acoustic meatus and the tympanic membrane require otoscopic examination. An otoscope is a device through which light can be shone and the image magnified. The middle ear is examined by computed tomography (CT) and magnetic resonance imaging (MRI) to visualize the malleus, incus, and stapes. The relationship of these bones to the middle ear cavity is determined and any masses identified. The internal ear is also assessed by CT and MRI.

Figure from Gray's Anatomy for Students, 3rd edition, p. 953.



*Is this image from the left or right side of the body?
Identify the indicated parts of the
tympanic membrane.*





TYMPANIC MEMBRANE



This image is from the right side of the body.

1. Pars flaccida
2. Lateral process of malleus
3. Anterior malleolar fold
4. Cone of light
5. Umbo
6. Handle of malleus
7. Posterior malleolar fold

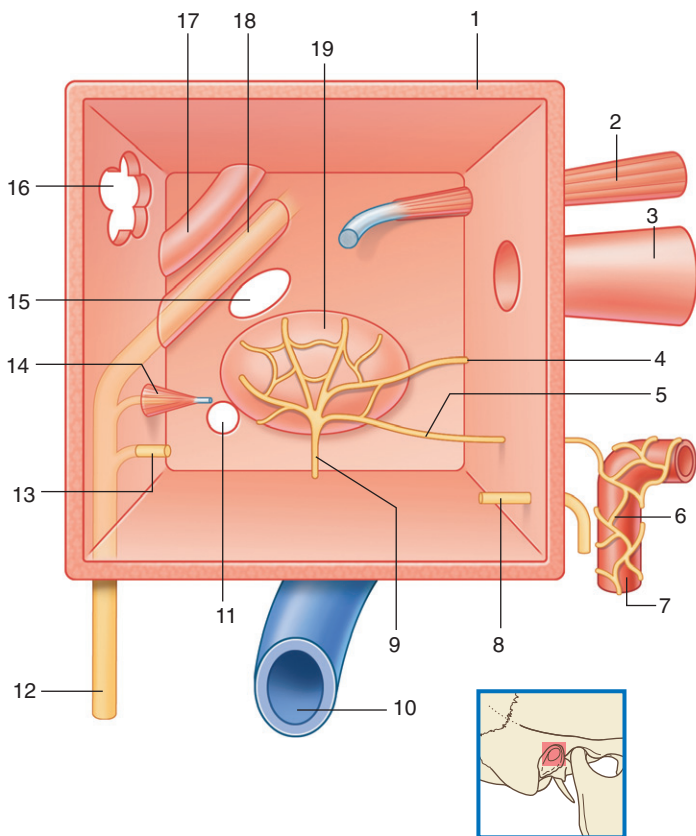
IN THE CLINIC:

- The normal tympanic membrane is relatively translucent and has a gray-red tinge. The tip of the handle of the malleus is visible near the center of the membrane. Extending from this point is a cone of light at the 5 o'clock position on the right side and the 7 o'clock position on the left side.

Figure from Gray's Anatomy for Students, 3rd edition, p. 956.



Identify the indicated structures related to the middle ear.





MIDDLE EAR: SCHEMATIC VIEW



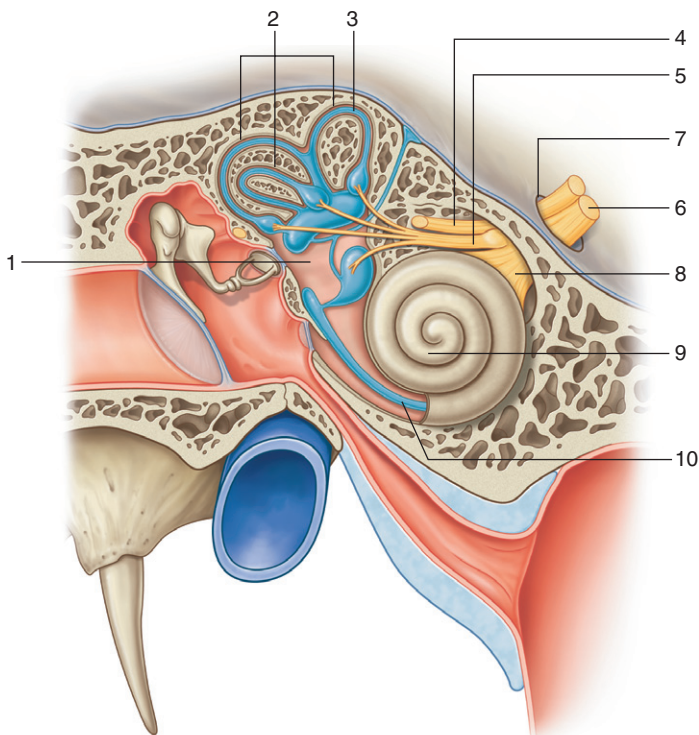
1. Tegmen tympani
2. Tensor tympani muscle
3. Pharyngotympanic tube
4. Lesser petrosal nerve
5. Branch from internal carotid plexus
6. Internal carotid plexus (sympathetic)
7. Internal carotid artery
8. Chorda tympani nerve
9. Tympanic branch of the glossopharyngeal nerve [IX]
10. Internal jugular vein
11. Round window
12. Facial nerve [VII]
13. Chorda tympani nerve
14. Pyramidal eminence (encloses stapedius muscle)
15. Oval window
16. Aditus to mastoid antrum
17. Prominence of lateral semicircular canal
18. Prominence of facial canal
19. Promontory

IN THE CLINIC:

- **Otitis media (infection of the middle ear) is common and can usually be treated by antibiotics. If the infection persists, the chronic inflammatory change may damage the ossicular chain and other structures within the middle ear to produce deafness.**

Figure from Gray's Anatomy for Students, 3rd edition, p. 959.

Identify the indicated structures related to the internal ear.





INTERNAL EAR



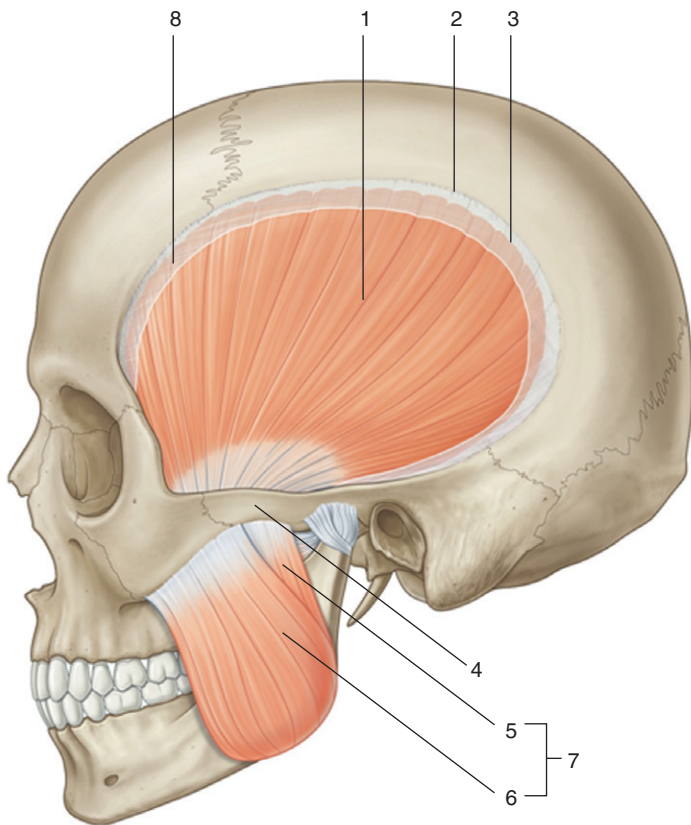
1. Vestibule
2. Semicircular canals
3. Semicircular duct
4. Facial nerve [VII]
5. Vestibular nerve
6. Vestibulocochlear nerve [VIII]
7. Internal acoustic meatus
8. Cochlear nerve
9. Cochlea
10. Cochlear duct

IN THE CLINIC:

- **A sound wave enters the external acoustic meatus and strikes the tympanic membrane, moving it medially. The handle of the malleus is attached to this membrane, and it also moves medially. This moves the head of the malleus laterally. Because the heads of the malleus and incus articulate, the head of the incus also moves laterally. This pushes the long process of the incus medially. Because the long process of the incus articulates with the stapes, the stapes also moves medially. Because the base of the stapes is attached to the oval window, the oval window is moved medially. This action completes the transfer of a large-amplitude, low-force, airborne wave that vibrates the tympanic membrane into a small-amplitude, high-force vibration of the oval window, which generates a wave in the fluid-filled scala vestibuli of the cochlea.**

Figure from Gray's Anatomy for Students, 3rd edition, p. 965.

Identify the indicated muscles.





INFRATEMPORAL REGION: MUSCLES OF MASTICATION

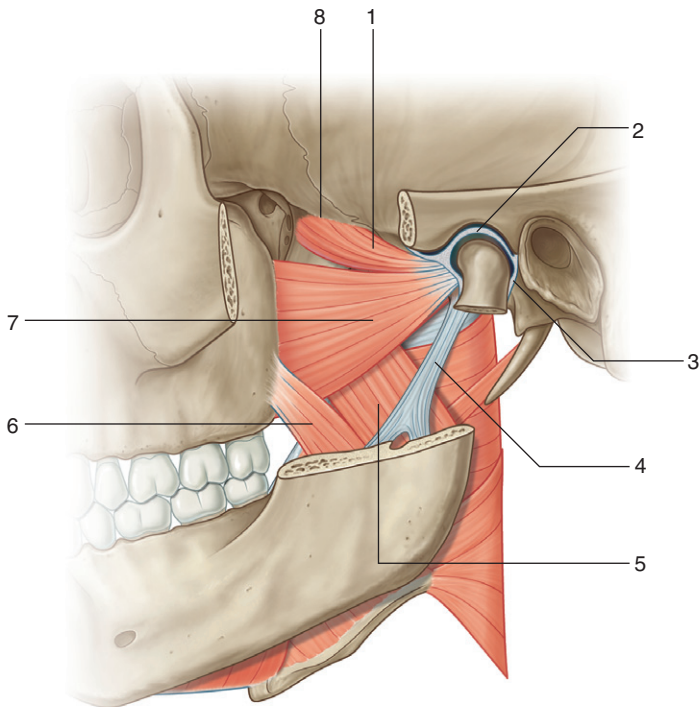


1. Temporalis muscle
2. Superior temporal line
3. Inferior temporal line
4. Zygomatic arch
5. Deep part (of masseter muscle)
6. Superficial part (of masseter muscle)
7. Masseter muscle
8. Cut temporal fascia

Figure from Gray's Atlas of Anatomy, 2nd edition, p. 526.



Identify the indicated structures.





INFRATEMPORAL REGION: MUSCLES



1. Upper head of lateral pterygoid muscle
2. Articular disc (of temporomandibular joint)
3. Capsule (of temporomandibular joint)
4. Sphenomandibular ligament
5. Deep head medial pterygoid muscle
6. Superficial head medial pterygoid muscle
7. Lower head lateral pterygoid muscle
8. Infratemporal crest

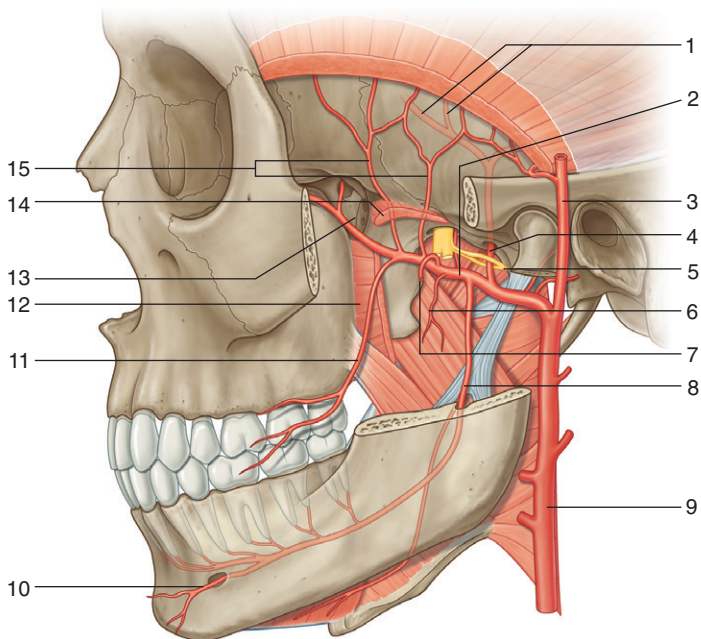
IN THE CLINIC:

- The lateral pterygoid facilitates opening the mouth by pulling the head of the mandible forward onto the articular tubercle of the temporal bone. In a lesion to V_3 on one side, the anterior aspect of the mandible points to the side of the lesion when the mouth is opened.

Figure from Gray's Anatomy for Students, 3rd edition, p. 983.



Identify the indicated arteries and related structures.





INFRATEMPORAL REGION: ARTERIES



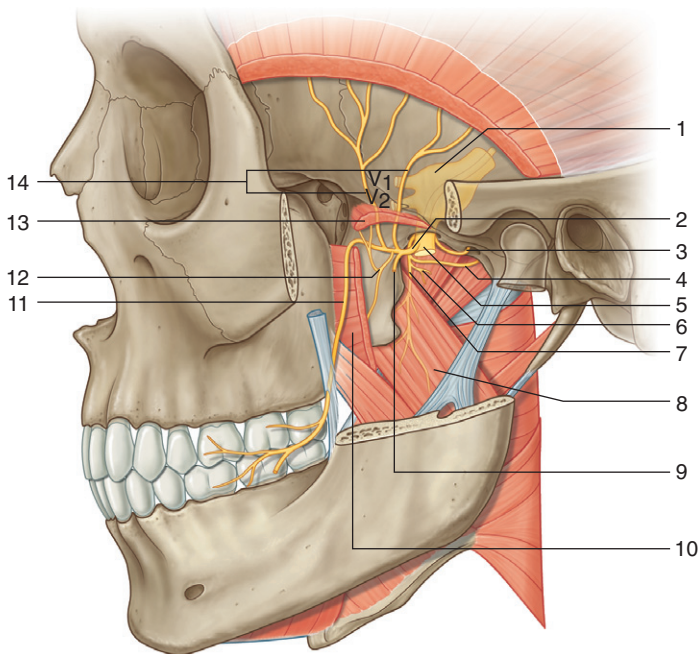
1. Branches of middle meningeal artery in cranial cavity
2. Maxillary artery
3. Superficial temporal artery
4. Middle meningeal artery
5. Auriculotemporal nerve
6. Pterygoid artery
7. Artery to masseter (cut)
8. Inferior alveolar artery
9. External carotid
10. Mental artery
11. Buccal artery
12. Lower head of lateral pterygoid (cut) muscle
13. Pterygopalatine fossa
14. Upper head of lateral pterygoid (cut) muscle
15. Deep temporal arteries

IN THE CLINIC:

- **The middle meningeal artery is a branch of the maxillary artery in the infratemporal fossa. Damage to the middle meningeal artery in the cranial cavity can lead to an extradural (epidural) hematoma.**
- **In addition to supplying structures in the infratemporal and temporal regions, the maxillary artery supplies all the upper teeth, all the lower teeth, the hard and soft palates, and much of the nasal cavity.**

Figure from Gray's Anatomy for Students, 3rd edition, p. 985.

Identify the indicated nerves and related structures.





INFRATEMPORAL REGION: NERVES, PART 1



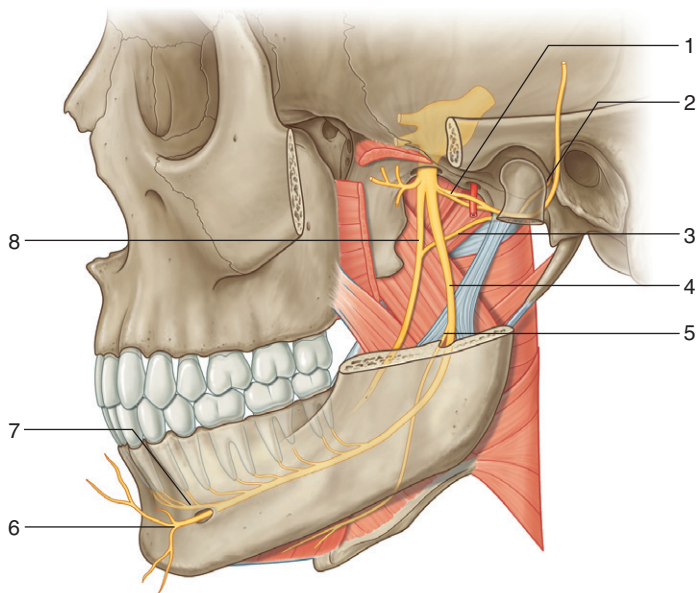
1. Trigeminal ganglion
2. Anterior trunk (of V_3)
3. Meningeal nerve
4. Branch to tensor tympani
5. Posterior trunk (of V_3)
6. Branch to tensor veli palatini
7. Nerve to medial pterygoid
8. Deep head medial pterygoid
9. Masseteric nerve
10. Lower head lateral pterygoid (cut)
11. Buccal nerve
12. Nerve to lateral pterygoid
13. Upper head lateral pterygoid (cut)
14. Deep temporal nerves

IN THE CLINIC:

- **Except for the buccal nerve, which is sensory, the branches of the anterior trunk of the mandibular nerve are motor and supply the muscles of mastication as well as the tensor tympani and tensor veli palatini. The buccal nerve often is anesthetized during dental procedures because it innervates gingiva on the buccal side of the lower molar teeth.**

Figure from Gray's Anatomy for Students, 3rd edition, p. 984.

Identify the indicated nerves and related structures.





INFRATEMPORAL REGION: NERVES, PART 2



1. Auriculotemporal nerve
2. Petrotympanic fissure
3. Chorda tympani nerve
4. Inferior alveolar nerve
5. Nerve to mylohyoid
6. Mental nerve
7. Incisive nerve
8. Lingual nerve

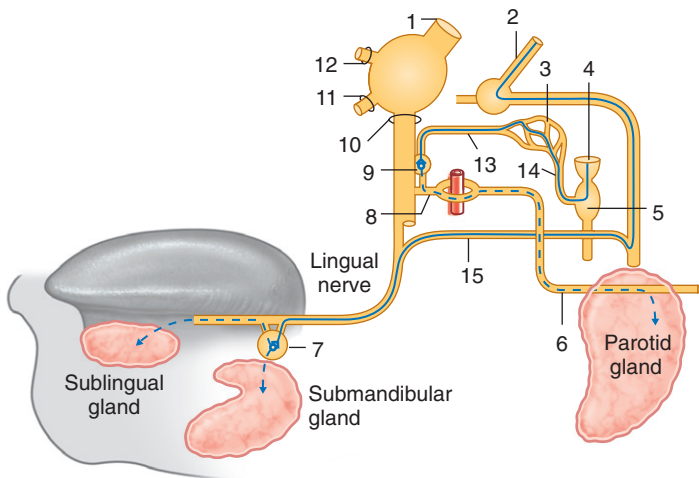
IN THE CLINIC:

- Except for the nerve to the mylohyoid muscle, which is motor and originates from the inferior alveolar nerve, branches of the posterior trunk of the mandibular nerve are general sensory.
- The inferior alveolar nerve is sensory to all lower teeth and to gingiva associated with the buccal side of the incisor, canine, and premolars. The buccal gingiva of the molars is innervated by the buccal nerve. The lingual nerve is, in general, sensory to the tongue and the lingual gingiva of all the lower teeth. Anesthesia of the lower teeth and associated gingiva can be achieved by injecting anesthetic into the infratemporal fossa lateral to the sphenomandibular ligament. This anesthetizes the inferior alveolar and lingual nerves. A separate injection is used to anesthetize the buccal nerve.

Figure from Gray's Anatomy for Students, 3rd edition, p. 985.

Identify the indicated nerves and ganglia.

- Preganglionic parasympathetic
- - - Postganglionic parasympathetic





PARASYMPATHETIC INNERVATION OF SALIVARY GLANDS



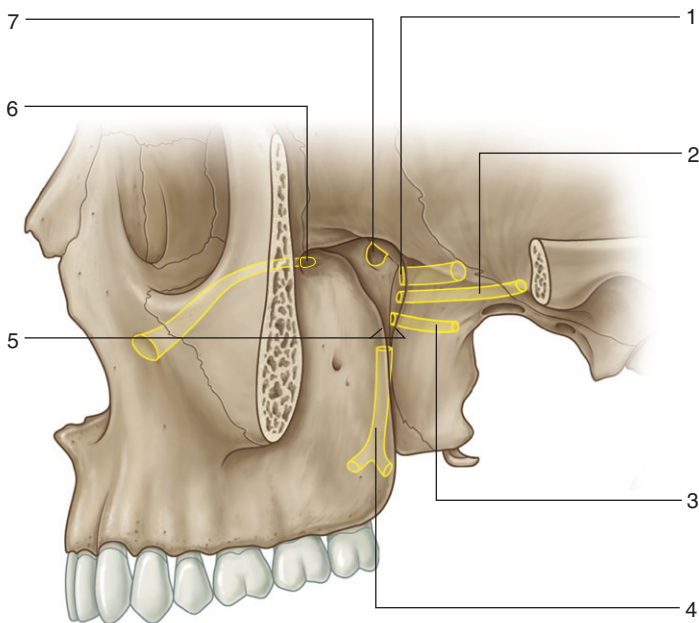
- | | |
|--------------------------------|--------------------------------|
| 1. Trigeminal nerve (V) | 9. Otic ganglion |
| 2. Facial nerve (VII) | 10. Mandibular nerve (V_3) |
| 3. Tympanic plexus | 11. Maxillary nerve (V_2) |
| 4. Glossopharyngeal nerve (IX) | 12. Ophthalmic nerve (V_1) |
| 5. Inferior ganglion of IX | 13. Lesser petrosal nerve |
| 6. Auriculotemporal nerve | 14. Tympanic nerve |
| 7. Submandibular ganglion | 15. Chorda tympani nerve |
| 8. Auriculotemporal nerve | |

IN THE CLINIC:

- The chorda tympani nerve carries taste from the oral part (anterior two thirds) of the tongue and parasympathetic innervation to all glands below the level of the oral fissure. The preganglionic parasympathetic fibers synapse in the submandibular ganglion. A lesion to the lingual nerve distal to the point where the chorda tympani joins it in the infratemporal fossa results in loss of general and special (taste) sensation from the oral part of the tongue and parasympathetic innervation to all glands below the level of the oral fissure. A lesion to the lingual nerve proximal to the point where it is joined by the chorda tympani results in loss only of general sensation from the anterior two thirds of the tongue.
- The lesser petrosal nerve carries preganglionic parasympathetic fibers that originate in cranial nerve IX into the infratemporal fossa, where they synapse in the otic ganglion. Postganglionic fibers are carried in the auriculotemporal nerve of V_3 to the parotid gland. A lesion to the auriculotemporal nerve distal to the otic ganglion results in general sensory loss to the area of distribution of the auriculotemporal nerve and to loss of secretion by the parotid gland.



Identify the indicated foramina, canals, and fissures in the pterygopalatine fossa.





PTERYGOPALATINE FOSSA: GATEWAYS



1. Foramen rotundum (cranial cavity–middle cranial fossa)
2. Pterygoid canal cavity (middle cranial fossa)
3. Palatovaginal canal (nasopharynx)
4. Palatine canal (roof of oral cavity–palate)
5. Pterygomaxillary fissure (infratemporal fossa)
6. Inferior orbital fissure (floor of orbit)
7. Sphenopalatine foramen (nasal cavity)

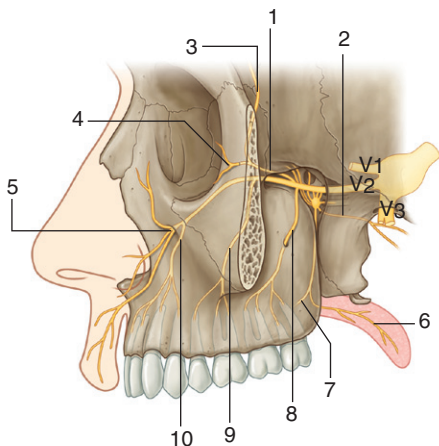
IN THE CLINIC:

- **The pterygopalatine fossa is a key site in the skull. Via its foramina, canals, and fissures, the fossa communicates with the middle cranial fossa, the infratemporal region, the nasal cavity, the oral cavity, the orbit, and the pharynx.**

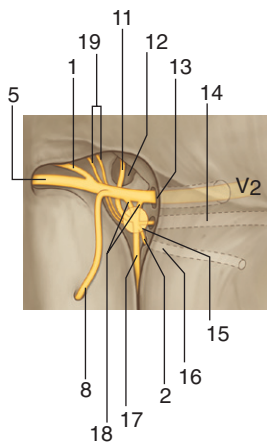
Figure from Gray's Anatomy for Students, 3rd edition, p. 994.



Identify the indicated nerves and ganglion.



A



B



PTERYGOPALATINE FOSSA: NERVES



- | | |
|--------------------------------|------------------------------|
| 1. Zygomatic | 11. Nasal |
| 2. Pharyngeal | 12. Sphenopalatine foramen |
| 3. Zygomaticotemporal | 13. Foramen rotundum |
| 4. Zygomaticofacial | 14. Pterygoid canal |
| 5. Infra-orbital | 15. Pterygopalatine ganglion |
| 6. Lesser palatine | 16. Palatovaginal canal |
| 7. Greater palatine | 17. Palatine |
| 8. Posterior superior alveolar | 18. Ganglionic branches |
| 9. Middle superior alveolar | 19. Orbital branches |
| 10. Anterior superior alveolar | |

IN THE CLINIC:

- The pterygopalatine fossa is the site where many of the branches of V_2 arise and where terminal branches of the maxillary artery originate. In addition, preganglionic parasympathetic fibers from the greater petrosal branch of VII and postganglionic sympathetic fibers in the deep petrosal nerve from the internal carotid plexus enter the fossa together as the nerve of the pterygoid canal. The preganglionic parasympathetic fibers synapse in the pterygopalatine ganglion and then, with the sympathetic fibers, join branches of V_2 .
- For some complex dental procedures, V_2 can be anesthetized by injecting anesthetic directly into the pterygopalatine fossa by passing a needle first through the mandibular notch and then through the infratemporal fossa and pterygomaxillary fissure.
- The greater petrosal nerve of VII carries parasympathetic innervation to all glands above the level of the oral fissure, including the lacrimal gland. Postganglionic parasympathetics are carried into the orbit in the zygomatic nerve and then pass into the zygomaticotemporal branch. Fibers leave the latter branch and course superiorly up the lateral wall of the orbit to join the lacrimal branch of V_1 , which delivers them to the lacrimal gland. Damage to the lateral wall of the orbit can result in loss of lacrimal gland secretion.

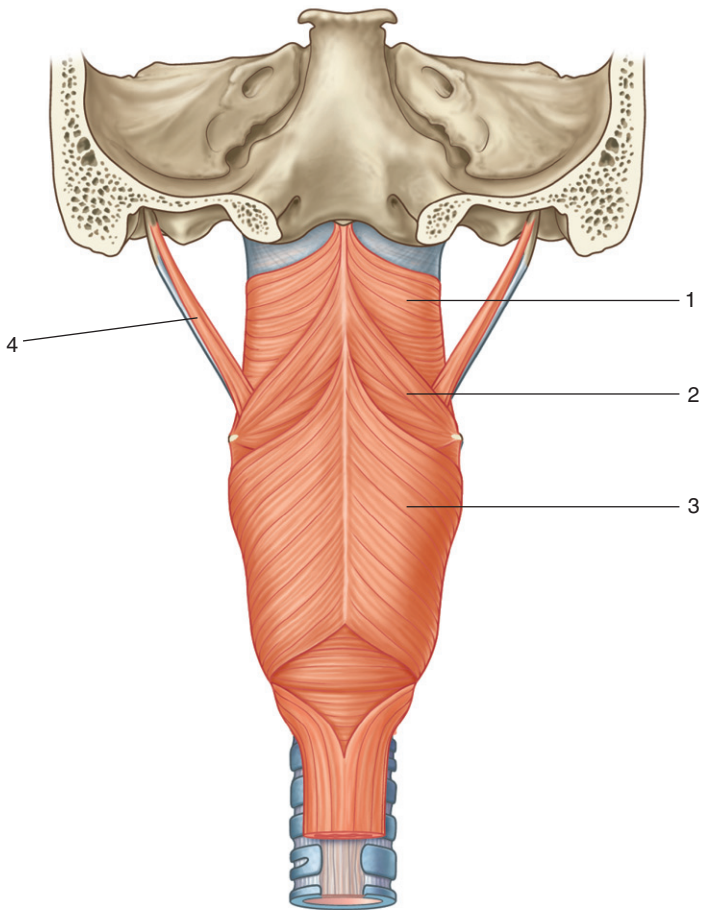
Figure from Gray's Anatomy for Students, 3rd edition, p. 995.

Copyright 2015, Elsevier Inc. All rights reserved.

PHARYNX:
POSTERIOR VIEW OF MUSCLES

307

Identify the indicated muscles.





PHARYNX: POSTERIOR VIEW OF MUSCLES



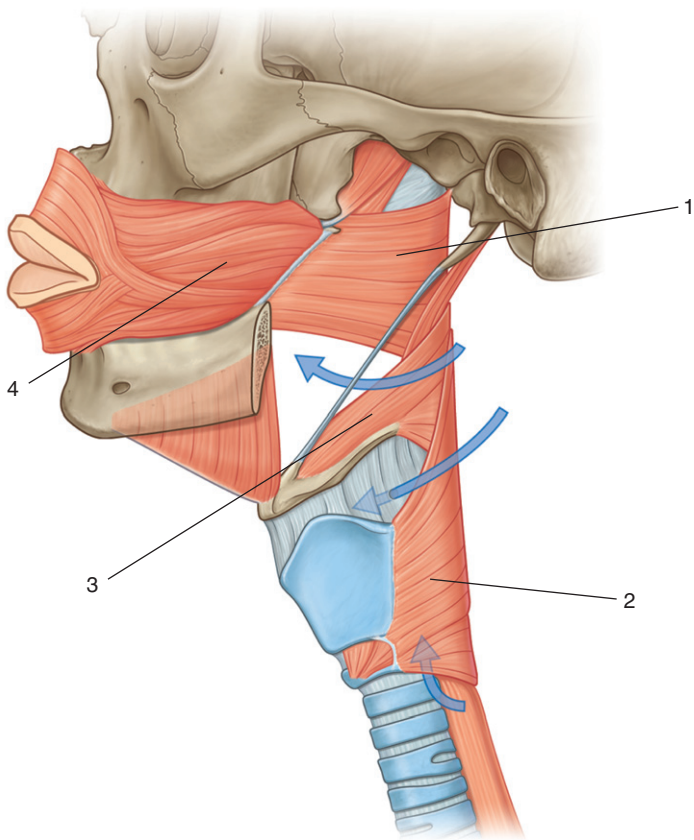
1. Superior constrictor
2. Middle constrictor
3. Inferior constrictor
4. Stylopharyngeus

IN THE CLINIC:

- **Muscles of the pharynx facilitate swallowing.**
- **The pharyngeal wall can be seen through the open mouth.**

Figure from Gray's Anatomy for Students, 3rd edition, p. 1043.

Identify the indicated muscles.





PHARYNX: LATERAL VIEW OF MUSCLES



1. Superior constrictor
2. Inferior constrictor
3. Middle constrictor
4. Buccinator

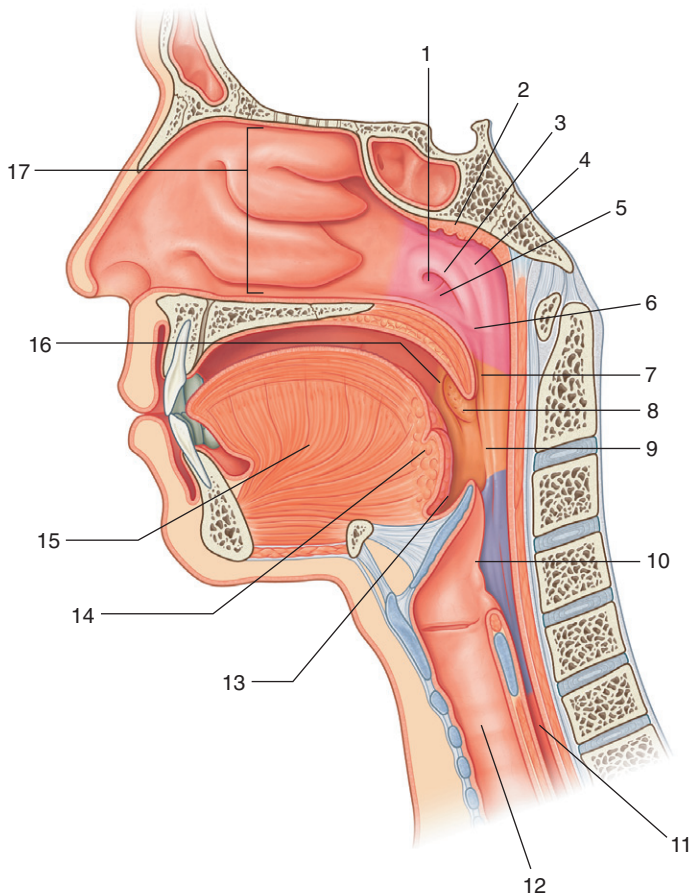
IN THE CLINIC:

- **The buccinator muscle of the cheek (a muscle of facial expression) and the superior constrictor of the pharynx are joined together by the pterygomandibular raphe.**

Figure from Gray's Anatomy for Students, 3rd edition, p. 1046.



Identify the indicated features.





PHARYNX: MIDSAGITTAL SECTION



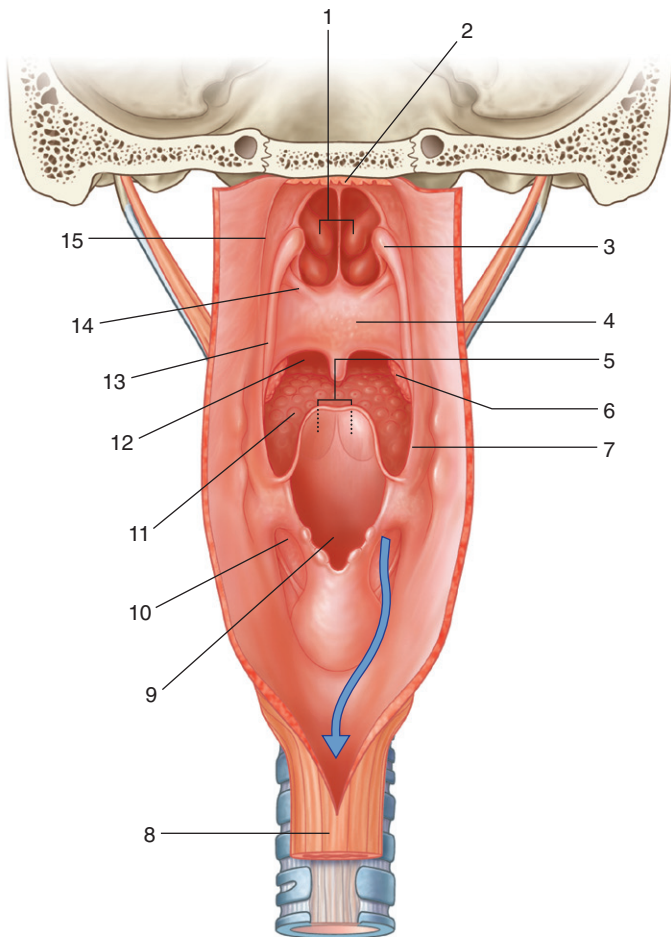
1. Pharyngeal opening of the pharyngotympanic tube
2. Pharyngeal tonsil
3. Torus tubarius
4. Pharyngeal recess
5. Torus levatorius (fold overlying levator veli palatini)
6. Fold overlying palatopharyngeal sphincter
7. Salpingopharyngeal fold
8. Palatine tonsil
9. Palatopharyngeal arch (overlies palatopharyngeus muscle)
10. Laryngeal inlet
11. Esophagus
12. Trachea
13. Vallecula
14. Lingual tonsils
15. Tongue
16. Palatoglossal arch (margin of oropharyngeal isthmus)
17. Nasal cavity

IN THE CLINIC:

- The pharynx interconnects the digestive and respiratory tracts. When intubating a patient, the lower airway is accessed through the oral cavity. A feeding tube can be passed into the nasal cavity, through the pharynx, and into the esophagus.
- In dental procedures, a rubber dam is used to prevent tooth debris from getting into the airway.
- Swollen pharyngeal tonsils (adenoids) can block the upper airway, and as a consequence the patient breathes through the mouth.
- When the pharyngotympanic (eustachian) tube is blocked, a person cannot equalize pressure in the middle ear.

Figure from Gray's Anatomy for Students, 3rd edition, p. 1047.

Identify the indicated features.





PHARYNX: POSTERIOR VIEW, OPENED



1. Choanae
2. Pharyngeal tonsil
3. Torus tubarius
4. Soft palate
5. Valleculae (anterior to epiglottis)
6. Palatine tonsil
7. Palatopharyngeal arch
8. Esophagus
9. Laryngeal inlet
10. Piriform fossa
11. Lingual tonsil
12. Oropharyngeal isthmus
13. Salpingopharyngeal fold
14. Torus levatorius
15. Pharyngeal recesses

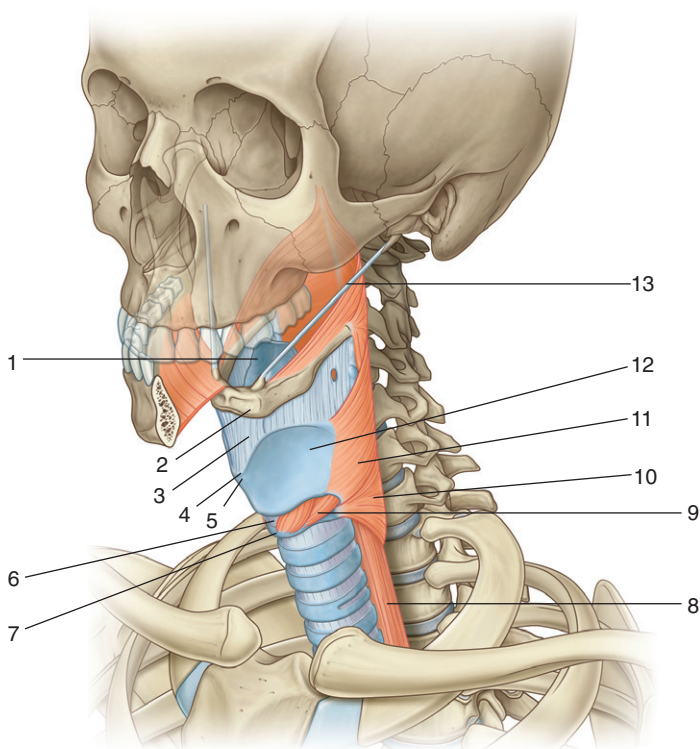
IN THE CLINIC:

- Food and liquid pass from the oral cavity into the pharynx through the oropharyngeal isthmus. The material then passes along the piriform fossae on either side of the larynx and into the esophagus. Debris can lodge in the fossae.

Figure from Gray's Anatomy for Students, 3rd edition, p. 1047.



Identify the indicated features.





LARYNX: OVERVIEW



1. Epiglottis
2. Hyoid bone
3. Thyrohyoid membrane
4. Superior thyroid notch
5. Laryngeal prominence
6. Cricothyroid (cricovocal) membrane
7. Anterior arch of cricoid cartilage
8. Esophagus
9. Cricothyroid muscle
10. Inferior constrictor of pharynx
11. Middle constrictor of pharynx
12. Thyroid cartilage
13. Stylohyoid ligament

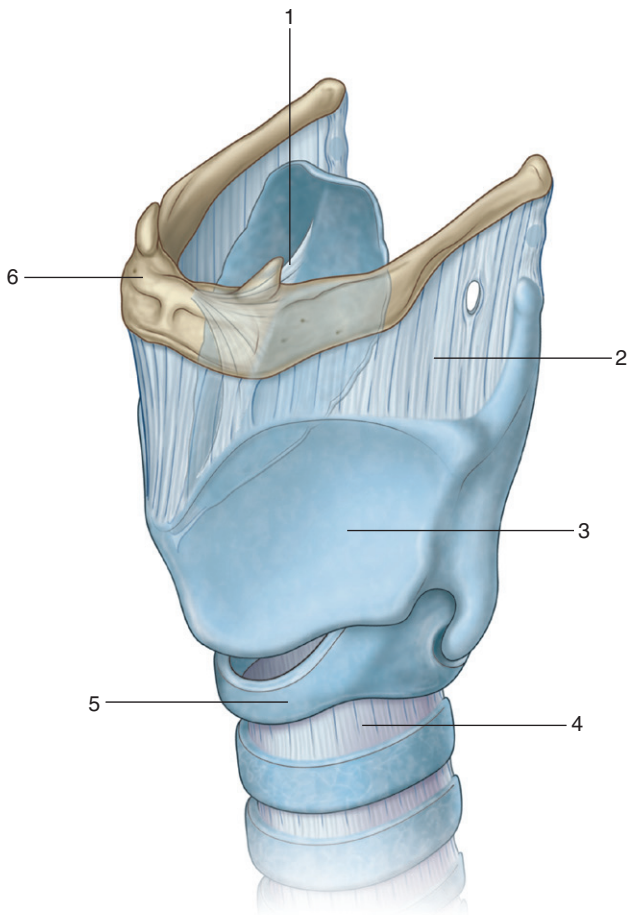
IN THE CLINIC:

- **The hyoid bone, superior thyroid notch, laryngeal prominence (“Adam’s apple”), and anterior arch of the cricoid cartilage are palpable in the neck. The cricothyroid (cricovocal) membrane is palpable in the midline between the thyroid and cricoid cartilages. This membrane can be perforated in emergency procedures to gain access to the airway below the level of the vocal folds of the larynx.**

Figure from Gray’s Anatomy for Students, 3rd edition, p. 845.



Identify the indicated features.





LARYNX: CARTILAGE AND LIGAMENTS

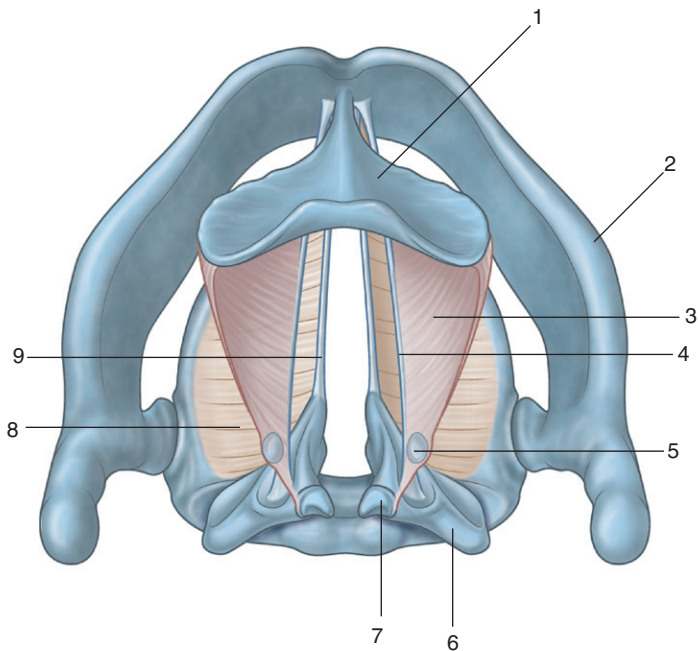


1. Hyo-epiglottic ligament
2. Thyrohyoid membrane
3. Thyroid cartilage
4. Cricotracheal ligament
5. Cricoid cartilage
6. Hyoid bone

Figure from Gray's Anatomy for Students, 3rd edition, p. 1056.

LARYNX:
SUPERIOR VIEW OF VOCAL LIGAMENTS

Identify the indicated features.





LARYNX: SUPERIOR VIEW OF VOCAL LIGAMENTS



1. Epiglottis
2. Thyroid cartilage
3. Quadrangular membrane
4. Vestibular ligament
5. Cuneiform cartilage
6. Arytenoid cartilage
7. Corniculate cartilage
8. Cricothyroid (cricovocal) ligament
9. Vocal ligament

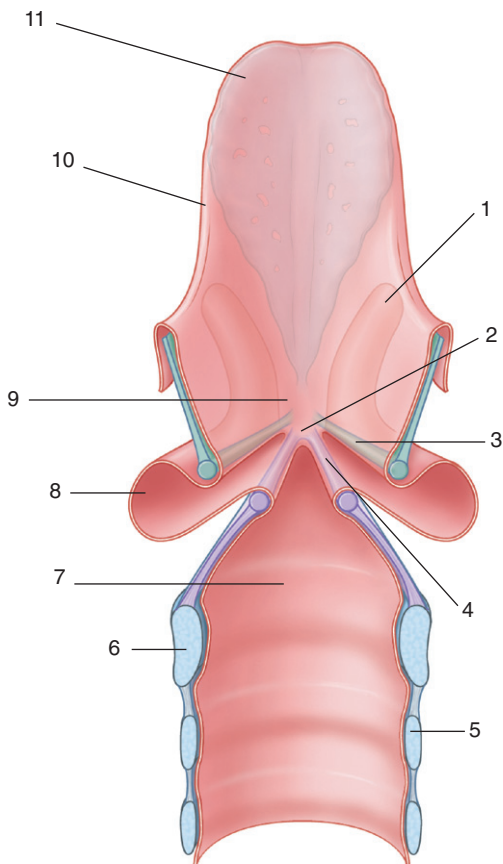
IN THE CLINIC:

- The vocal ligament is the upper, free, thickened margin of the cricothyroid (cricovocal) membrane, and the vestibular ligament is the lower, free, thickened margin of the quadrangular membrane. When viewed from above, the vocal ligaments are more medial in position than are the vestibular ligaments.

Figure from Gray's Anatomy for Students, 3rd edition, p. 1058.



Identify the indicated features on this posterior view of the anterior half of a coronal section through the larynx and associated trachea.





LARYNX: POSTERIOR VIEW



1. Laryngeal sacculle
2. Middle part of laryngeal cavity
3. Vestibular fold (mucosa overlying vestibular ligament)
4. Vocal fold (mucosa overlying vocal ligament)
5. Trachea
6. Cricoid arch
7. Infraglottic space
8. Laryngeal ventricle
9. Vestibule
10. Ary-epiglottic fold
11. Epiglottis

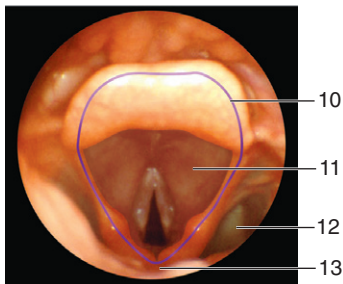
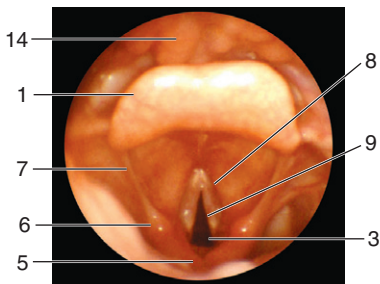
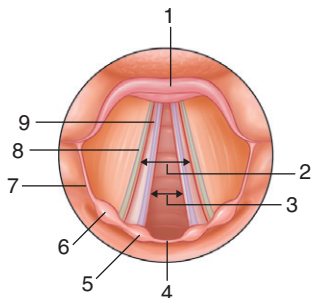
IN THE CLINIC:

- **The vestibular and vocal ligaments are attached anteriorly to the posterior surface of the thyroid cartilage near the midline. Perforation of the cricothyroid (cricovocal) membrane in the midline between the thyroid cartilage and cricoid cartilage allows access to the infraglottic space of the airway below the level of the vocal folds. This would allow a patient to breathe when the airway is blocked above the level of the vocal folds.**

Figure from Gray's Anatomy for Students, 3rd edition, p. 1060.



Identify the indicated features in this laryngoscopic view of the larynx.





LARYNX: LARYNGOSCOPIC IMAGES



1. Epiglottis
2. Rima vestibuli
3. Rima glottidis
4. Interarytenoid fold
5. Corniculate tubercle
6. Cuneiform tubercle
7. Ary-epiglottic fold
8. Vestibular fold
9. Vocal fold
10. Laryngeal inlet
11. Vestibule
12. Piriform recess
13. Laryngopharynx (closed)
14. Tongue

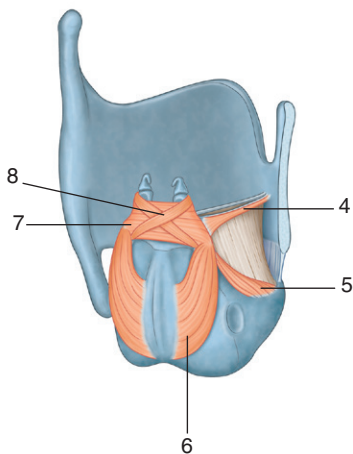
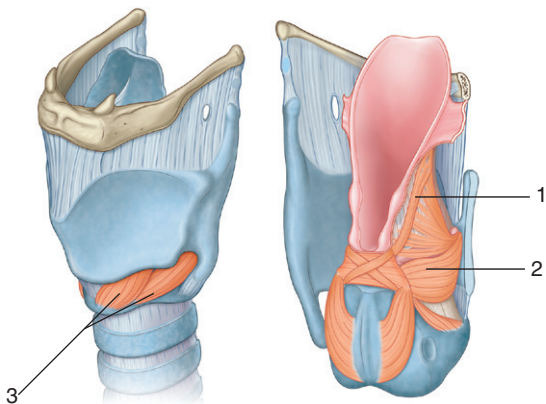
IN THE CLINIC:

- **Small objects or food can accidentally be inhaled into the vestibule of the larynx, where they become lodged and block the airway above the level of the vocal folds. A Heimlich maneuver may dislodge the material. In cases in which material cannot be dislodged or when the airway is blocked for other reasons, a cricothyrotomy (midline perforation of the cricothyroid ligament) can be done to establish an artificial airway.**

Figure from Gray's Anatomy for Students, 3rd edition, p. 1060.



Identify the indicated muscles.





LARYNX: INTRINSIC MUSCLES

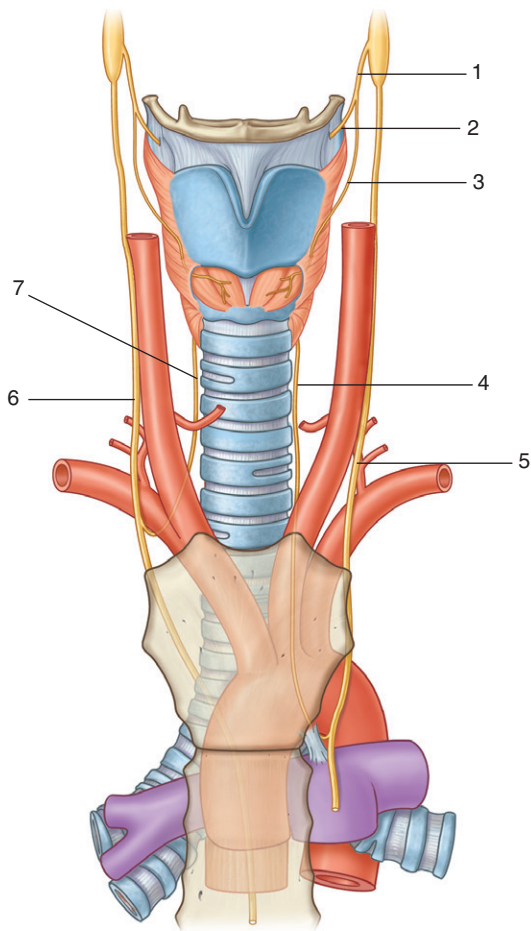


1. Ary-epiglottic muscle
2. Thyro-arytenoid muscle
3. Cricothyroid muscle
4. Vocalis muscle
5. Lateral crico-arytenoid muscle
6. Posterior crico-arytenoid muscle
7. Transverse arytenoid muscle
8. Oblique arytenoid muscle

IN THE CLINIC:

- **Intrinsic muscles of the larynx generally are involved with adjusting the diameter of the airway in the cavity of the larynx or adjusting tension in the vocal folds. Some of the muscles work by adjusting the size and shape of the rima glottidis and rima vestibuli. Others work by adjusting the diameter of the vestibule or the laryngeal inlet. The posterior crico-arytenoid muscles are significant “openers” of the airway. Bilateral loss of function of the intrinsic muscles of the larynx can lead to suffocation because soft tissues lose “tone” and move toward the midline during inspiration.**

Figure from Gray's Anatomy for Students, 3rd edition, pp. 1062-1063.





LARYNX: NERVES



1. Superior laryngeal nerve
2. Internal laryngeal nerve
3. External laryngeal nerve
4. Left recurrent laryngeal nerve
5. Left vagus nerve
6. Right vagus nerve
7. Right recurrent laryngeal nerve

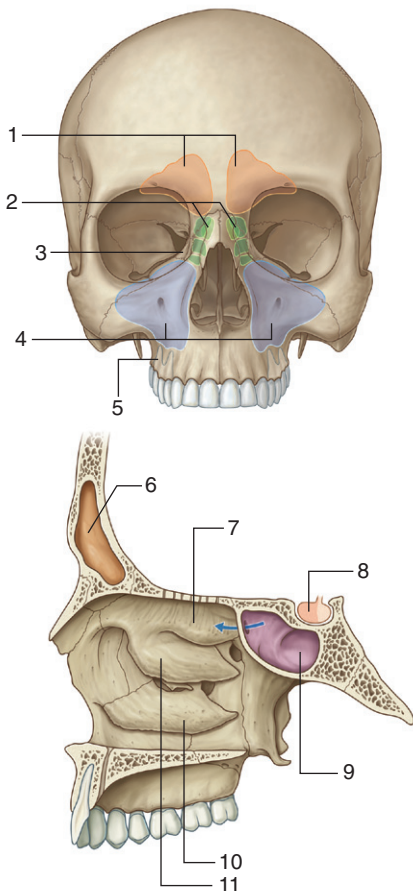
IN THE CLINIC:

- **Innervation of the larynx is by two major branches of the vagus nerve: the superior laryngeal nerve and the recurrent laryngeal nerve.**
- **The superior laryngeal nerve carries general sensation (internal laryngeal nerve) from the lining of the laryngeal cavity above the level of the vocal folds and is motor (external laryngeal nerve) to the cricothyroid muscle.**
- **The recurrent laryngeal nerve is motor to all intrinsic muscles of the larynx, except for the cricothyroid muscle, and carries general sensation from the lining of the laryngeal cavity below the level of the vocal fold.**
- **The left recurrent laryngeal nerve branches from the left vagus nerve in the superior mediastinum in the thorax. The right recurrent laryngeal nerve originates from the right vagus nerve in the root of the neck.**
- **Hoarseness of voice due to the inability to move either the left or the right vocal fold to the midline to meet its counterpart on the opposite side may be the result of a pathologic process in the left side of the superior mediastinum or the right side of the root of the neck that erodes either the left or the right recurrent laryngeal nerve, respectively.**
- **The recurrent laryngeal nerves are in danger of injury during removal of the thyroid gland.**

Figure from Gray's Anatomy for Students, 3rd edition, p. 1068.



Identify the indicated paranasal sinuses and related structures.





NASAL CAVITY: PARANASAL SINUSES



1. Frontal sinuses
2. Ethmoidal cells
3. Orbital plate of ethmoid bone
4. Maxillary sinuses
5. Roots of posterior upper molars
6. Frontal sinus
7. Superior concha
8. Pituitary gland
9. Sphenoidal sinus
10. Inferior concha
11. Middle concha

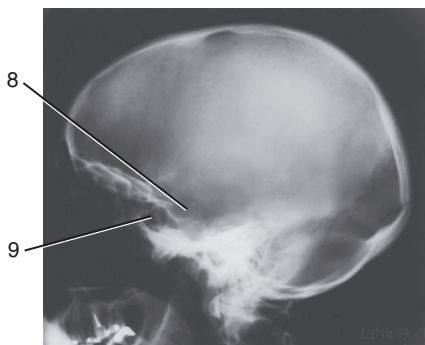
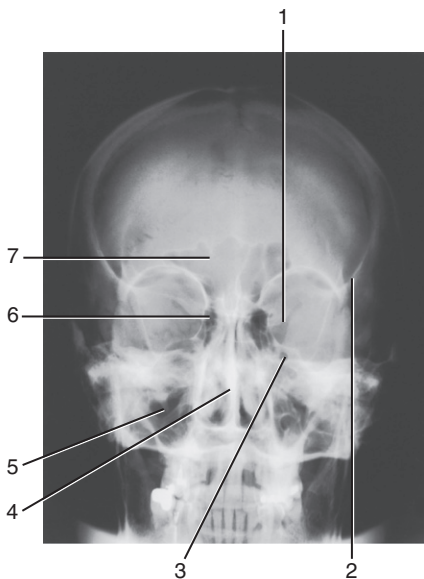
IN THE CLINIC:

- The paranasal sinuses are lined by a mucus-secreting respiratory epithelium. The sinuses normally drain into the nasal cavities.
- Sinusitis is an infection of the sinuses.
- The maxillary sinuses are related to the roots of the upper molar teeth. Abscesses in these teeth can erode into the related sinus. Removal of the molars can generate a communication between the oral cavity and the related maxillary sinus—an “oronasal” fistula.
- The sphenoidal sinus and its bony walls separate the nasal cavity from the pituitary gland. The pituitary gland can surgically be accessed through the nasal cavity and sphenoidal sinus.

Figure from Gray's Anatomy for Students, 3rd edition, pp. 1074 and 1075.



Identify the indicated structures.





RADIOGRAPHS: NASAL CAVITIES AND PARANASAL SINUSES

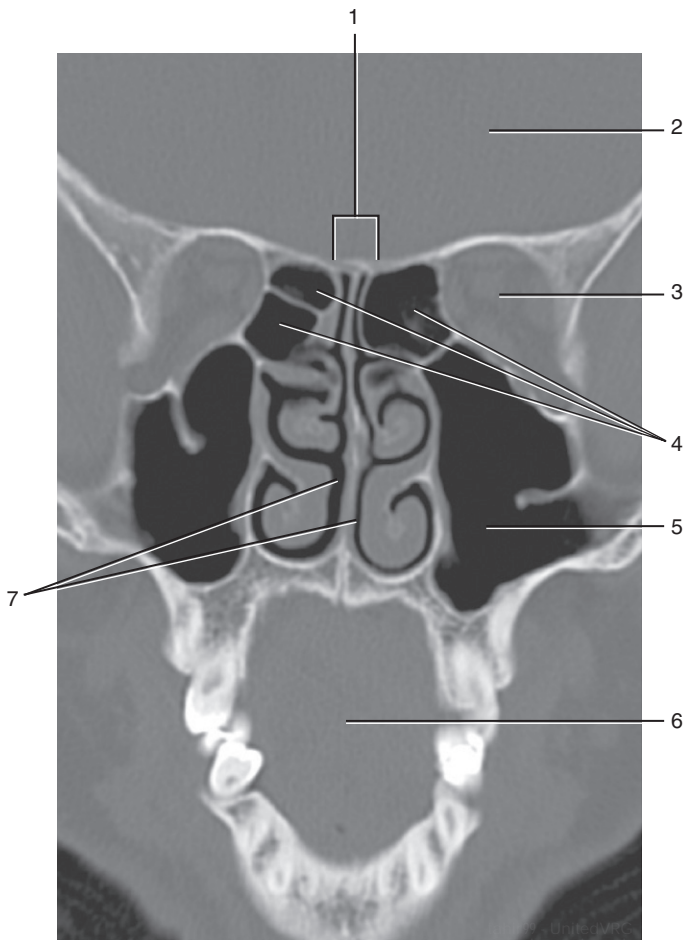


1. Superior orbital fissure
2. Zygomatic process of frontal bone
3. Foramen rotundum
4. Nasal septum
5. Maxillary sinus
6. Ethmoidal cells
7. Frontal sinuses
8. Hypophyseal fossa
9. Sphenoidal sinus

Figure from Gray's Basic Anatomy, p. 563.



Identify the indicated structures.





CT: NASAL CAVITIES AND PARANASAL SINUSES

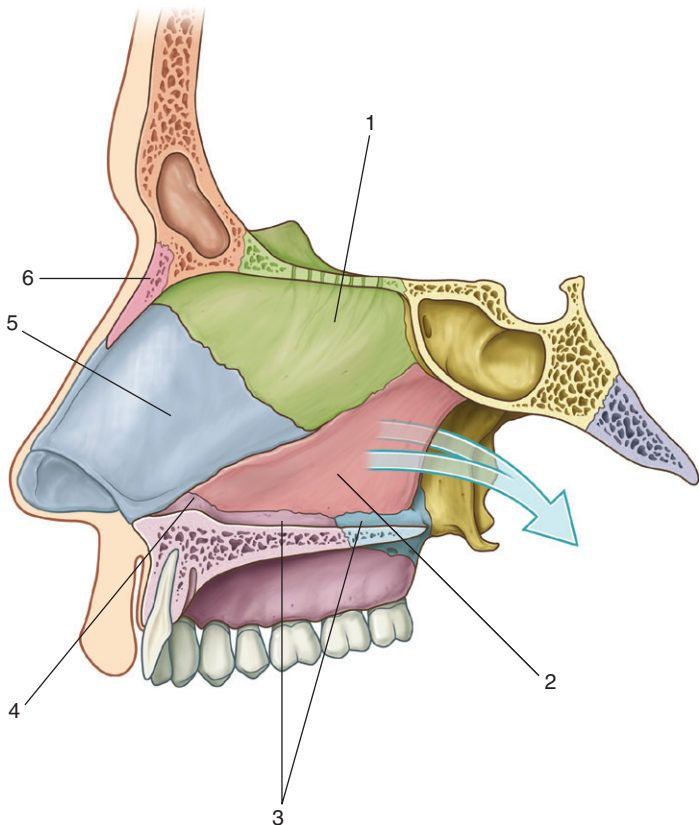


1. Cribriform plate
2. Cranial cavity
3. Orbit
4. Ethmoidal cells
5. Maxillary sinus
6. Oral cavity
7. Nasal cavities

Figure from Gray's Basic Anatomy, p. 563.



Identify the indicated parts of the nasal septum.





NASAL CAVITY: NASAL SEPTUM



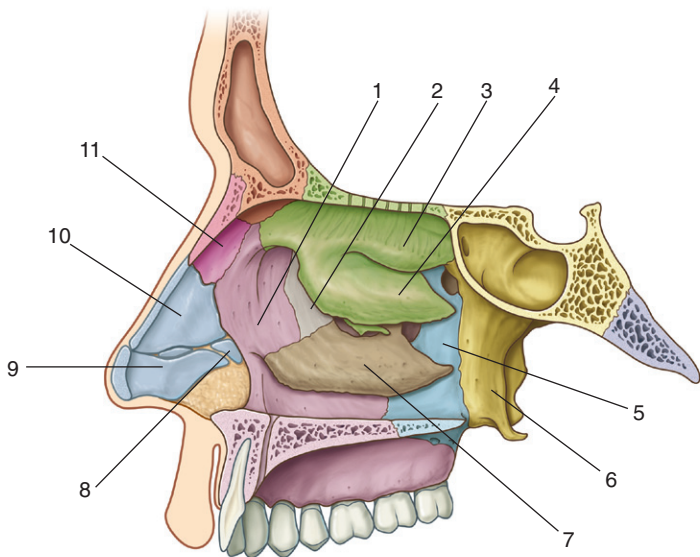
1. Perpendicular plate of ethmoid bone
2. Vomer
3. Nasal crest of maxillary and palatine bones
4. Incisor crest of maxilla
5. Septal cartilage
6. Nasal bone

IN THE CLINIC:

- The nasal septum is formed in the midsagittal plane both by bone and by cartilage. It separates the left and right nasal cavities. In some individuals, the nasal septum can “deviate” from the midline, causing one nasal cavity to be narrower than the other.

Figure from Gray's Anatomy for Students, 3rd edition, p. 1076.

Identify the indicated features.





NASAL CAVITY: LATERAL WALL, BONES



1. Frontal process of maxilla
2. Lacrimal bone
3. Superior concha of ethmoid bone
4. Middle concha of ethmoid bone
5. Perpendicular plate of palatine bone
6. Medial plate of pterygoid process of sphenoid bone
7. Inferior concha
8. Minor alar cartilage
9. Major alar cartilage
10. Lateral process of septal cartilage
11. Nasal bone

Figure from Gray's Anatomy for Students, 3rd edition, p. 1078.

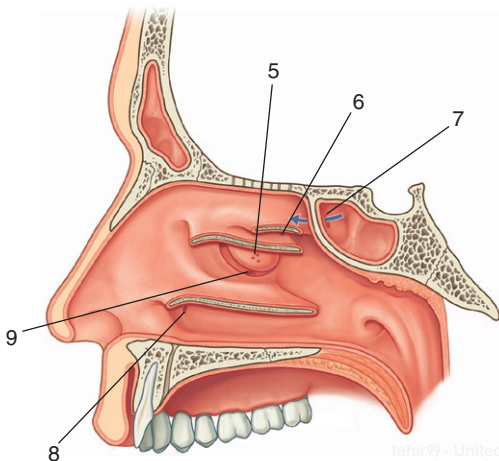
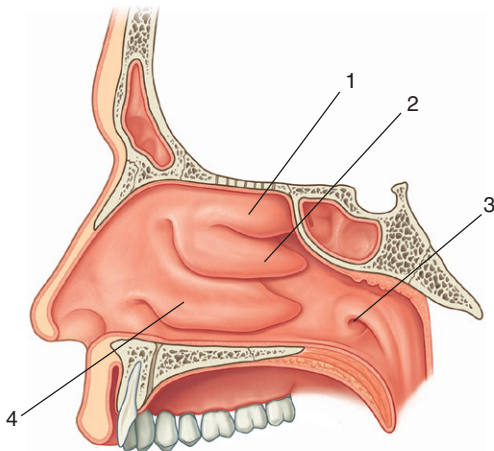


NASAL CAVITY: LATERAL WALL, MUCOSA, AND OPENINGS



323

Identify the indicated features.





NASAL CAVITY: LATERAL WALL, MUCOSA, AND OPENINGS



1. Superior concha
2. Middle concha
3. Opening of pharyngotympanic (eustachian) tube
4. Inferior concha
5. Openings of middle ethmoidal cells onto the ethmoidal bulla
6. Openings of posterior ethmoidal cells onto lateral wall of superior meatus
7. Opening of sphenoidal sinus into spheno-ethmoidal recess
8. Opening of nasolacrimal duct onto lateral wall of inferior meatus
9. Opening of maxillary sinus into floor of hiatus semilunaris

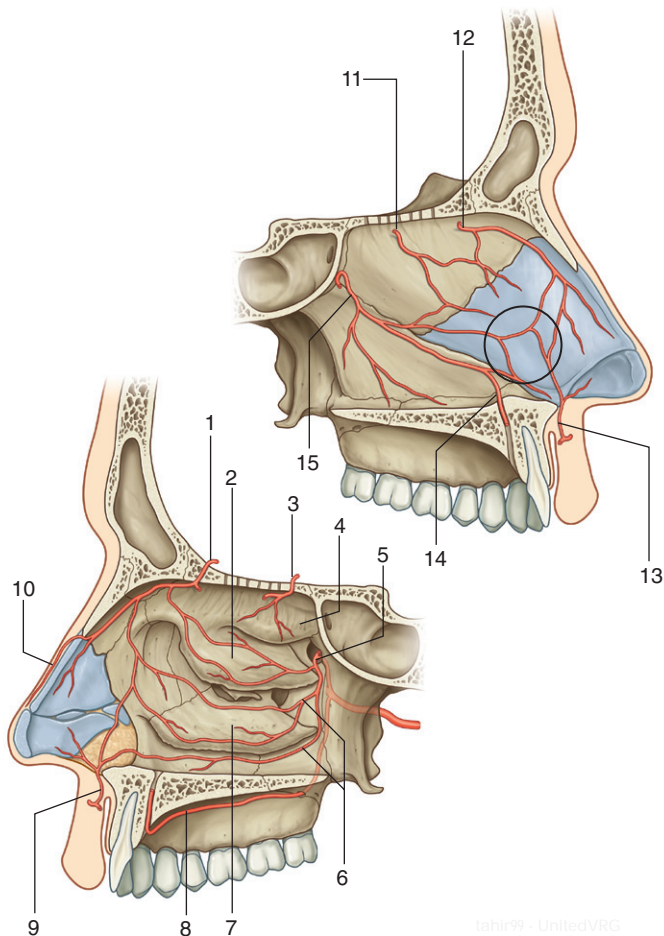
IN THE CLINIC:

- All paranasal sinuses drain into the nasal cavities, as do the nasolacrimal ducts from the orbits.
- The opening for the maxillary sinus is near the top of the sinus. As a result, this sinus is the most difficult of all the sinuses to drain. When problems arise and the sinus does not drain efficiently, an artificial opening can be created by putting a hole through the lateral wall of the nasal cavity and into the sinus closer to its bottom.
- The pharyngeal opening of the pharyngotympanic (eustachian) tube can be accessed by passing an instrument through the nostril and along the floor of the nasal cavity to the lateral wall of the nasopharynx.

Figure from Gray's Anatomy for Students, 3rd edition, p. 1079.



Identify the indicated arteries and related features.





NASAL CAVITY: ARTERIES



1. Anterior ethmoidal artery
2. Middle concha
3. Posterior ethmoidal artery
4. Superior concha
5. Sphenopalatine artery
6. Posterior lateral nasal branches of sphenopalatine artery
7. Inferior concha
8. Greater palatine artery
9. Alar branch of lateral nasal artery
10. External nasal artery from anterior ethmoidal artery
11. Septal branch of posterior ethmoidal artery
12. Septal branch of anterior ethmoidal artery
13. Septal branch from nasal artery from superior labial artery
14. Terminal part of greater palatine artery
15. Posterior septal branch of sphenopalatine artery

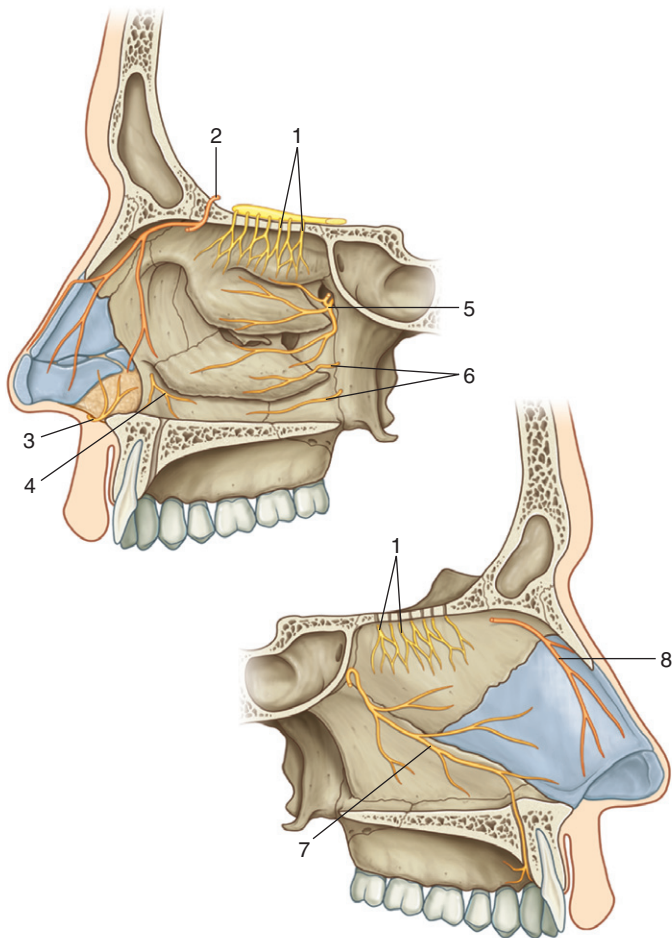
IN THE CLINIC:

- **Vessels that supply the nasal cavities form extensive anastomoses with each other. This is particularly evident in the anterior region of the medial wall, where there are anastomoses between branches of the greater palatine, sphenopalatine, superior labial, and anterior ethmoidal arteries and where the vessels are relatively close to the surface. This area is the major site of “nosebleeds,” or epistaxis.**

Figure from Gray's Anatomy for Students, 3rd edition, p. 1083.



Identify the indicated nerves.





NASAL CAVITY: NERVES



1. Olfactory nerve (I)
2. Anterior ethmoidal nerve (branch of V_1)
3. Internal nasal branches of infra-orbital nerve (branch of V_2)
4. Nasal branch of anterior superior alveolar nerve (branch of V_2)
5. Posterior superior lateral nasal nerves (branches of V_2)
6. Posterior inferior lateral nasal nerves (branches of V_2)
7. Nasopalatine nerve (branch of V_2)
8. Septal branch of anterior ethmoidal nerve (branch of V_1)

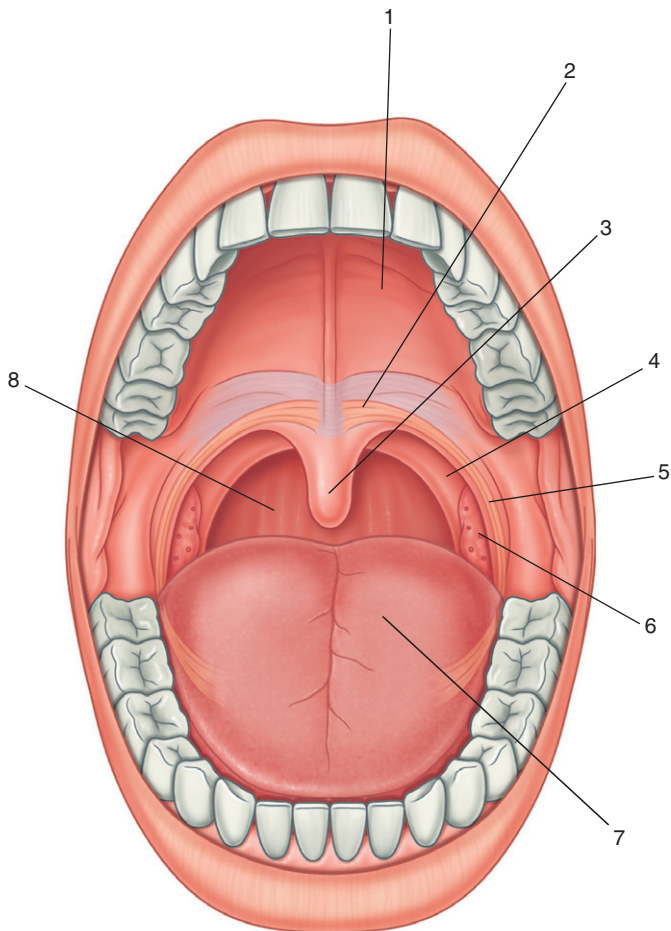
IN THE CLINIC:

- **General sensory innervation to mucosa of the nasal cavity is from multiple branches of V_1 and V_2 . When working on the walls of the nasal cavity, it is important to apply local anesthetic over a wide area.**

Figure from Gray's Anatomy for Students, 3rd edition, p. 1085.



Identify the indicated features.





ORAL CAVITY: OVERVIEW



1. Hard palate
2. Soft palate
3. Uvula
4. Palatopharyngeal arch
5. Palatoglossal arch
6. Palatine tonsil
7. Oral part of tongue (anterior two thirds)
8. Posterior wall of oropharynx

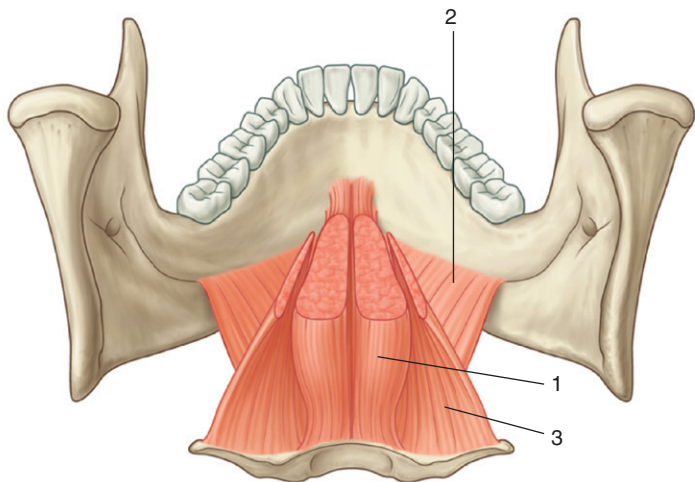
IN THE CLINIC:

- The oropharyngeal isthmus (opening between the oral cavity and the oropharynx) is bound laterally by the palatoglossal arches and inferiorly by the tongue.
- A palatine tonsil can be seen on each side of the oropharynx between the palatoglossal and palatopharyngeal arches.
- Touching the oropharynx can initiate a gag reflex (afferent limb of the gag reflex is cranial nerve IX; the efferent limb is X).

Figure from Gray's Anatomy for Students, 3rd edition, p. 1099.



Identify the indicated muscles.





ORAL CAVITY: FLOOR



1. Genioglossus
2. Mylohyoid
3. Hyoglossus

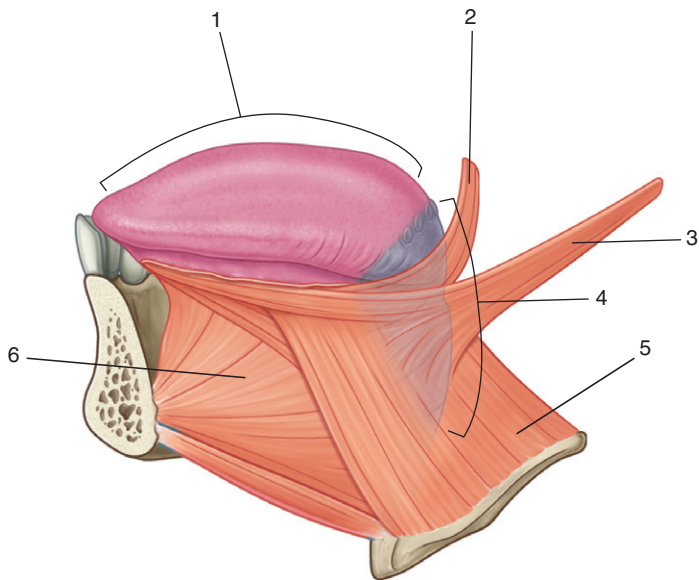
IN THE CLINIC:

- The mylohyoid muscles together form a muscular diaphragm that defines the inferior limit of the floor of the oral cavity. The muscles on a patient can be palpated between two fingers—one finger placed inside the oral cavity lateral to the tongue and the other placed externally medial to the mandible on the same side.
- The genioglossus and hyoglossus muscles are extrinsic muscles of the tongue. The function of the genioglossus muscle is used to test the function of the hypoglossal nerve. A patient is asked to stick his or her tongue out. If the hypoglossal nerve on one side is not functioning, the tip of the tongue when protruded will point to the side where the nerve is affected.

Figure from Gray's Anatomy for Students, 3rd edition, p. 1103.



Identify the indicated regions and muscles.





ORAL CAVITY: TONGUE



1. Anterior two thirds (oral part) of tongue
2. Palatoglossus muscle
3. Styloglossus muscle
4. Posterior third (pharyngeal part) of tongue
5. Hyoglossus muscle
6. Genioglossus muscle

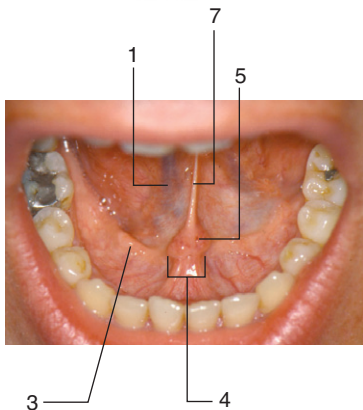
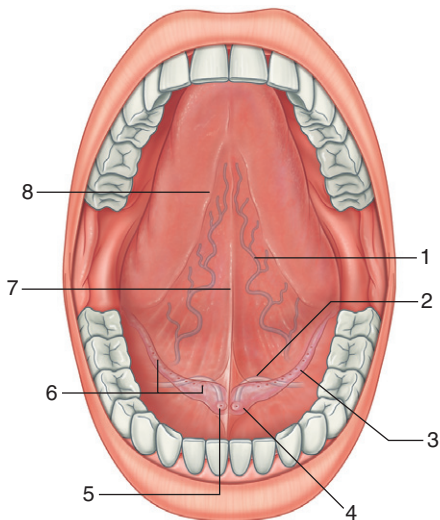
IN THE CLINIC:

- All muscles of the tongue (intrinsic and extrinsic) are innervated by the hypoglossal nerve (XII), except the palatoglossus muscle, which is innervated by the vagus nerve (X) through the pharyngeal plexus. The hypoglossal nerve can be tested clinically by asking a patient to stick his or her tongue out. The tip of the protruded tongue is in the midline if the nerves on both sides are normal. If the nerve on one side has been lesioned, the tip of the protruded tongue points to the side of the lesion.
- General sensation from the oral part of the tongue is by the lingual branch of the mandibular nerve (V_3). Special sensation from the oral part of the tongue is by the facial nerve (VII) via the chorda tympani branch that joins the lingual nerve in the infratemporal fossa.
- General and special sensation from the pharyngeal part of the tongue is by the glossopharyngeal nerve (IX).

Figure from Gray's Anatomy for Students, 3rd edition, p. 1100.



Identify the indicated structures.





ORAL CAVITY: SUBLINGUAL GLANDS



1. Deep lingual vein
2. Submandibular duct
3. Sublingual fold overlying sublingual gland
4. Sublingual caruncle
5. Opening of submandibular duct
6. Opening of ducts from sublingual gland
7. Frenulum of tongue
8. Fimbriated fold

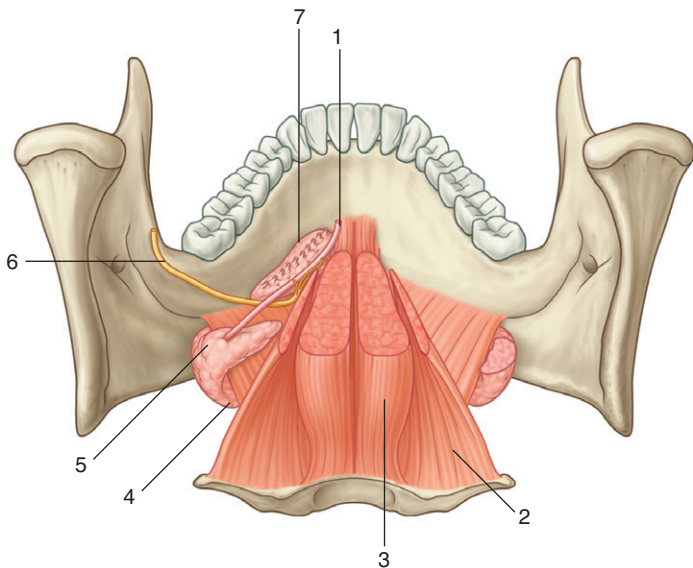
IN THE CLINIC:

- **The oral mucosa on the undersurface of the tongue and on the floor of the oral cavity is “wet” and has a rich blood supply. Pharmaceuticals can be placed under the tongue to be absorbed quickly into the vascular system.**

Figure from Gray's Anatomy for Students, 3rd edition, p. 1103.



Identify the indicated structures.





ORAL CAVITY: GLANDS



1. Submandibular duct
2. Hyoglossus muscle
3. Genioglossus muscle
4. Superficial submandibular gland
5. Deep submandibular gland
6. Lingual nerve
7. Sublingual gland

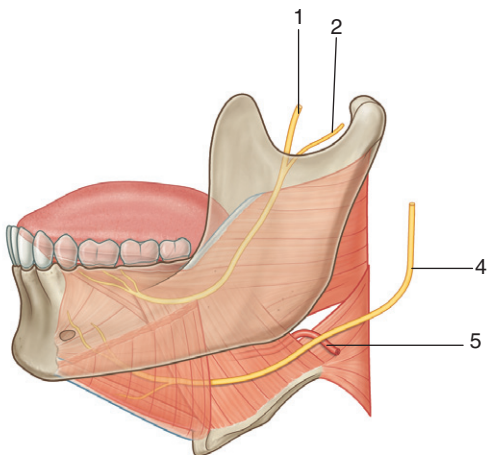
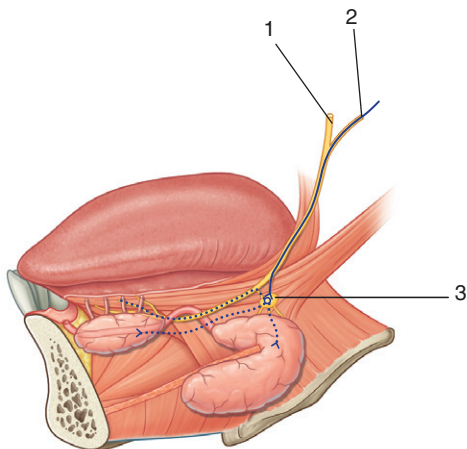
IN THE CLINIC:

- The sublingual gland and opening of the submandibular duct can be visualized in the “open mouth” in the floor of the oral cavity.
- The submandibular duct can become blocked, causing pain, particularly when moving the tongue or when stimulating salivation.

Figure from Gray's Anatomy for Students, 3rd edition, p. 1103.



Identify the indicated structures.





ORAL CAVITY: SALIVARY GLAND NERVES



1. Lingual nerve
2. Chorda tympani nerve
3. Submandibular ganglion
4. Hypoglossal nerve
5. Lingual artery

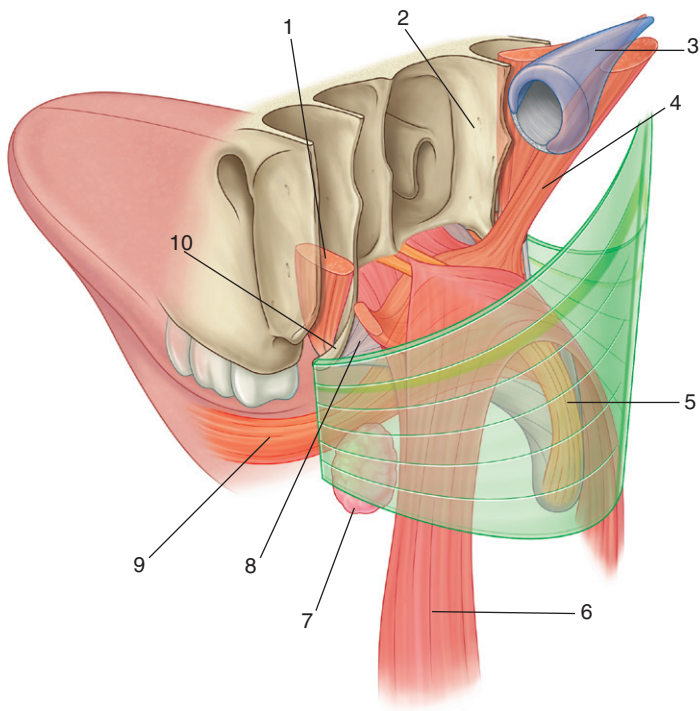
IN THE CLINIC:

- All glands below the level of the oral fissure are innervated by the facial nerve (VII) via the chorda tympani branch that joins the lingual nerve in the infratemporal fossa. Preganglionic parasympathetic fibers in the chorda tympani nerve join the lingual nerve and synapse in the submandibular ganglion in the floor of the oral cavity. Postganglionic parasympathetic fibers pass directly into adjacent glands or are delivered to target glands by branches of the lingual nerve. Taste fibers from the anterior two thirds of the tongue also are carried in the chorda tympani nerve. A lesion to the lingual nerve proximal to where it is joined by the chorda tympani has different consequences than a lesion that occurs distal to the site of union.

Figure from Gray's Anatomy for Students, 3rd edition, pp. 1105 and 1098.



Identify the indicated structures.





ORAL CAVITY: SOFT PALATE (OVERVIEW)



1. Tensor veli palatini muscle
2. Medial plate of pterygoid process of sphenoid bone
3. Pharyngotympanic (eustachian) tube
4. Levator veli palatini muscle
5. Musculus uvulae
6. Palatopharyngeus muscle
7. Palatine tonsil
8. Palatine aponeurosis
9. Palatoglossus muscle
10. Pterygoid hamulus

IN THE CLINIC:

- The soft palate can elevate to close the pharyngeal isthmus between the oropharynx and the nasopharynx or can be depressed to facilitate closing the oropharyngeal isthmus between the oral cavity and oropharynx.
- All muscles of the palate are innervated by cranial nerve (X) via the pharyngeal branch through the pharyngeal plexus, except for the tensor veli palatini, which is innervated by the mandibular nerve (V_3). The only muscle that elevates the palate from the neutral position is the levator veli palatini. Clinically, the function of the levator veli palatini can be used to test the pharyngeal branch of the vagus nerve. A patient is asked to say "ah," which requires elevation of the soft palate. If the muscle on each side is functioning normally, the palate elevates evenly in the midline. If one side is not functioning, the palate deviates away from the affected side of the lesion.

Figure from Gray's Anatomy for Students, 3rd edition, p. 1107.

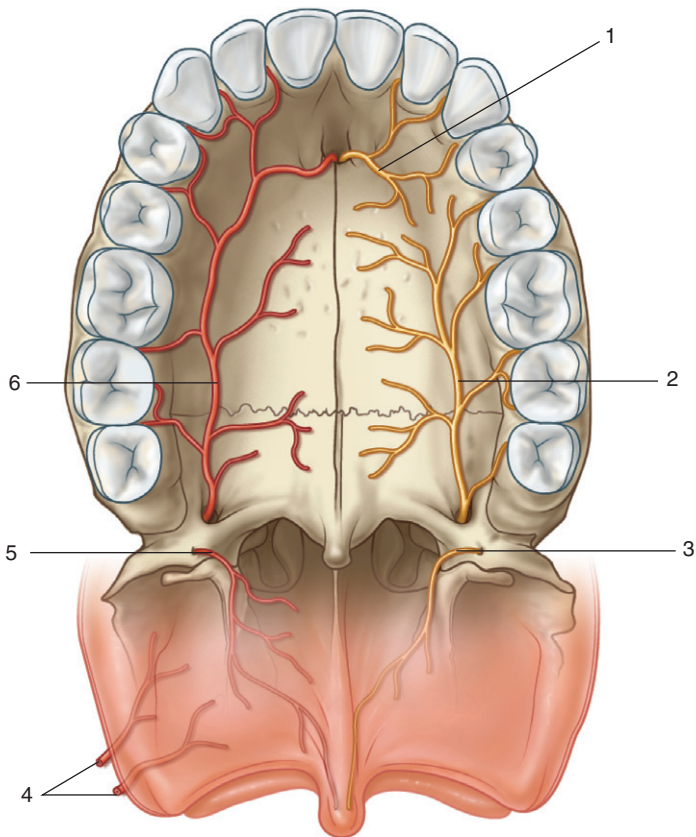


ORAL CAVITY: PALATE, ARTERIES, AND NERVES



333

Identify the indicated arteries and nerves.





ORAL CAVITY: PALATE, ARTERIES, AND NERVES



1. Nasopalatine nerve
2. Greater palatine nerve
3. Lesser palatine nerve
4. Branches of the ascending palatine artery of facial artery and palatine branch of ascending pharyngeal artery
5. Lesser palatine artery
6. Greater palatine artery

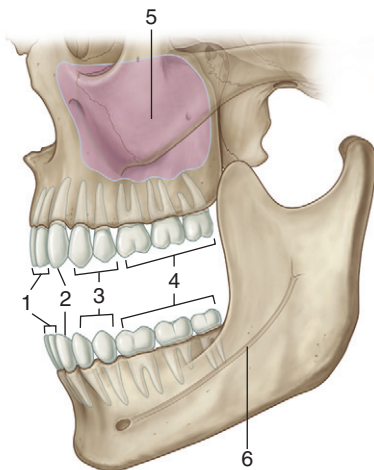
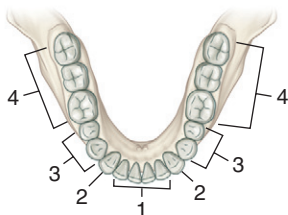
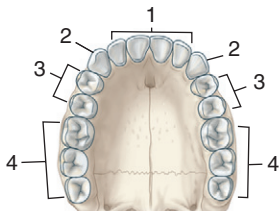
IN THE CLINIC:

- All muscles of the soft palate are innervated by the pharyngeal branch of the vagus via the pharyngeal plexus except for the levator veli palatini, which is innervated by a branch from the mandibular nerve (V_3).

Figure from Gray's Anatomy for Students, 3rd edition, p. 1111.



Identify the indicated structures.





ORAL CAVITY: TEETH



1. Incisor teeth
2. Canine teeth
3. Premolar teeth
4. Molar teeth
5. Maxillary sinus
6. Mandibular canal

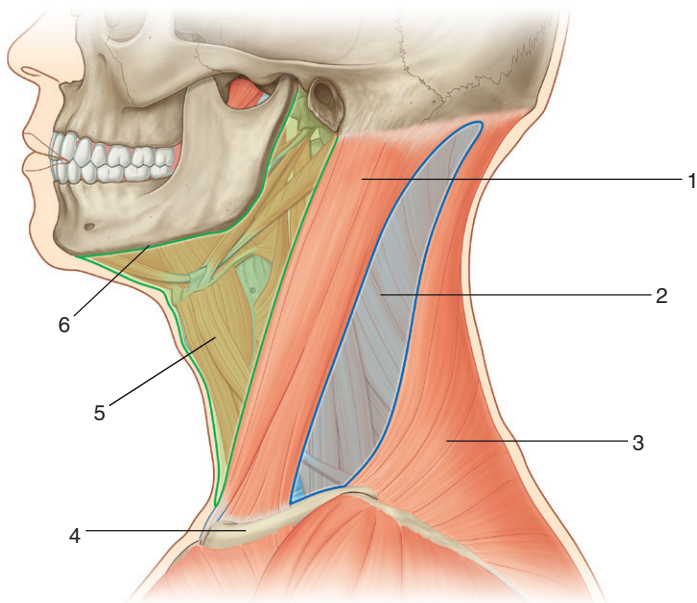
IN THE CLINIC:

- **Roots of the upper molars are related above to the maxillary sinus. Extraction of these teeth can result in the formation of oronasal fistulae (connections between the oral cavity and maxillary sinus).**
- **Roots of the lower molars are related to the mandibular canal containing the inferior alveolar nerve and artery. In some cases, the roots can “hook” around the canal. Extraction of these teeth can endanger the inferior alveolar nerve.**

Figure from Gray's Anatomy for Students, 3rd edition, p. 1115.



Identify the triangles of the neck and features related to their boundaries.





NECK: TRIANGLES



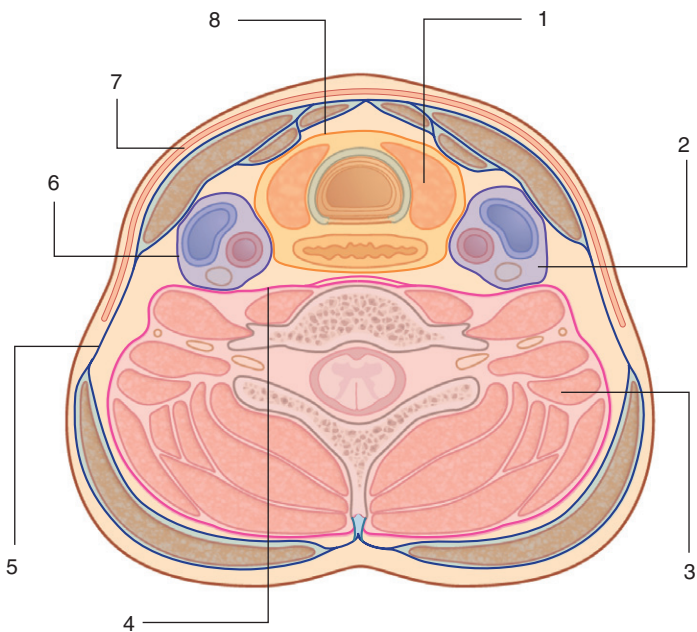
1. Sternocleidomastoid muscle
2. Posterior triangle
3. Trapezius muscle
4. Clavicle
5. Anterior triangle
6. Inferior border of mandible

IN THE CLINIC:

- **The boundaries of the anterior triangle are the anterior border of the sternocleidomastoid muscle, the inferior border of the mandible, and the midline of the neck. The boundaries of the posterior triangle are the posterior border of the sternocleidomastoid muscle, the anterior border of the trapezius muscle, and the middle one third of the clavicle.**

Figure from Gray's Anatomy for Students, 3rd edition, p. 1000.

Identify the compartments and fascial layers of the neck.





1. Visceral compartment
2. Vascular compartment
3. Vertebral compartment
4. Prevertebral fascia
5. Investing fascia
6. Carotid sheath
7. Superficial fascia
8. Pretracheal fascia

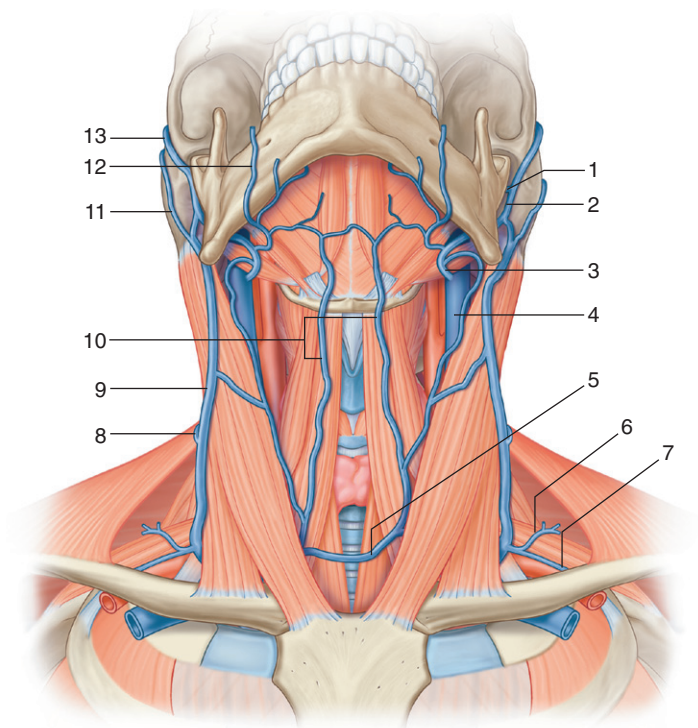
IN THE CLINIC:

- **The neck contains a series of fascial compartments. All these compartments are deep to the investing layer of fascia that is the outer layer of deep fascia surrounding the neck. The clinical importance of these compartments is that infection tends to spread within compartments or within the spaces between the fascial layers. For example, if an infection arises in the pretracheal space between the pretracheal fascia and overlying investing fascia related to the infrahyoid muscles, it may spread inferiorly into the superior mediastinum.**

Figure from Gray's Anatomy for Students, 3rd edition, p. 1101.



Identify the indicated superficial veins of the neck.





NECK: SUPERFICIAL VEINS



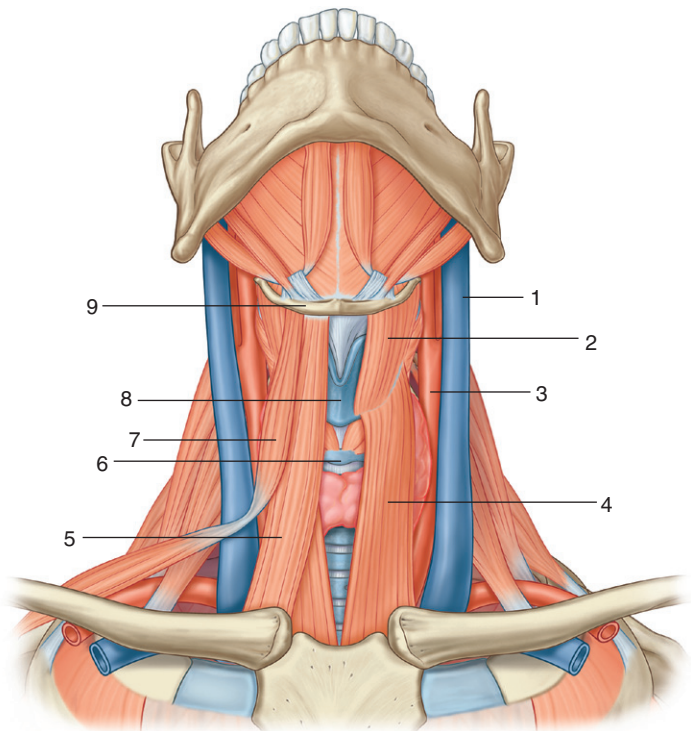
1. Maxillary vein
2. Retromandibular vein
3. Common facial vein
4. Internal jugular vein
5. Venous arch
6. Transverse cervical vein
7. Suprascapular vein
8. Posterior external jugular vein
9. External jugular vein
10. Anterior jugular veins
11. Posterior auricular vein
12. Facial vein
13. Superficial temporal vein

IN THE CLINIC:

- The external jugular vein is formed posterior to the angle of the mandible as the posterior auricular vein and the posterior division of the retromandibular vein join. Once formed, the external jugular vein passes straight down the neck in the superficial fascia and is superficial to the sternocleidomastoid muscle throughout its course, crossing it diagonally as it descends.

Figure from Gray's Anatomy for Students, 3rd edition, p. 1003.

Identify the indicated structures.





NECK: ANTERIOR TRIANGLE, INFRAHYOID MUSCLES



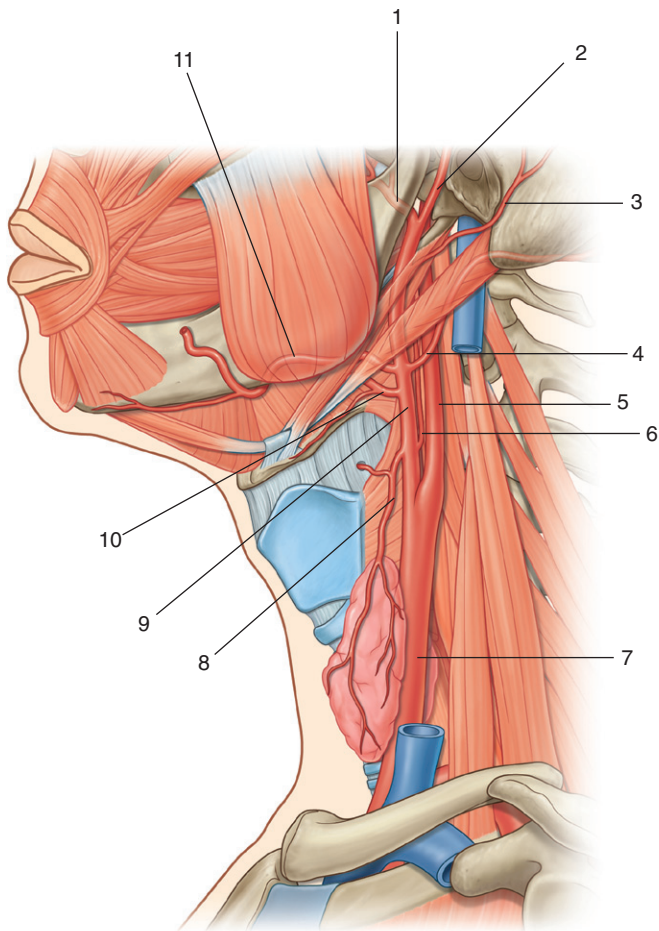
1. Internal jugular vein
2. Thyrohyoid muscle
3. Common carotid artery
4. Sternothyroid muscle
5. Sternohyoid muscle
6. Cricoid cartilage
7. Omohyoid muscle
8. Thyroid cartilage
9. Hyoid bone

IN THE CLINIC:

- **The four infrahyoid muscles are in the muscular triangle. They attach the hyoid bone to inferior structures and depress the hyoid bone. They also provide a stable point of attachment for the suprahyoid muscles.**

Figure from Gray's Anatomy for Students, 3rd edition, p. 1009.

Identify the indicated arteries.





NECK: ANTERIOR TRIANGLE, CAROTID SYSTEM



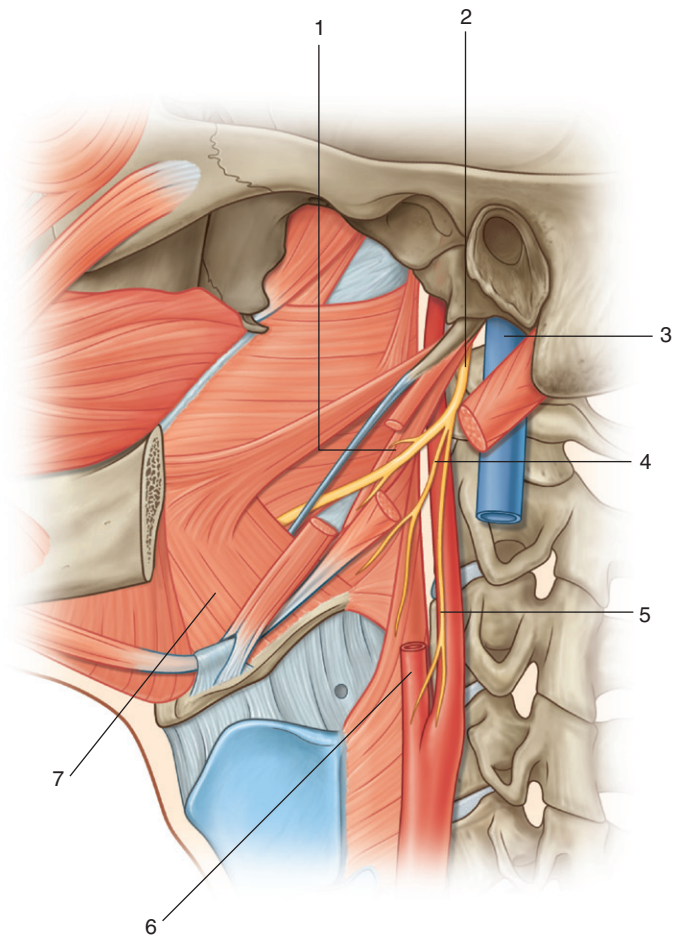
1. Maxillary artery
2. Superficial temporal artery
3. Posterior auricular artery
4. Occipital artery
5. Internal carotid artery
6. Ascending pharyngeal artery
7. Common carotid artery
8. Superior thyroid artery
9. External carotid artery
10. Lingual artery
11. Facial artery

IN THE CLINIC:

- Near the superior edge of the thyroid cartilage each common carotid artery divides into its two terminal branches, the external and internal carotid arteries. At this bifurcation, the common carotid artery and the beginning of the internal carotid artery are dilated. This dilation is the carotid sinus and contains receptors that monitor changes in blood pressure and are innervated by a branch of the glossopharyngeal nerve (IX). Another accumulation of receptors in the area of the bifurcation is responsible for detecting changes in blood chemistry, primarily oxygen content. This is the carotid body and is innervated by branches from both the glossopharyngeal (IX) and vagus (X) nerves.

Figure from Gray's Anatomy for Students, 3rd edition, p. 1012.

Identify the indicated structures.





NECK: ANTERIOR TRIANGLE, GLOSSOPHARYNGEAL NERVE



1. Stylopharyngeus muscle
2. Glossopharyngeal nerve (IX)
3. Internal jugular vein
4. Pharyngeal branch
5. Carotid sinus branch
6. External carotid artery
7. Hyoglossus muscle

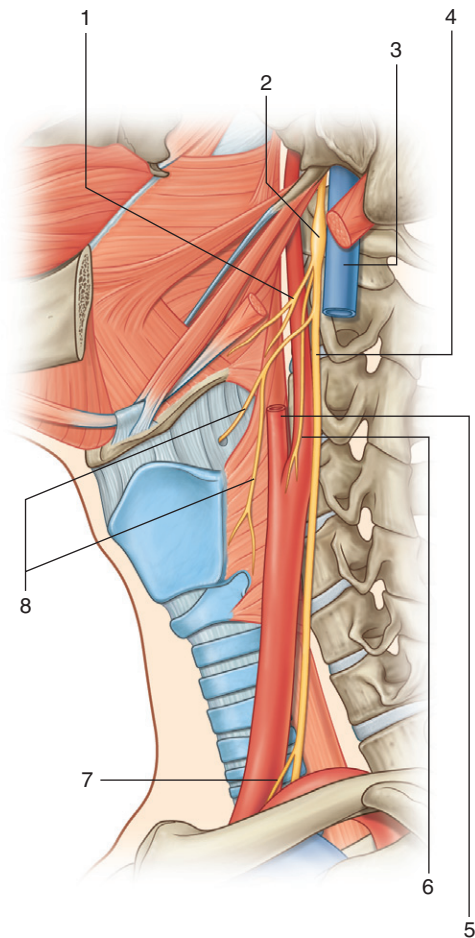
IN THE CLINIC:

- **As the glossopharyngeal nerve (IX) passes through the area of the anterior triangle of the neck it innervates the stylopharyngeus muscle, sends a branch to the carotid sinus, and supplies sensory branches to the pharynx.**

Figure from Gray's Anatomy for Students, 3rd edition, p. 1015.



Identify the indicated structures.





NECK: ANTERIOR TRIANGLE, VAGUS NERVE



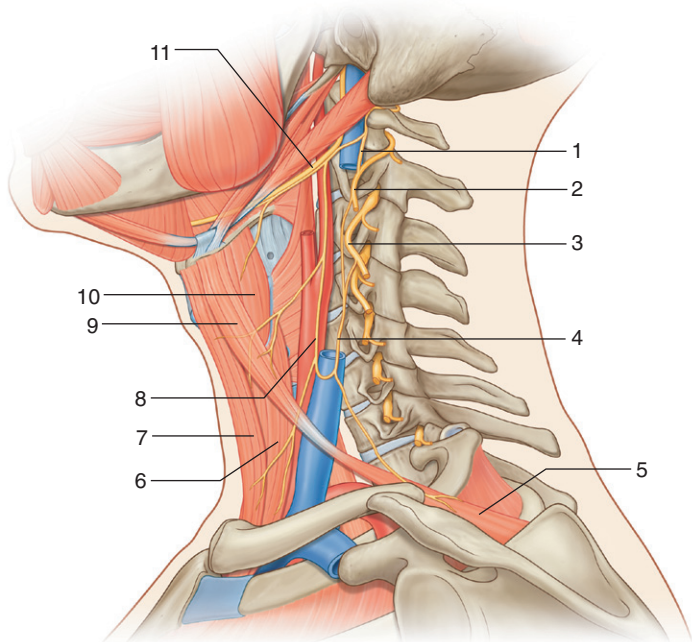
1. Pharyngeal branch
2. Inferior ganglion
3. Internal jugular vein
4. Vagus nerve [X]
5. External carotid artery
6. Carotid body branch
7. Cardiac branch
8. Internal and external laryngeal nerves (branches of the superior laryngeal nerve)

IN THE CLINIC:

- **Branches of the vagus nerve (X) as it passes through the anterior triangle of the neck include a motor branch to the pharynx, a branch to the carotid body, the superior laryngeal nerve, which divides into external and internal laryngeal nerves), and possibly a cardiac branch.**

Figure from Gray's Anatomy for Students, 3rd edition, p. 1014.

Identify the indicated structures and nerves.





NECK: ANTERIOR TRIANGLE, HYPOGLOSSAL NERVE, AND ANSA CERVICALIS



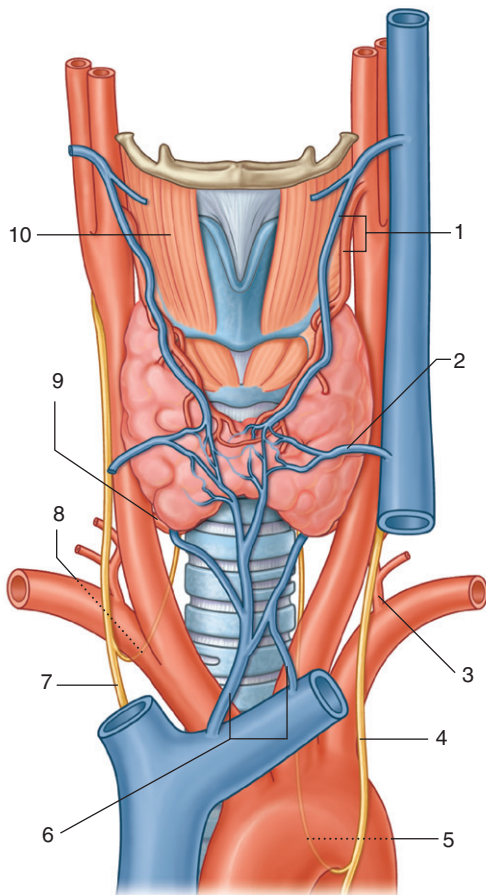
1. C1
2. C2
3. C3
4. Inferior root of ansa cervicalis
5. Omohyoid muscle (inferior belly)
6. Sternothyroid muscle
7. Sternohyoid muscle
8. Superior root of ansa cervicalis
9. Omohyoid muscle (superior belly)
10. Thyrohyoid muscle
11. Hypoglossal nerve (XII)

IN THE CLINIC:

- The hypoglossal nerve (XII), which supplies the tongue, does not give off any branches as it passes through the anterior triangle of the neck.
- The ansa cervicalis is a loop of nerve fibers from cervical nerves C1 to C3 that innervate the muscles in the anterior triangle of the neck. The superior root is from C1 and innervates the thyrohyoid muscle, the superior belly of the omohyoid muscle, and the upper parts of the sternohyoid and sternothyroid muscles. The inferior root is from C2 and C3 and innervates the inferior belly of the omohyoid muscle and the lower parts of the sternohyoid and sternothyroid muscles.

Figure from Gray's Anatomy for Students, 3rd edition, p. 1016.

Identify the indicated vessels and nerves associated with the thyroid gland.





NECK: ANTERIOR TRIANGLE, ANTERIOR VIEW THYROID



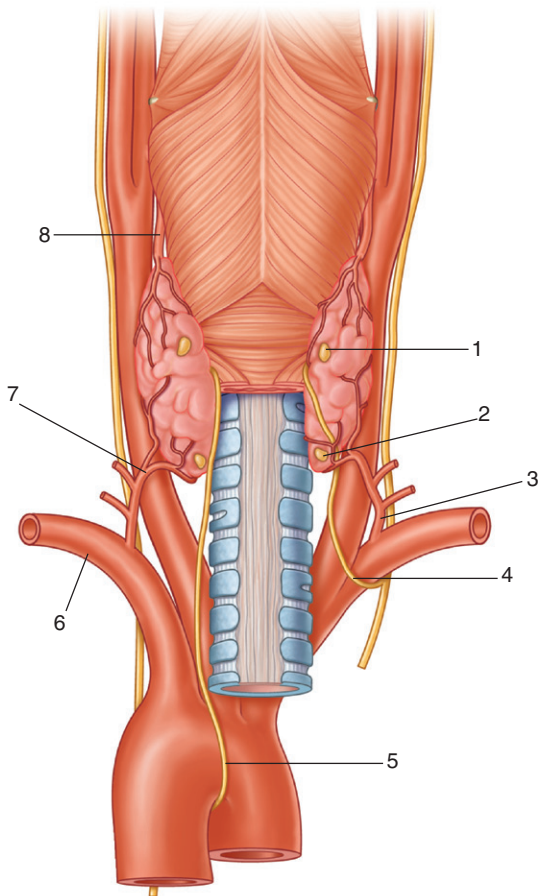
1. Superior thyroid artery and vein
2. Middle thyroid vein
3. Thyrocervical trunk
4. Left vagus nerve
5. Left recurrent laryngeal nerve
6. Inferior thyroid veins
7. Right vagus nerve
8. Right recurrent laryngeal nerve
9. Inferior thyroid artery
10. Thyrohyoid muscle

IN THE CLINIC:

- **The thyroid gland develops from a small region of tissue near the base of the tongue. This tissue descends as the thyroglossal duct from the posterior aspect of the tongue. It continues inferiorly, passing anterior to the middle of the hyoid bone, until reaching its final position in the root of the neck anterior to the trachea. Although thyroid tissue can be found along this path, it is more common to find thyroglossal duct cysts along the midline path of migration.**

Figure from Gray's Atlas of Anatomy, p. 1019.

Identify the indicated structures in the posterior view of the thyroid gland.





NECK: ANTERIOR TRIANGLE, POSTERIOR VIEW THYROID



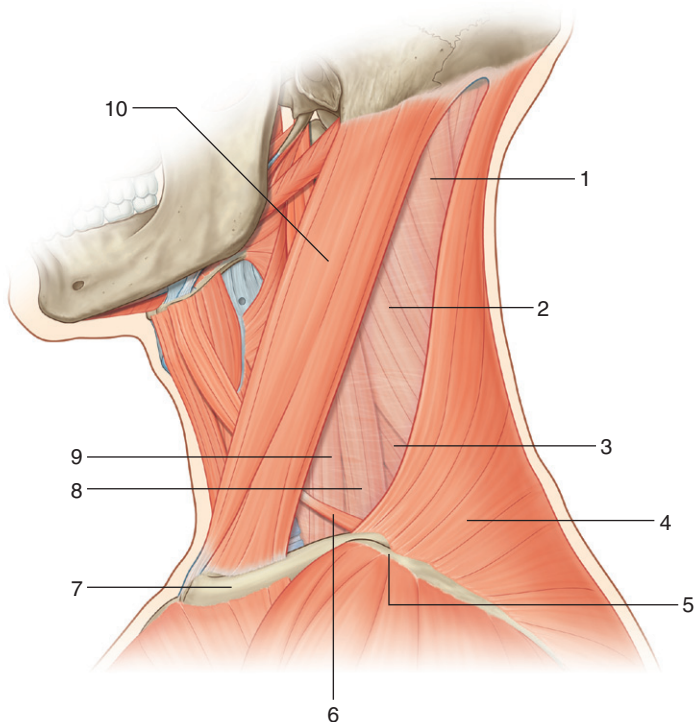
1. Superior parathyroid gland
2. Inferior parathyroid gland
3. Thyrocervical trunk
4. Right recurrent laryngeal nerve
5. Left recurrent laryngeal nerve
6. Left subclavian artery
7. Inferior thyroid artery
8. Superior thyroid artery

IN THE CLINIC:

- **A thyroidectomy is a relatively common surgical procedure involving removal of part or all of the thyroid gland. Because of its location, there is a possibility of damaging other structures during this procedure, including the parathyroid glands, the recurrent laryngeal nerves, and the sympathetic trunk.**

Figure from Gray's Anatomy for Students, 3rd edition, p. 1019.

Identify the indicated muscles and related structures of the posterior triangle of the neck.





NECK: POSTERIOR TRIANGLE, MUSCLES



1. Splenius capitis muscle
2. Levator scapulae muscle
3. Posterior scalene muscle
4. Trapezius muscle
5. Acromion of scapula
6. Inferior belly of omohyoid muscle
7. Clavicle
8. Middle scalene muscle
9. Anterior scalene muscle
10. Sternocleidomastoid muscle

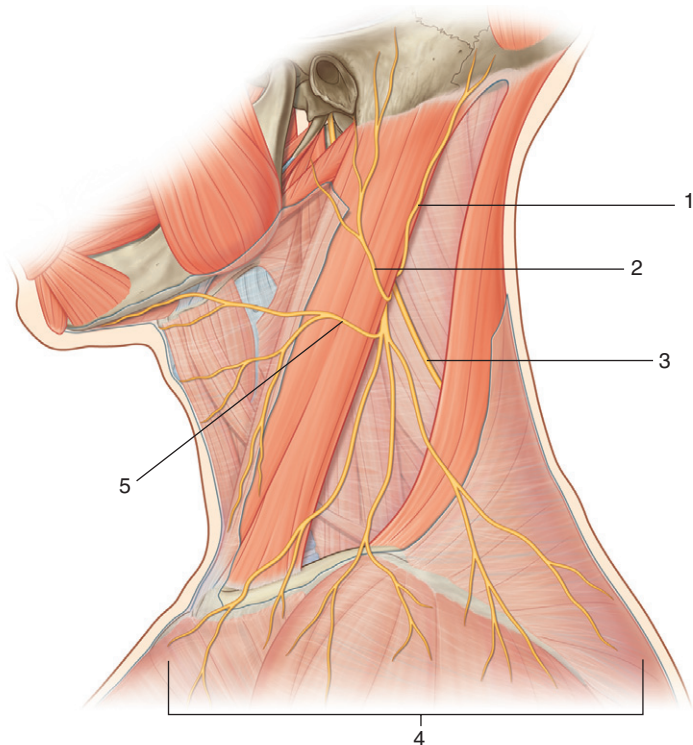
IN THE CLINIC:

- The roof of the posterior triangle consists of an investing layer of cervical fascia that surrounds the sternocleidomastoid and trapezius muscles.
- The floor of the posterior triangle is covered by the prevertebral layer of cervical fascia and consists of the following muscles, beginning superiorly: splenius capitis; levator scapulae; and posterior, middle, and anterior scalene muscles.

Figure from Gray's Anatomy for Students, 3rd edition, p. 1025.



Identify the indicated nerves in the posterior triangle of the neck.





NECK: POSTERIOR TRIANGLE, NERVES



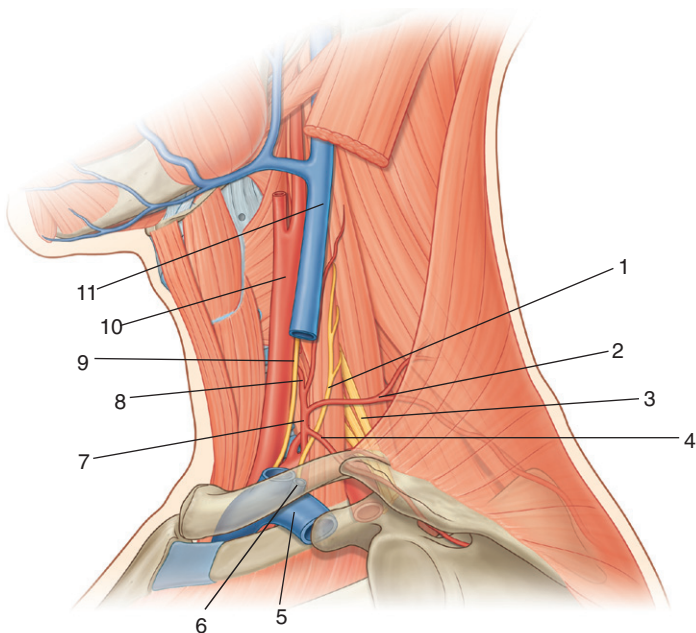
1. Lesser occipital nerve
2. Great auricular nerve
3. Accessory nerve (XI)
4. Supraclavicular nerves
5. Transverse cervical nerve

IN THE CLINIC:

- **A variety of nerves pass through or are within the posterior triangle. These include the accessory nerve (XI), branches of the cervical plexus, components forming the brachial plexus, and branches of the brachial plexus. Because of the superficial location of some of these nerves, they are susceptible to injury.**

Figure from Gray's Anatomy for Students, 3rd edition, p. 1027.

Identify the indicated arteries, veins, and nerves related to the posterior triangle of the neck.





BASE OF NECK



1. Phrenic nerve
2. Transverse cervical artery
3. Brachial plexus
4. Suprascapular artery
5. Subclavian vein
6. External jugular vein
7. Thyrocervical trunk
8. Inferior thyroid artery
9. Vagus nerve (X)
10. Common carotid artery
11. Internal jugular vein

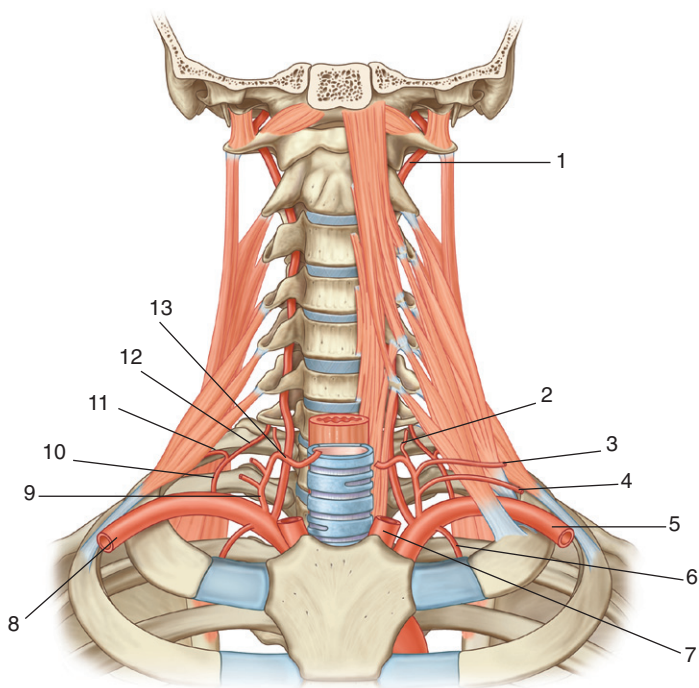
IN THE CLINIC:

- **Large-bore catheters can be inserted into larger central veins (central venous access) for the administration of large amounts of fluids or drugs that need rapid dilution. In the root of the neck this must be done carefully to avoid injury to surrounding structures. A misdirected subclavian vein procedure can puncture the cervical pleura, producing a pneumothorax, and an improperly performed internal jugular vein procedure can cause local hematoma and damage to the carotid artery.**

Figure from Gray's Anatomy for Students, 3rd edition, p. 1026.



Identify the indicated arteries in the base of the neck.





BASE OF NECK: ARTERIES



1. Vertebral artery
2. Ascending cervical artery
3. Transverse cervical artery
4. Suprascapular artery
5. Left subclavian artery
6. Internal thoracic artery
7. Left common carotid artery
8. Right subclavian artery
9. Thyrocervical trunk
10. Costocervical trunk
11. Supreme intercostal artery
12. Deep cervical artery
13. Inferior thyroid artery

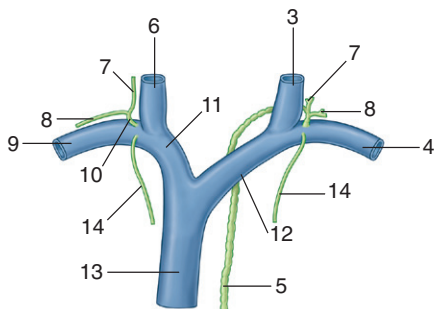
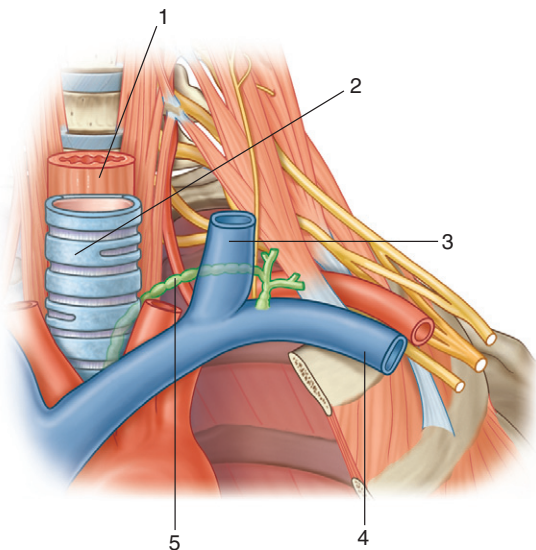
IN THE CLINIC:

- Each subclavian artery is divided into three parts by the anterior scalene muscle. The first part extends from the origin of the artery to the anterior scalene muscle. The second part is the portion of the artery posterior to the anterior scalene muscle. The third part is the portion of the artery lateral to the anterior scalene muscle before the artery reaches the lateral border of rib I. All branches (vertebral, thyrocervical trunk, internal thoracic, costocervical) from the subclavian arteries arise from the first part of the artery, except for the costocervical trunk on the right side, which arises from the second part.

Figure from Gray's Anatomy for Students, 3rd edition, p. 1031.



Identify the indicated structures.





BASE OF NECK: LYMPHATICS



1. Esophagus
2. Trachea
3. Left internal jugular vein
4. Left subclavian vein
5. Thoracic duct
6. Right internal jugular vein
7. Jugular trunk
8. Subclavian trunk
9. Right subclavian vein
10. Right lymphatic duct
11. Right brachiocephalic vein
12. Left brachiocephalic vein
13. Superior vena cava
14. Bronchomediastinal trunk

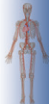IN THE CLINIC:

- The thoracic duct terminates in the junction between the left internal jugular and left subclavian veins. It may be joined at this junction by the left jugular trunk, which drains lymph from the left side of the head and neck, and the left subclavian trunk, which drains lymph from the left upper limb. The left bronchomediastinal trunk, which drains lymph from the left half of the thoracic structures, usually enters the left subclavian vein directly but may occasionally enter the thoracic duct. A similar confluence of lymphatic trunks occurs on the right side.

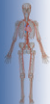Figure from Gray's Anatomy for Students, 3rd edition, p. 1037.



SECTION 9: SURFACE ANATOMY



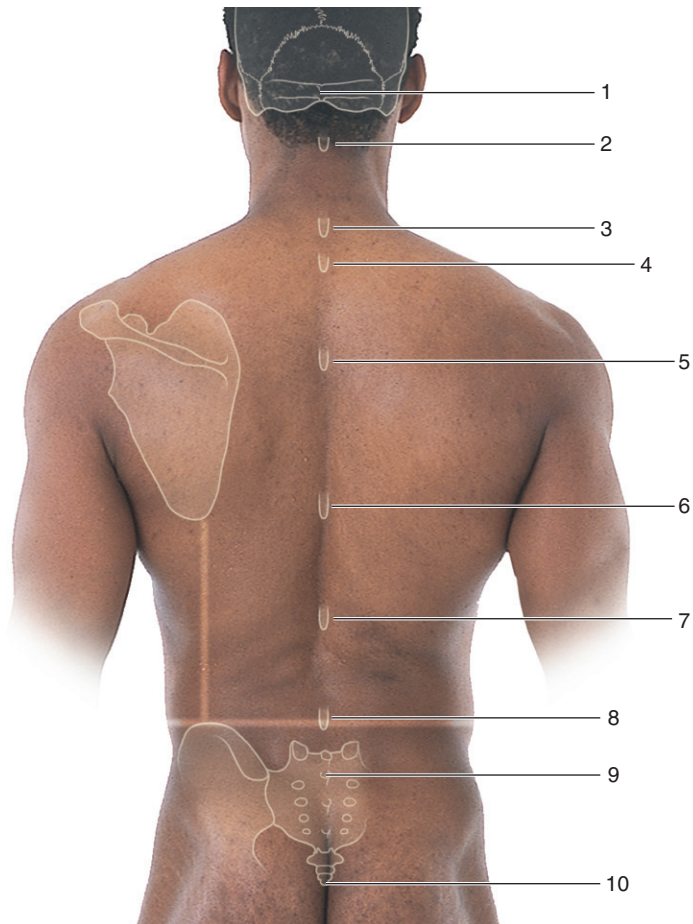
- 350. Back Surface Anatomy
- 351. End of Spinal Cord: Lumbar Puncture
- 352. Thoracic Skeletal Landmarks
- 353. Heart Valve Auscultation
- 354. Lung Auscultation 1
- 355. Lung Auscultation 2
- 356. Referred Pain: Heart
- 357. Inguinal Hernia I
- 358. Inguinal Hernia II
- 359. Inguinal Hernia III
- 360. Referred Abdominal Pain
- 361. Female Perineum
- 362. Male Perineum
- 363. Gluteal Injection Site
- 364. Femoral Triangle Surface Anatomy
- 365. Popliteal Fossa
- 366. Tarsal Tunnel
- 367. Lower Limb Pulse Points
- 368. Upper Limb Pulse Points
- 369. Head and Neck Pulse Points

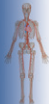



BACK SURFACE ANATOMY

Identify the indicated bony landmarks.





BACK SURFACE ANATOMY



1. External occipital protuberance
2. CII vertebral spinous process
3. CVII vertebral spinous process
4. TI vertebral spinous process
5. TIII vertebral spinous process
6. TVII vertebral spinous process
7. TXII vertebral spinous process
8. LIV vertebral spinous process
9. SII vertebral spinous process
10. Tip of coccyx

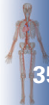IN THE CLINIC:

- **Vertebral spines are used as landmarks for approximating the position of deep structures in the back, thorax, and abdomen.**

Figure from Gray's Anatomy for Students, 3rd edition, p. 114.

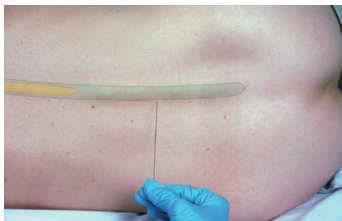
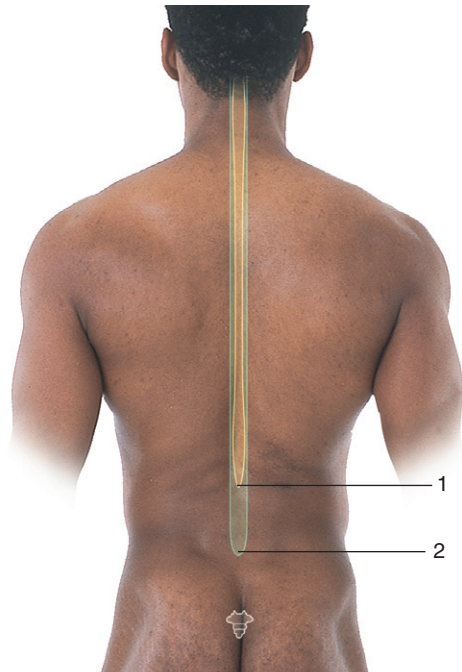


END OF SPINAL CORD: LUMBAR PUNCTURE



351

Identify the indicated features.





END OF SPINAL CORD: LUMBAR PUNCTURE



1. Inferior end of spinal cord normally between LI and LII vertebrae
2. Inferior end of subarachnoid space normally at SII

IN THE CLINIC:

- In most adults the subarachnoid space can be accessed in the lower lumbar region with minimal risk of damage to the spinal cord.

Figure from Gray's Anatomy for Students, 3rd edition, pp. 115-116.

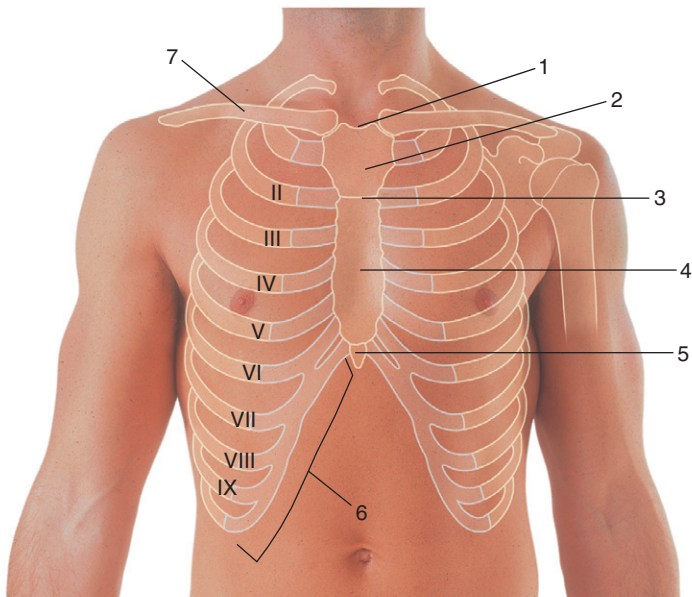


THORACIC SKELETAL LANDMARKS



352

Identify the indicated features.





THORACIC SKELETAL LANDMARKS



1. Jugular notch/suprasternal notch
2. Manubrium of sternum
3. Sternal angle
4. Body of sternum
5. Xiphoid process
6. Costal margin
7. Clavicle

IN THE CLINIC:

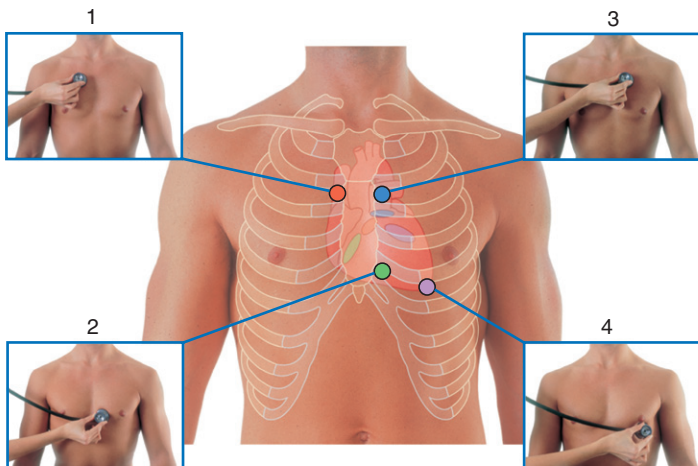
- **The sternal angle is a major landmark for counting ribs. Rib II articulates with the angle.**

Figure from Gray's Anatomy for Students, 3rd edition, p. 231.



HEART VALVE AUSCULTATION

Which heart valves can be heard at each of the indicated positions?





HEART VALVE AUSCULTATION



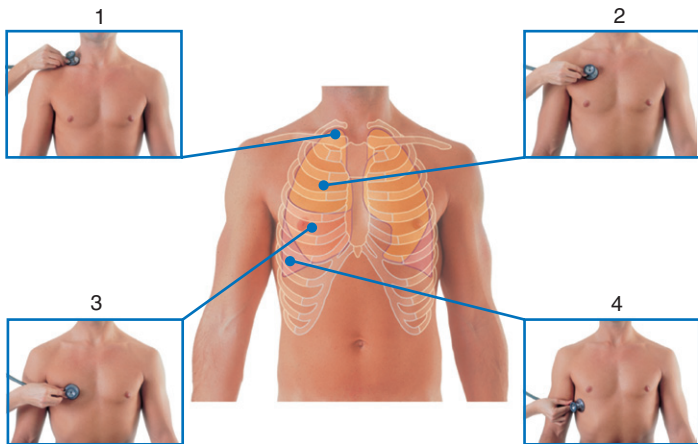
1. Aortic valve
2. Tricuspid valve
3. Pulmonary valve
4. Mitral valve

Figure from Gray's Anatomy for Students, 3rd edition, p. 236.



LUNG AUSCULTATION 1

Which parts of the lungs can be heard at each of the indicated positions?





LUNG AUSCULTATION 1



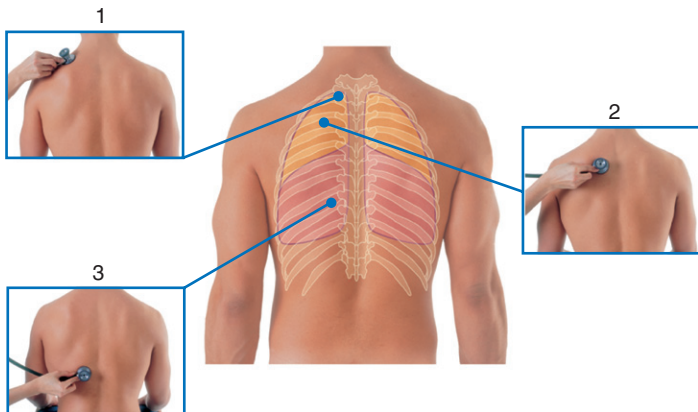
1. Apex of right lung
2. Superior lobe of right lung
3. Middle lobe of right lung
4. Inferior lobe of right lung

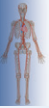Figure from Gray's Anatomy for Students, 3rd edition, p. 240.



LUNG AUSCULTATION 2

Which parts of the lungs can be heard at each of the indicated positions?



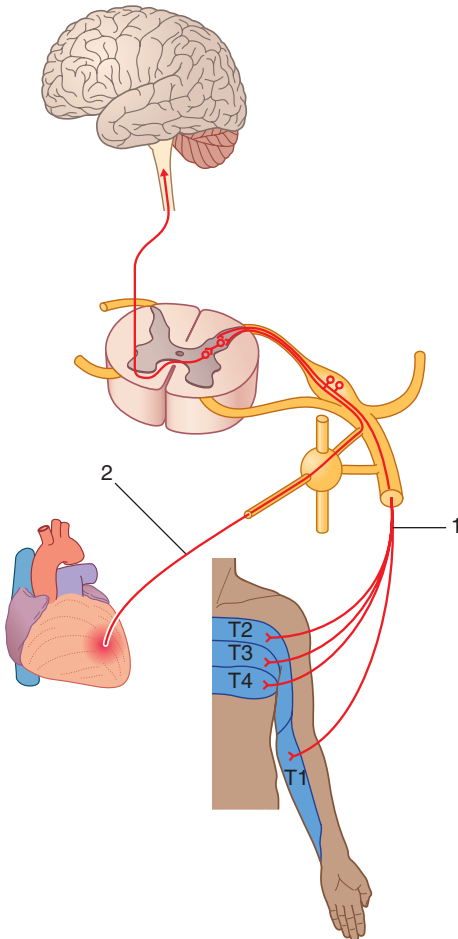


LUNG AUSCULTATION 2



1. Apex of left lung
2. Superior lobe of left lung
3. Inferior lobe of left lung

Figure from Gray's Anatomy for Students, 3rd edition, p. 240.





REFERRED PAIN: HEART



1. Somatic sensory
2. Visceral sensory

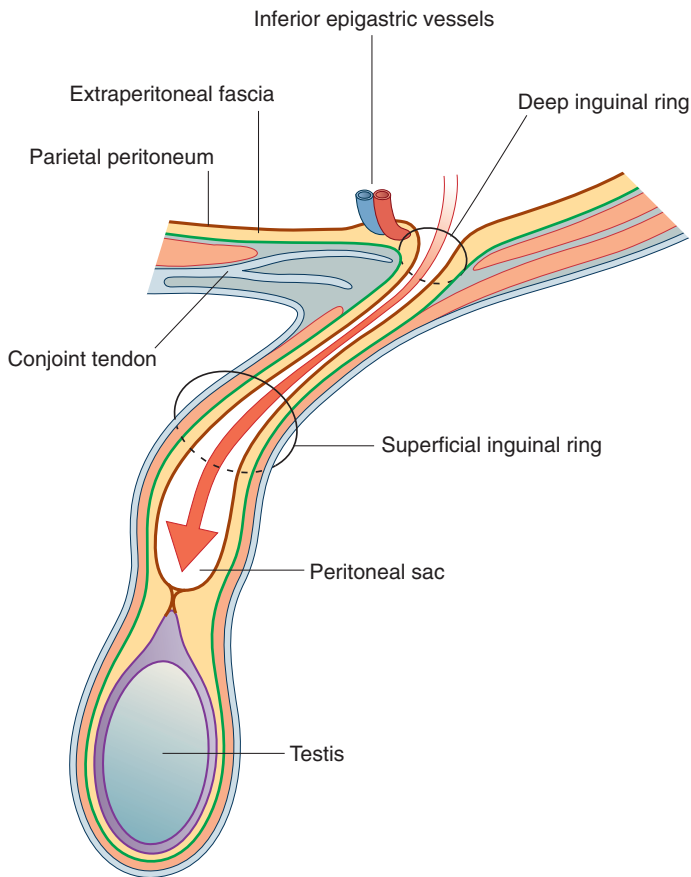
IN THE CLINIC:

- The figure indicates how pain from the heart is referred to the chest and upper limb on the left side. Visceral pain impulses from the heart enter the spinal cord mainly at spinal cord levels T2 to T4. These fibers synapse with interneurons in the cord that also receive impulses from somatic sensory nerves from the skin that enter at the same spinal cord levels. The central nervous system interprets the input from the heart as coming from skin.

Figure from Gray's Anatomy for Students, 3rd edition, p. 244.



What type of inguinal hernia is indicated in the figure?





INGUINAL HERNIA I



This is an indirect inguinal hernia.

IN THE CLINIC:

- **An indirect inguinal hernia follows the contents of the spermatic cord through the deep (internal) inguinal ring and inguinal canal. The neck of the hernia is lateral to the inferior epigastric vessels.**

Figure from Gray's Anatomy for Students, 3rd edition, p. 299.



What type of inguinal hernia is indicated in the figure?

Inferior epigastric vessels

Deep inguinal ring

Extraperitoneal fascia

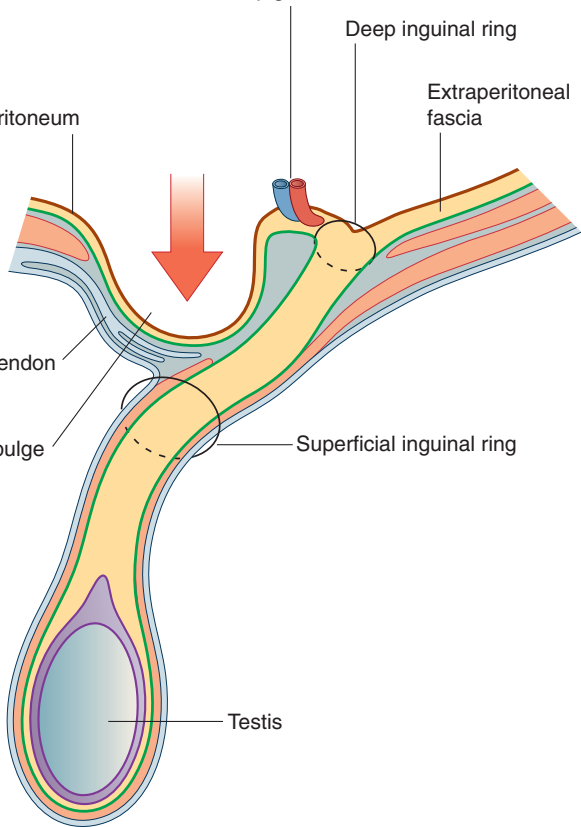
Parietal peritoneum

Conjoint tendon

Peritoneal bulge

Superficial inguinal ring

Testis





INGUINAL HERNIA II



This is a direct inguinal hernia.

IN THE CLINIC:

- A direct inguinal hernia protrudes anteriorly through a weakened posterior wall (conjoint tendon) of the inguinal canal immediately behind the superficial (external) inguinal ring. In this location, the neck of the hernia is medial to the inferior epigastric vessels.

Figure from Gray's Anatomy for Students, 3rd edition, p. 300.



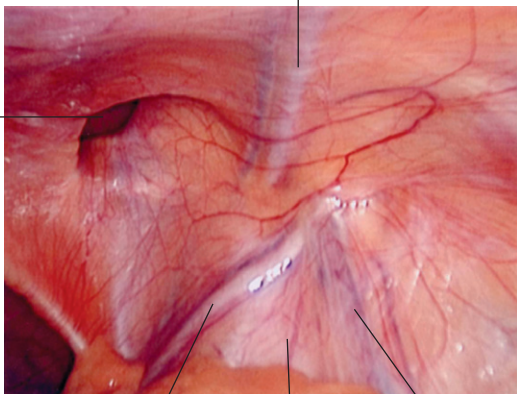
INGUINAL HERNIA III

What type of inguinal hernia is indicated by the asterisk in the figure?

Inferior
epigastric vessels

Medial

Lateral



Ductus
deferens

External
iliac vessels

Testicular
vessels



INGUINAL HERNIA III



This is a direct inguinal hernia.

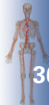IN THE CLINIC:

- A direct inguinal hernia protrudes anteriorly through a weakened posterior wall (conjoint tendon) of the inguinal canal immediately behind the superficial (external) inguinal ring. In this location, the neck of the hernia is medial to the inferior epigastric vessels.

Figure from Gray's Anatomy for Students, 3rd edition, p. 301.

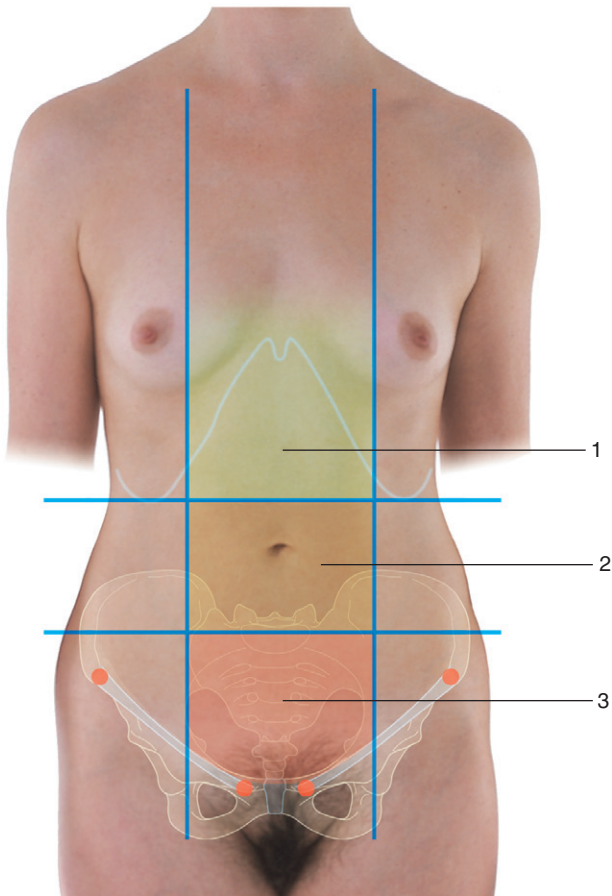


REFERRED ABDOMINAL PAIN



360

Pain from what parts of the gastrointestinal system are referred to the indicated regions?





REFERRED ABDOMINAL PAIN



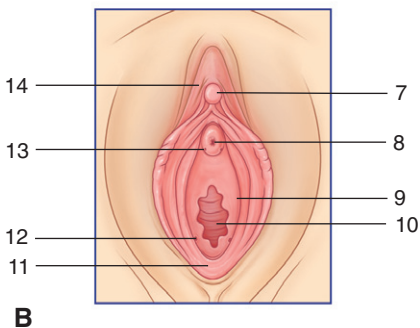
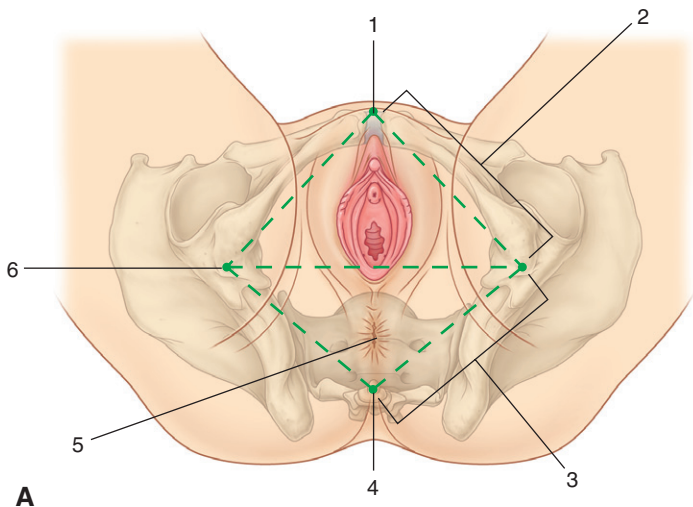
1. Foregut
2. Midgut
3. Hindgut

Figure from Gray's Anatomy for Students, 3rd edition, p. 408.



FEMALE PERINEUM

Identify the indicated features.





FEMALE PERINEUM



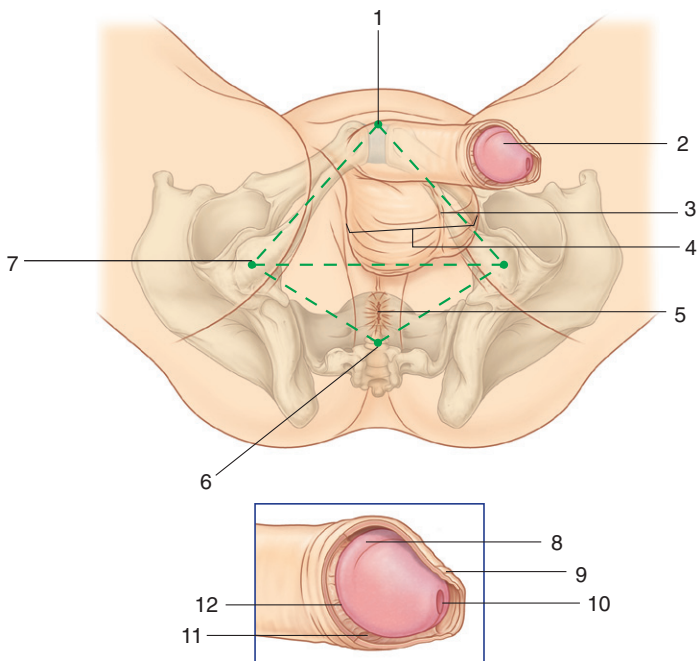
1. Pubic symphysis
2. Urogenital triangle
3. Anal triangle
4. Coccyx
5. Anal aperture
6. Ischial tuberosity
7. Glans clitoris
8. Urethral opening
9. Hymen
10. Vaginal opening
11. Fourchette
12. Opening of duct of greater vestibular gland
13. Opening of duct of para-urethral gland
14. Prepuce of clitoris

IN THE CLINIC:

- The pubic symphysis, ischial tuberosities, and coccyx can all be palpated easily in a patient. An imaginary line between the ischial tuberosities divides the diamond-shaped perineum into an anterior urogenital triangle and a posterior anal triangle.

Figure from Gray's Anatomy for Students, 3rd edition, p. 510.

Identify the indicated features.





MALE PERINEUM



1. Pubic symphysis
2. Glans penis
3. Raphe
4. Scrotum
5. Anal aperture
6. Coccyx
7. Ischial tuberosity
8. Corona of glans
9. Prepuce
10. External urethral orifice
11. Frenulum of glans
12. Neck of glans

IN THE CLINIC:

- **The pubic symphysis, ischial tuberosities, and coccyx can all be palpated easily in a patient. An imaginary line between the ischial tuberosities divides the diamond-shaped perineum into an anterior urogenital triangle and a posterior anal triangle.**

Figure from Gray's Anatomy for Students, 3rd edition, p. 511.

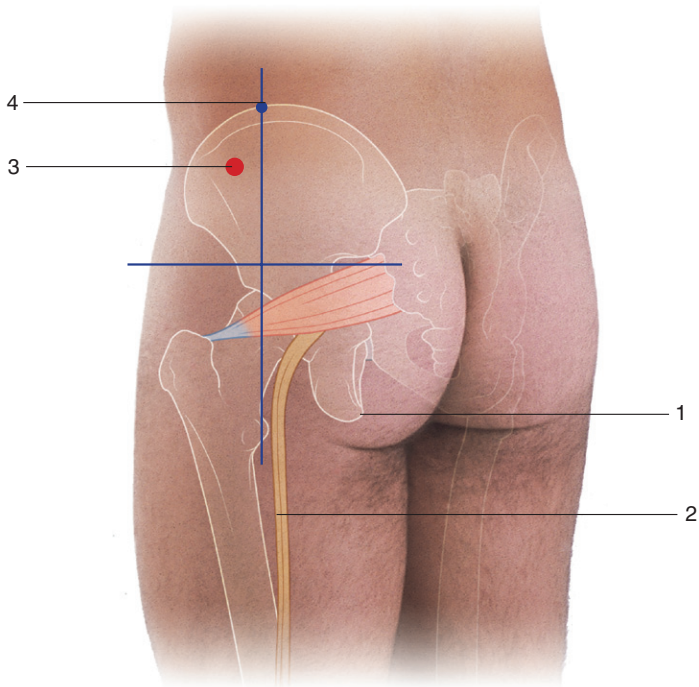


GLUTEAL INJECTION SITE



363

Identify the indicated structures.





GLUTEAL INJECTION SITE



1. Ischial tuberosity
2. Sciatic nerve
3. Safe injection site
4. Highest point on iliac crest

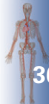IN THE CLINIC:

- The gluteal region can be divided into quadrants by two lines positioned using palpable bony landmarks. One line descends vertically from the highest point of the iliac crest. The other line passes horizontally through the first line midway between the highest point of the iliac crest and the horizontal plane through the ischial tuberosity. Injections can be carried out in the anterior corner of the upper lateral quadrant to avoid injury to the sciatic nerve and other structures in the region.

Figure from Gray's Anatomy for Students, 3rd edition, p. 663.

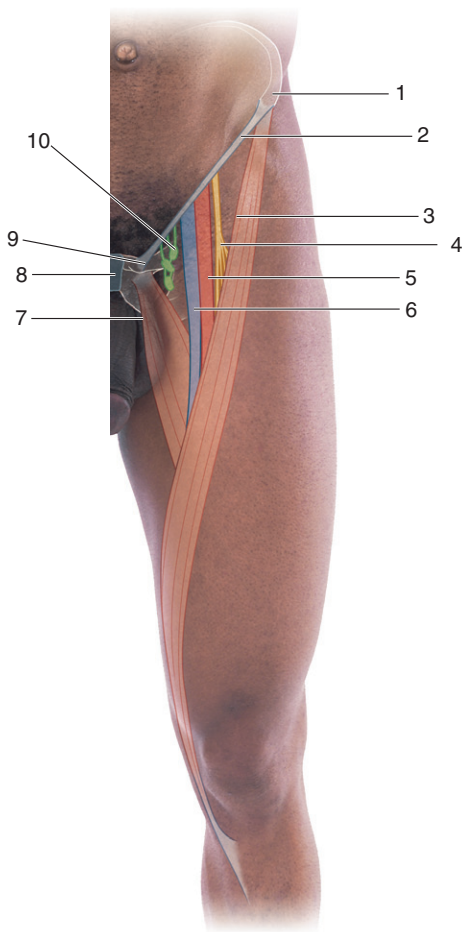


FEMORAL TRIANGLE SURFACE ANATOMY



364

Identify the indicated structures.





FEMORAL TRIANGLE SURFACE ANATOMY



1. Anterior superior iliac spine
2. Inguinal ligament
3. Medial margin of sartorius muscle
4. Femoral nerve
5. Femoral artery
6. Femoral vein
7. Medial margin of adductor longus muscle
8. Pubic symphysis
9. Pubic tubercle
10. Lymphatics passing through femoral canal

IN THE CLINIC:

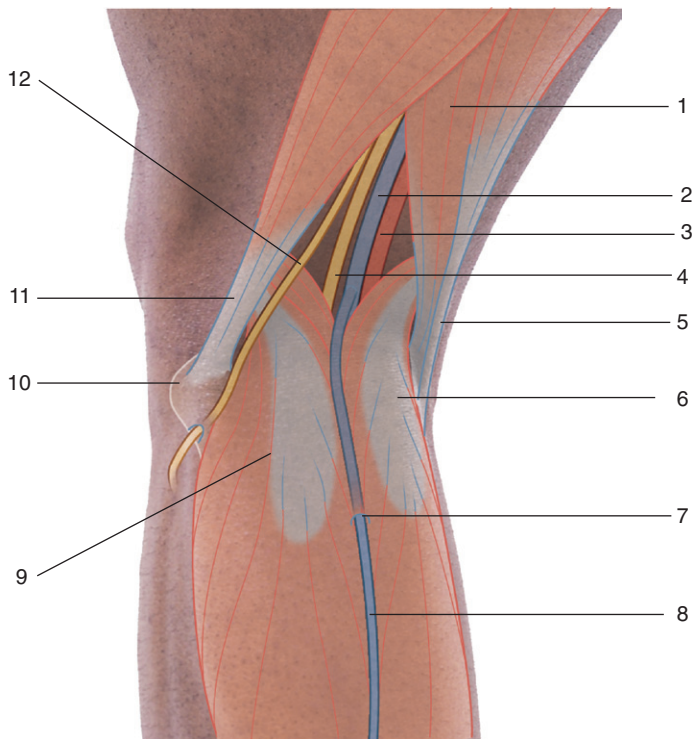
- **The pulse of the femoral artery can be felt midway between the pubic symphysis and anterior superior iliac spine just inferior to the inguinal ligament.**

Figure from Gray's Anatomy for Students, 3rd edition, p. 664.



POPLITEAL FOSSA

Identify the indicated structures.





POPLITEAL FOSSA



1. Semimembranosus muscle
2. Popliteal vein
3. Popliteal artery
4. Tibial nerve
5. Semitendinosus tendon
6. Medial head of gastrocnemius muscle
7. Small saphenous vein penetrating deep fascia
8. Small saphenous vein
9. Lateral head of gastrocnemius muscle
10. Head of fibula
11. Biceps femoris muscle and tendon
12. Common fibular nerve

IN THE CLINIC:

- **The pulse of the popliteal artery can be felt by deep palpation just medial to the midline in the popliteal fossa.**

Figure from Gray's Anatomy for Students, 3rd edition, p. 666.

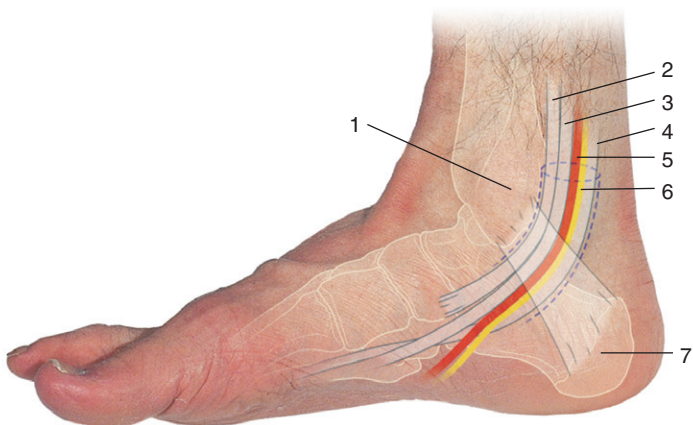


TARSAL TUNNEL



366

Identify the indicated structures.





TARSAL TUNNEL



1. Medial malleolus
2. Tibialis posterior tendon
3. Flexor digitorum longus tendon
4. Flexor hallucis longus tendon
5. Posterior tibial artery
6. Tibial nerve
7. Calcaneus

IN THE CLINIC:

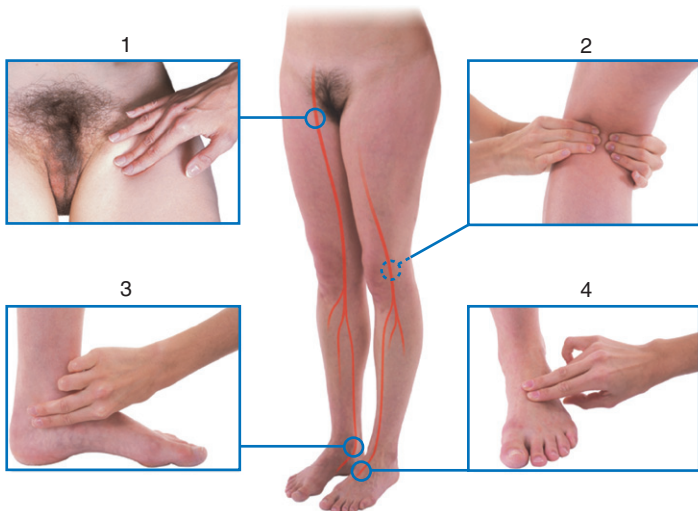
- **The pulse of the posterior tibial artery can be felt approximately midway between the medial malleolus and heel.**

Figure from Gray's Anatomy for Students, 3rd edition, p. 667.



LOWER LIMB PULSE POINTS

The pulses of which arteries can be palpated at each of the indicated sites?





LOWER LIMB PULSE POINTS



1. Femoral
2. Popliteal
3. Posterior tibial
4. Dorsalis pedis

Figure from Gray's Anatomy for Students, 3rd edition, p. 671.

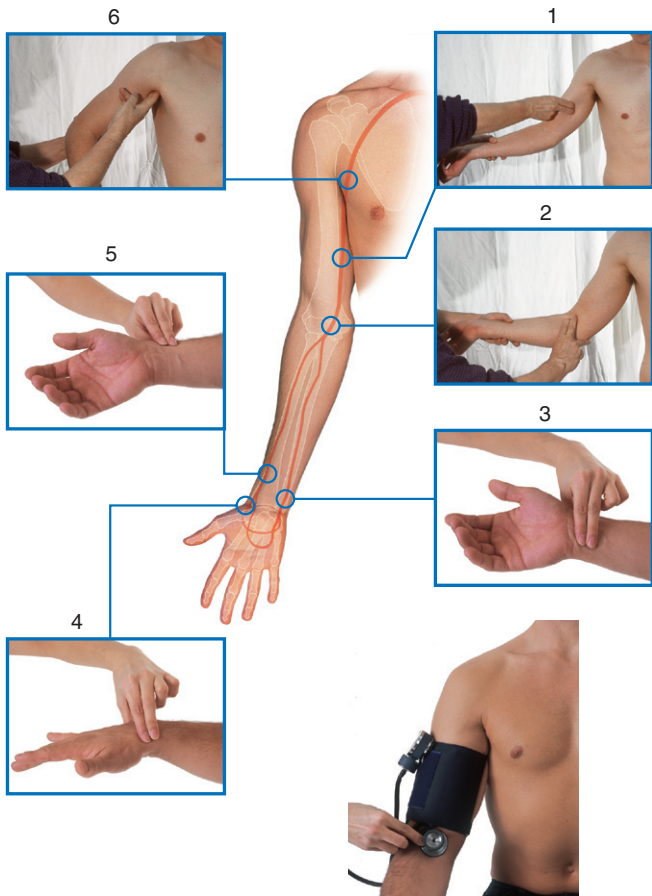


UPPER LIMB PULSE POINTS



368

The pulses of which arteries can be palpated at each of the indicated sites?





UPPER LIMB PULSE POINTS



1. Brachial
2. Brachial
3. Ulnar
4. Radial
5. Radial
6. Axillary

Figure from Gray's Anatomy for Students, 3rd edition, p. 828.



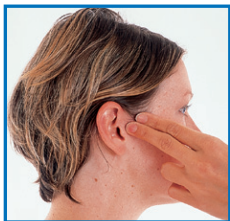HEAD AND NECK PULSE POINTS



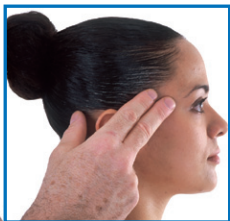369

The pulses of which arteries can be palpated at each of the indicated sites?

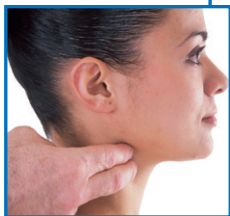4



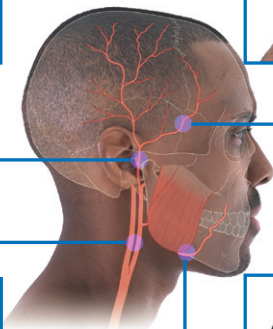
1



3



2





HEAD AND NECK PULSE POINTS



1. Anterior branch of superficial temporal artery
2. Facial artery
3. Common carotid artery
4. Superficial temporal artery

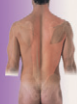Figure from Gray's Anatomy for Students, 3rd edition, p. 1128.



SECTION 10: NERVOUS SYSTEM



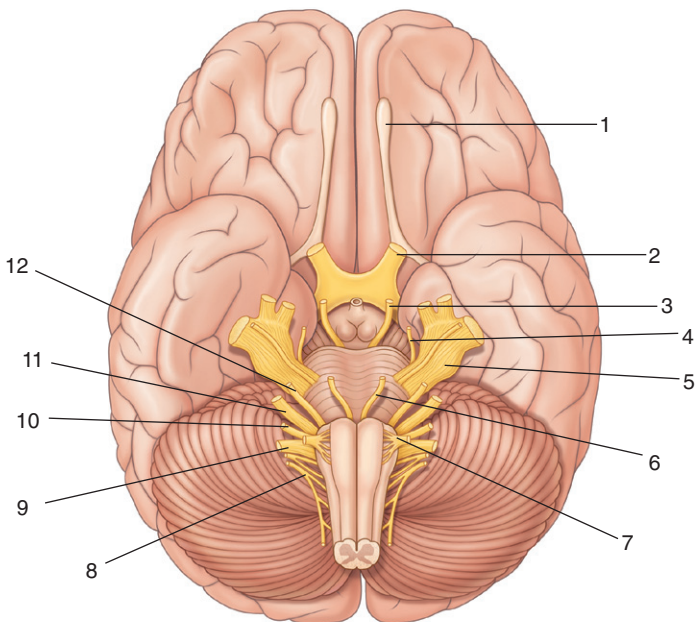
- 370. Brain: Base of Brain Cranial Nerves
- 371. Spinal Cord
- 372. Spinal Nerve
- 373. Heart Sympathetics
- 374. Gastrointestinal Sympathetics
- 375. Parasympathetics
- 376. Parasympathetic Ganglia
- 377. Pelvic Autonomics



BRAIN:
BASE OF BRAIN CRANIAL NERVES



Identify the indicated cranial nerves in this inferior view of the brain.





BRAIN: BASE OF BRAIN CRANIAL NERVES



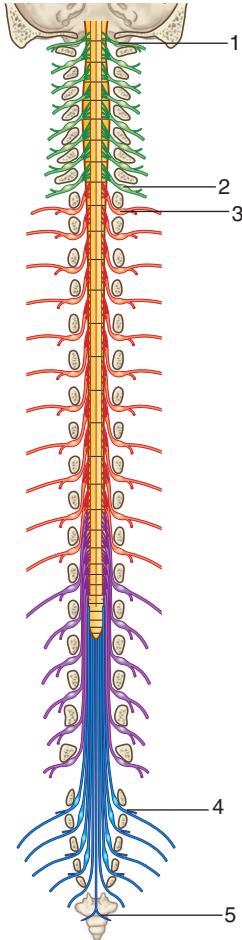
1. Olfactory bulb (the olfactory nerve [I] connects with this structure)
2. Optic nerve (II)
3. Oculomotor nerve (III)
4. Trochlear nerve (IV)
5. Trigeminal nerve (V)
6. Abducent nerve (VI)
7. Hypoglossal nerve (XII)
8. Accessory nerve (XI)
9. Vagus nerve (X)
10. Glossopharyngeal nerve (IX)
11. Vestibulocochlear nerve (VIII)
12. Facial nerve (VII)

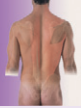Figure from Gray's Anatomy for Students, 3rd edition, p. 897.

SPINAL CORD

371

Identify the indicated spinal nerves.





SPINAL CORD



1. C1
2. C8
3. T1
4. S1
5. Co

Figure from Gray's Anatomy for Students, 3rd edition, p. 108.

The diagram illustrates the pathways of afferent and efferent fibers within a spinal cord segment. The central structure is the spinal cord, shown in cross-section. The dorsal horn is the posterior part, and the ventral horn is the anterior part. The dorsal root ganglion is located on the dorsal root. The ventral root is the anterior root. The dorsal root is labeled 1, the dorsal root ganglion is 2, the dorsal horn is 3, the ventral horn is 4, the ventral root is 5, and the ventral root ganglion is 6. The afferent fibers (red) enter the dorsal root and ascend to the dorsal horn. The efferent fibers (blue) exit the ventral root and descend to the ventral horn. The diagram also shows the pathways of the afferent and efferent fibers within the spinal cord, including the dorsal horn, ventral horn, and the exit points for sensory and motor fibers. The afferent fibers enter the dorsal root and ascend to the dorsal horn. The efferent fibers exit the ventral root and descend to the ventral horn. The diagram illustrates the complex circuitry of the spinal cord, including the dorsal horn, ventral horn, and the exit points for sensory and motor fibers.



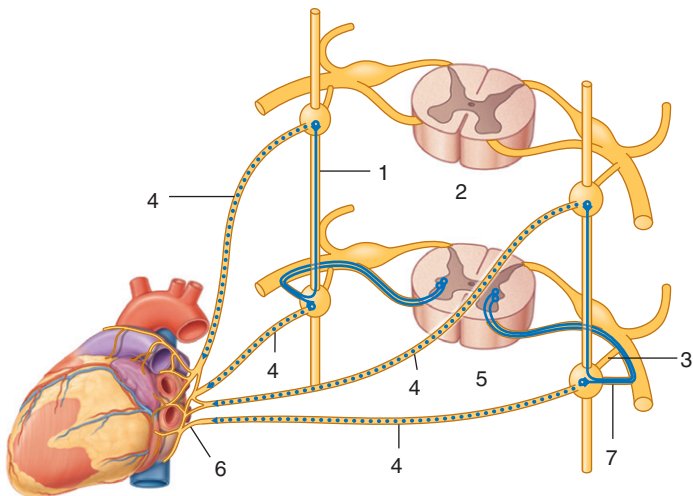
SPINAL NERVE



1. Posterior root
2. Spinal ganglion
3. Anterior ramus
4. Anterior rootlets
5. Somatic motor fiber
6. Posterior ramus
7. Spinal nerve
8. Anterior root
9. Somatic sensory fiber
10. Posterior rootlets

Figure from Gray's Anatomy for Students, 3rd edition, p. 107.

Identify the indicated structures involved in the sympathetic innervation of the heart.





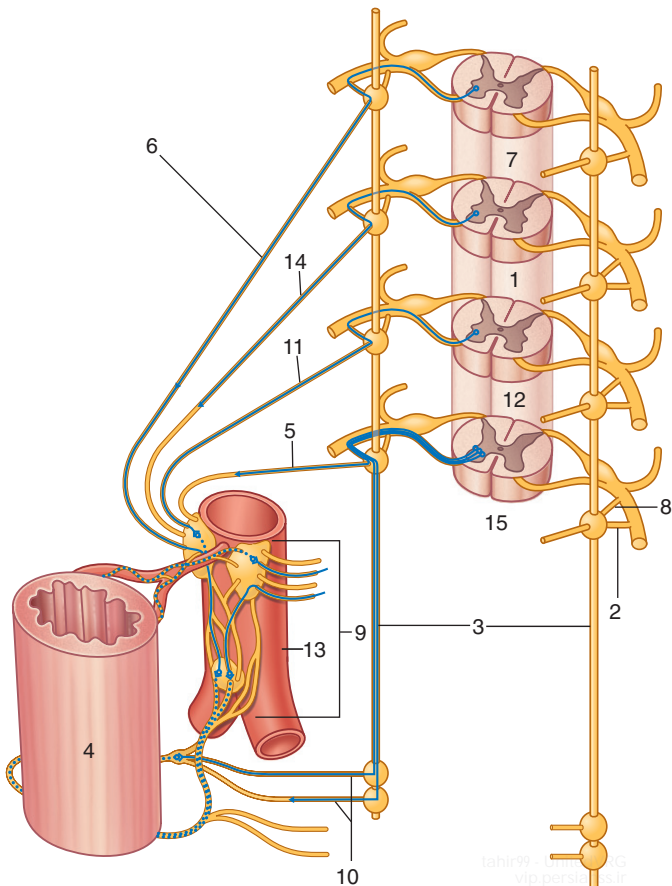
HEART SYMPATHETICS



1. Sympathetic trunk
2. Cervical spinal cord
3. Gray ramus communicans
4. Sympathetic cardiac nerves
5. T1 to T4 spinal cord levels
6. Cardiac plexus
7. White ramus communicans

Figure from Gray's Anatomy for Students, 3rd edition, p. 43.

tahir99 - UnitedRG
vip.persianss.ir



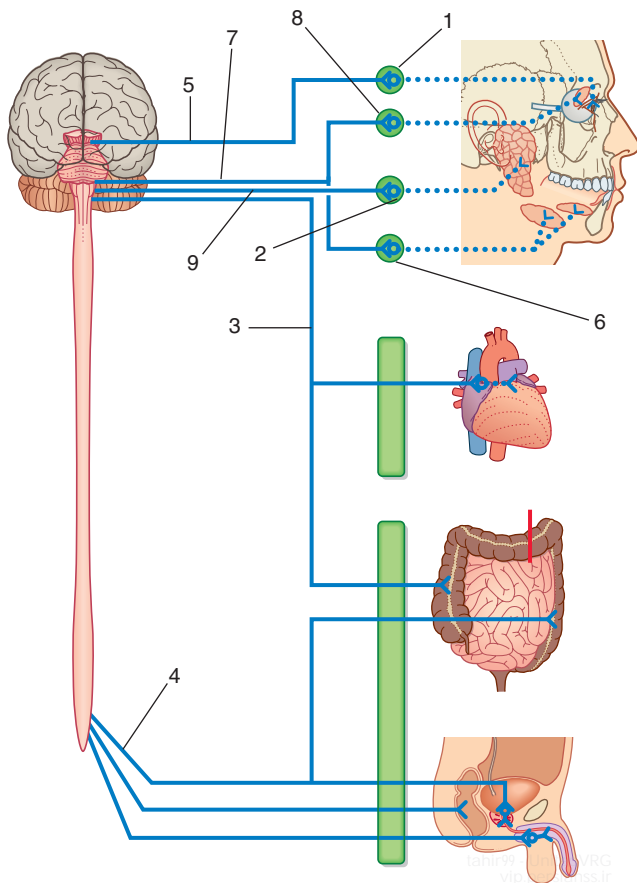


GASTROINTESTINAL SYMPATHETICS

1. T9 to T10 spinal cord levels
2. White ramus communicans
3. Paravertebral sympathetic trunks
4. Abdominal and pelvic viscera
5. Lumbar splanchnic nerve
6. Greater splanchnic nerve
7. T5 to T9 spinal cord levels
8. Gray ramus communicans
9. Prevertebral plexus and ganglia
10. Sacral splanchnic nerves
11. Least splanchnic nerve
12. T12 spinal cord level
13. Abdominal aorta
14. Lesser splanchnic nerve
15. L1 to L2 spinal cord levels

Figure from Gray's Anatomy for Students, 3rd edition, p. 44.

Identify the indicated components of the parasympathetic part of the peripheral nervous system.





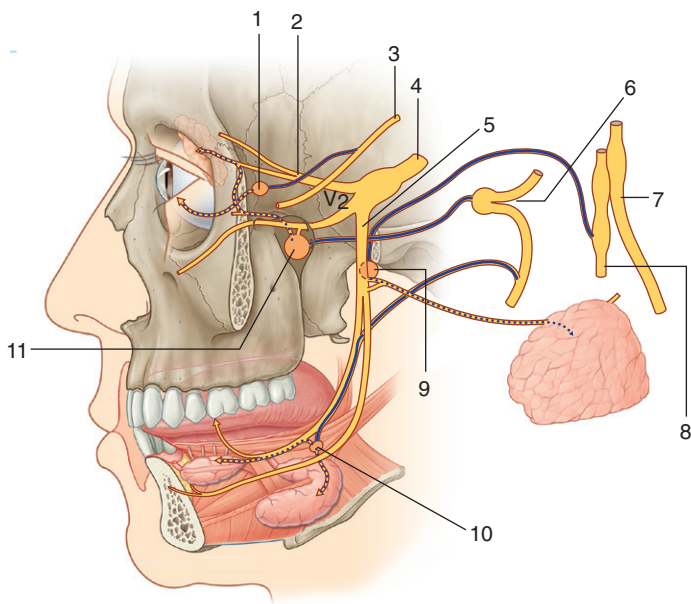
PARASYMPATHETICS



1. Ciliary ganglion
2. Otic ganglion
3. Vagus nerve (X)
4. Pelvic splanchnic nerves from S2 to S4 spinal nerves
5. Oculomotor nerve (III)
6. Submandibular ganglion
7. Facial nerve (VII)
8. Pterygopalatine ganglion
9. Glossopharyngeal nerve (IX)

Figure from Gray's Anatomy for Students, 3rd edition, p. 45.

Identify the indicated structures related to the parasympathetic innervation of the head.



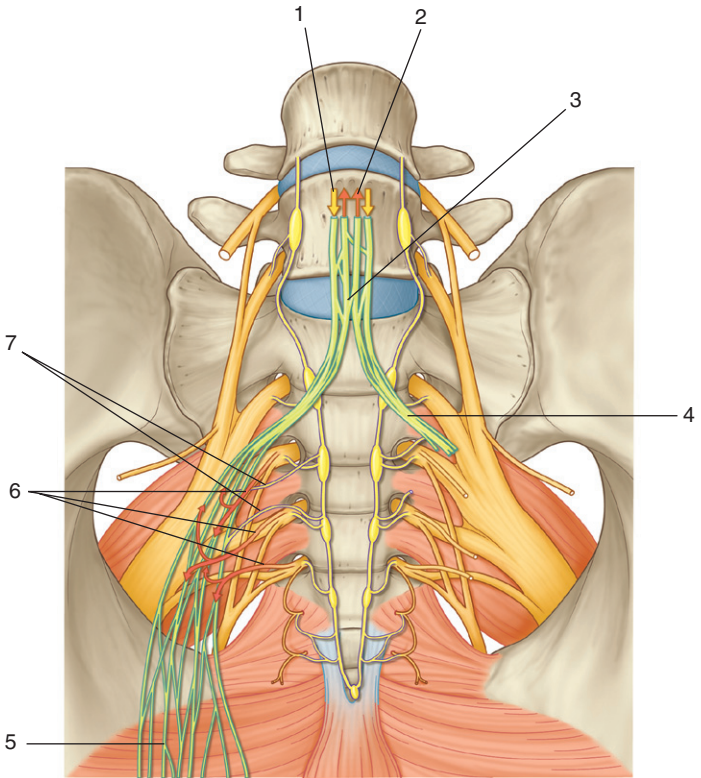


PARASYMPATHETIC GANGLIA

1. Ciliary ganglion
2. Ophthalmic nerve (V_1)
3. Oculomotor nerve (III)
4. Trigeminal nerve (V)
5. Mandibular nerve (V_3)
6. Facial nerve (VII)
7. Vagus nerve (X)
8. Glossopharyngeal nerve (IX)
9. Otic ganglion
10. Submandibular ganglion
11. Pterygopalatine ganglion

Figure from Gray's Anatomy for Students, 3rd edition, p. 850.

Identify the indicated structures related to the parasympathetic and sympathetic innervation of pelvic structures.





PELVIC AUTONOMICS

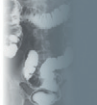

1. Sympathetics descending from above
2. Pelvic parasympathetics ascending
3. Superior hypogastric plexus
4. Hypogastric nerve
5. Inferior hypogastric plexus
6. Pelvic splanchnic nerves (parasympathetics from S2 to S4)
7. Sacral splanchnic nerves (sympathetics descending from above in sympathetic trunk)

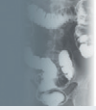Figure from Gray's Anatomy for Students, 3rd edition, p. 492.



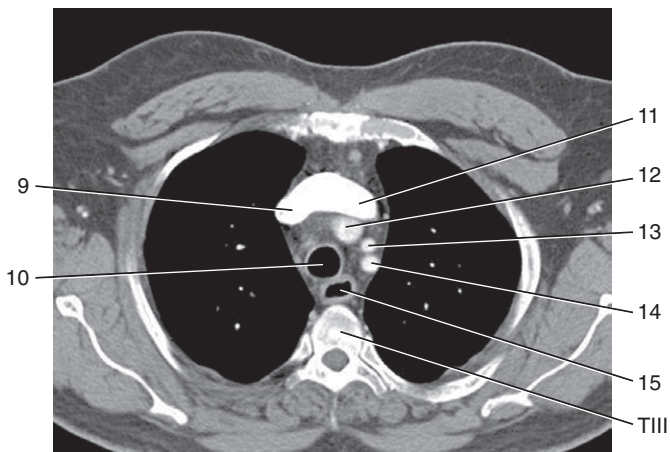
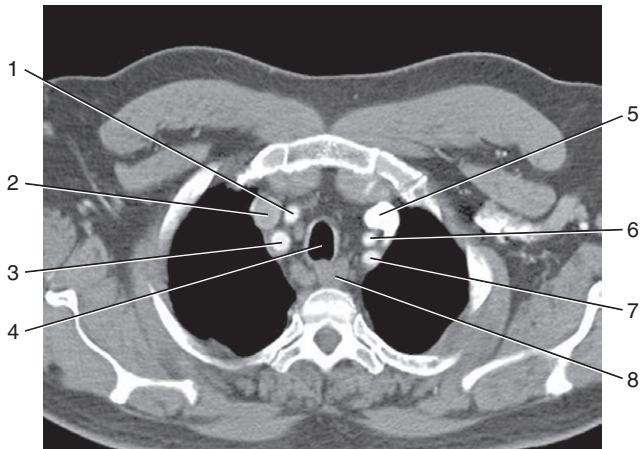
SECTION 11: IMAGING



- 378. Mediastinum: CT Images, Axial Plane
- 379. Mediastinum: CT Images, Axial Plane
- 380. Mediastinum: CT Images, Axial Plane
- 381. Stomach and Duodenum: Double-Contrast Radiograph
- 382. Jejunum and Ileum: Radiograph
- 383. Large Intestine: Radiograph, Using Barium
- 384. Liver: Abdominal CT Scan with Contrast, in Axial Plane
- 385. Pancreas: Abdominal CT Scan with Contrast, in Axial Plane
- 386. Male Pelvic Cavity and Perineum: T2-Weighted MR Images, in Axial Plane
- 387. Male Pelvic Cavity and Perineum: T2-Weighted MR Images, in Axial Plane
- 388. Female Pelvic Cavity and Perineum: T2-Weighted MR Images, in Sagittal Plane
- 389. Female Pelvic Cavity and Perineum: T2-Weighted MR Images, in Coronal Plane
- 390. Female Pelvic Cavity and Perineum: T2-Weighted MR Images, in Axial Plane
- 391. Female Pelvic Cavity and Perineum: T2-Weighted MR Images, in Axial Plane



Identify the indicated structures.





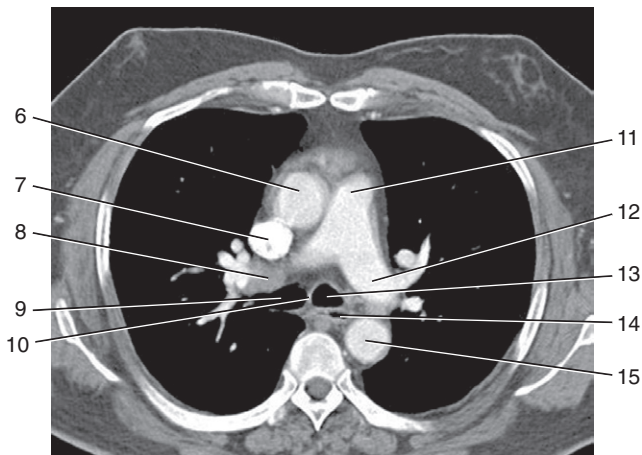
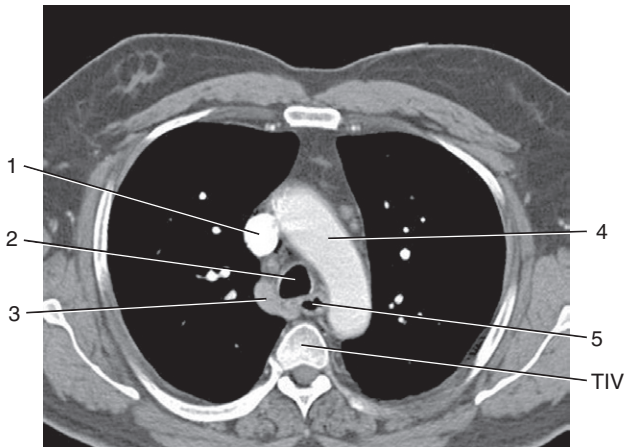
MEDIASTINUM: CT IMAGES, AXIAL PLANE



1. Right common carotid artery
2. Right brachiocephalic vein
3. Right subclavian artery
4. Trachea
5. Left brachiocephalic vein
6. Left common carotid artery
7. Left subclavian artery
8. Esophagus
9. Right brachiocephalic vein
10. Trachea
11. Left brachiocephalic vein
12. Brachiocephalic trunk
13. Left common carotid artery
14. Left subclavian artery
15. Esophagus



Identify the indicated structures.





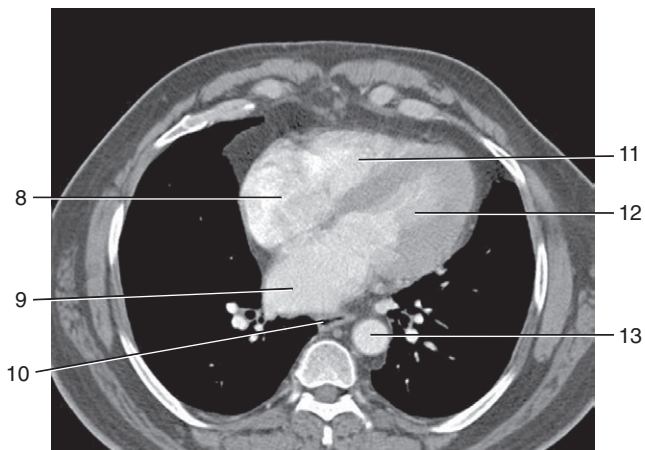
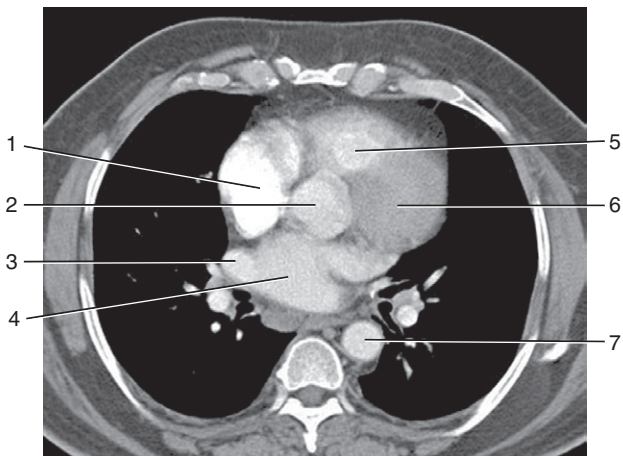
MEDIASTINUM: CT IMAGES, AXIAL PLANE



1. Superior vena cava
2. Trachea
3. Azygos vein
4. Arch of aorta
5. Esophagus
6. Ascending aorta
7. Superior vena cava
8. Right pulmonary artery
9. Right main bronchus
10. Carina
11. Pulmonary trunk
12. Left pulmonary artery
13. Left main bronchus
14. Esophagus
15. Thoracic aorta



Identify the indicated structures.



MEDIASTINUM: CT IMAGES, AXIAL PLANE



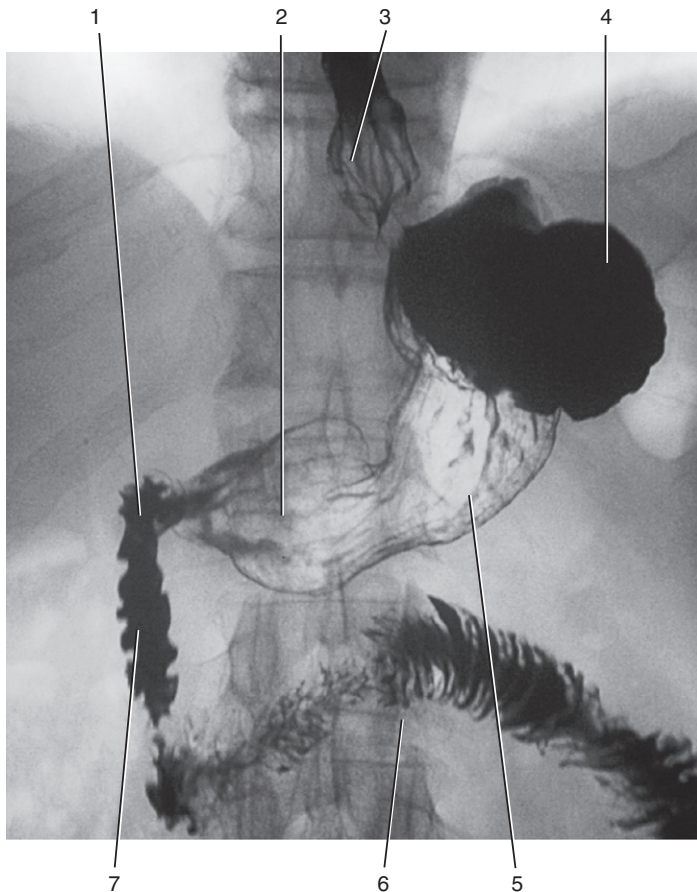
1. Right atrium
2. Ascending aorta
3. Right pulmonary vein
4. Left atrium
5. Right ventricle
6. Left ventricle
7. Thoracic aorta
8. Right atrium
9. Left atrium
10. Esophagus
11. Right ventricle
12. Left ventricle
13. Thoracic aorta

Figure from Gray's Basic Anatomy, p. 132.

**STOMACH AND DUODENUM:
DOUBLE-CONTRAST RADIOGRAPH**

381

Identify the indicated structures.





STOMACH AND DUODENUM: DOUBLE-CONTRAST RADIOGRAPH

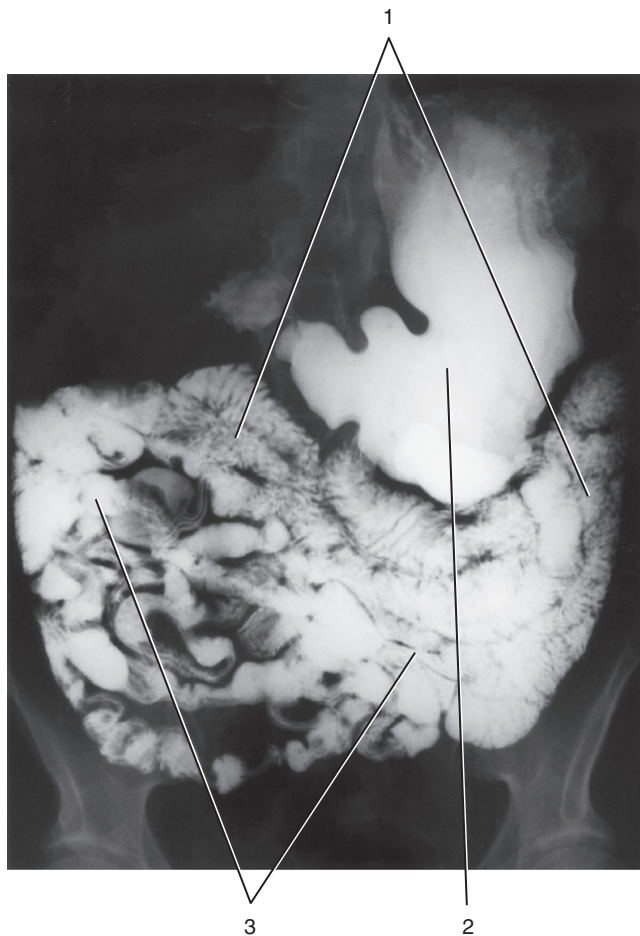


1. Superior part of duodenum
2. Pyloric antrum
3. Esophagus
4. Fundus of stomach
5. Body of stomach
6. Duodenal jejunal flexure
7. Descending part of duodenum

Figure from Gray's Basic Anatomy, p. 154.



Identify the indicated structures.





JEJUNUM AND ILEUM: RADIOGRAPH

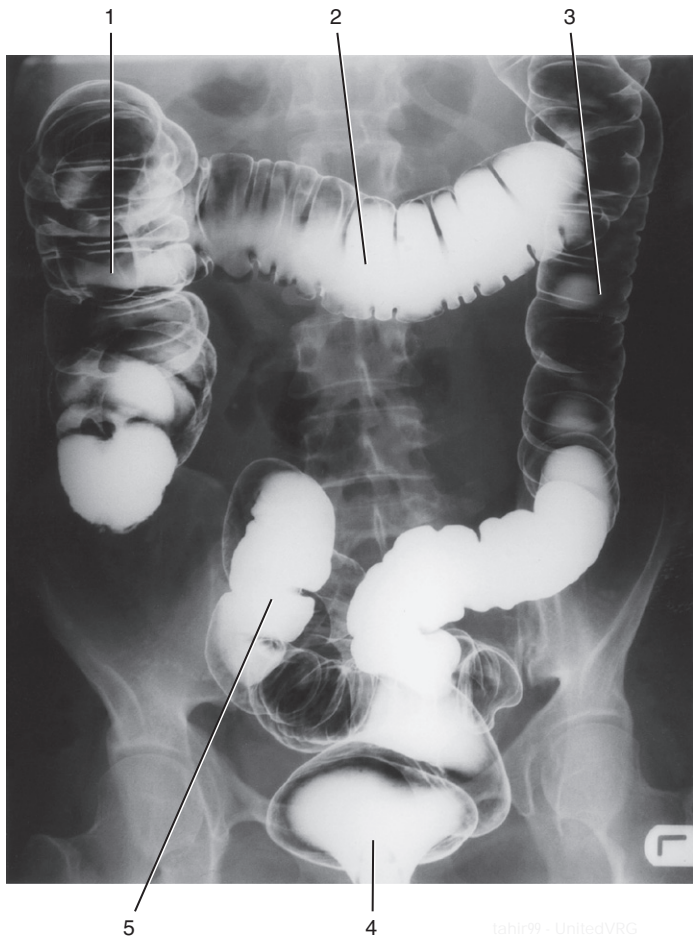


1. Jejunum
2. Stomach
3. Ileum

**LARGE INTESTINE:
RADIOGRAPH, USING BARIUM**

383

Identify the indicated structures.





LARGE INTESTINE: RADIOGRAPH, USING BARIUM



1. Ascending colon
2. Transverse colon
3. Descending colon
4. Rectum
5. Sigmoid colon

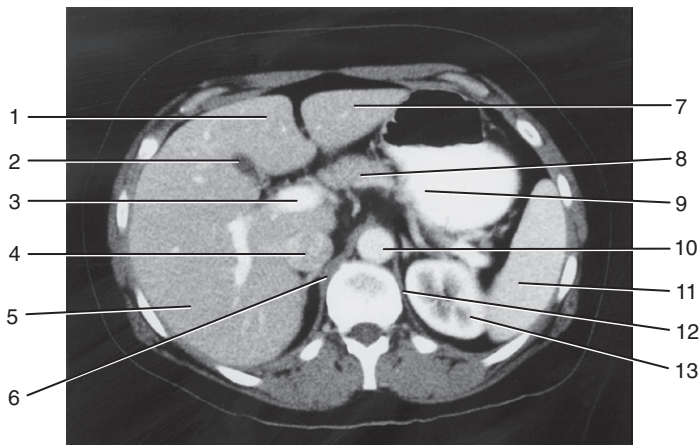
Figure from Gray's Basic Anatomy, p. 159.



LIVER: ABDOMINAL CT SCAN WITH CONTRAST, IN AXIAL PLANE

384

Identify the indicated structures.



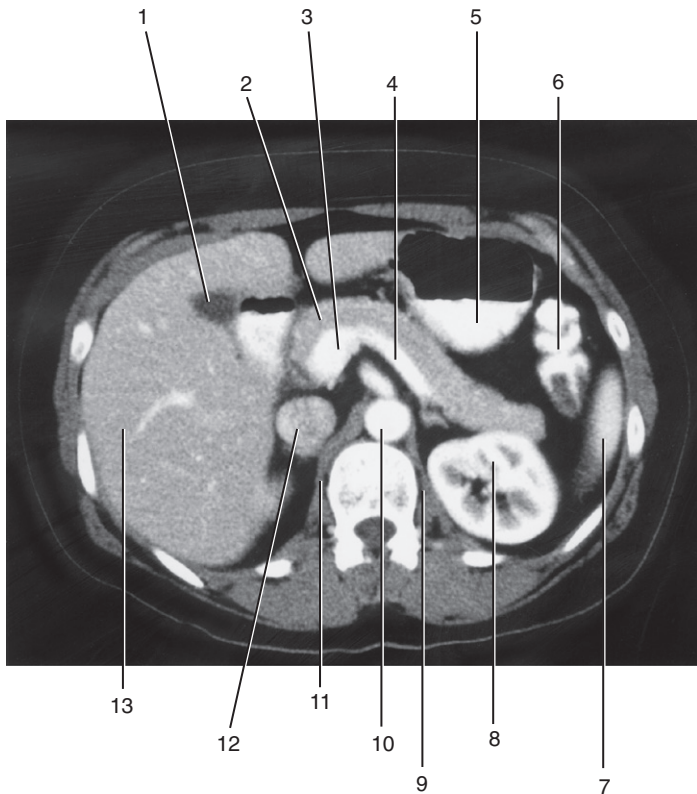
LIVER: ABDOMINAL CT SCAN WITH CONTRAST, IN AXIAL PLANE



1. Quadrate lobe
2. Gallbladder
3. Portal vein
4. Inferior vena cava
5. Right lobe of liver
6. Right crus
7. Left lobe of liver
8. Neck of pancreas
9. Stomach
10. Aorta
11. Spleen
12. Left crus
13. Left kidney

Figure from Gray's Basic Anatomy, p. 166.

Identify the indicated structures.



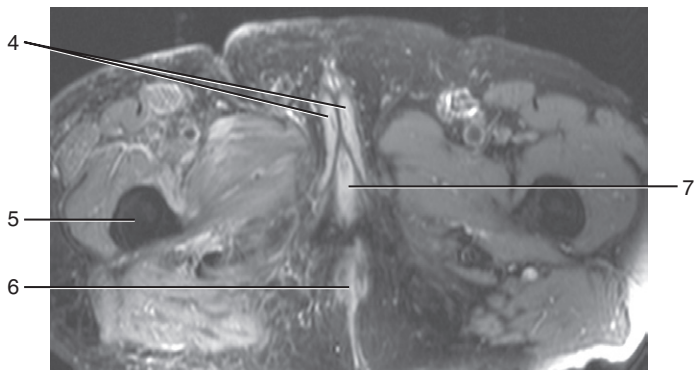
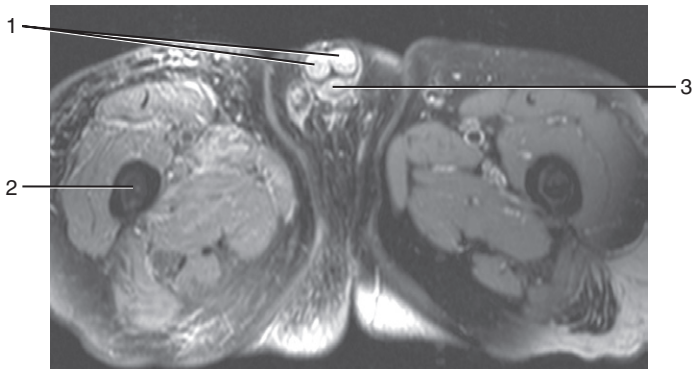
PANCREAS: ABDOMINAL CT SCAN WITH CONTRAST, IN AXIAL PLANE



1. Gallbladder
2. Pancreas
3. Portal vein
4. Splenic vein
5. Stomach
6. Left colonic flexure
7. Spleen
8. Left kidney
9. Left crus
10. Aorta
11. Right crus
12. Inferior vena cava
13. Right lobe of liver

Figure from Gray's Basic Anatomy, p. 169.

Identify the indicated structures.





MALE PELVIC CAVITY AND PERINEUM: T2-WEIGHTED MR IMAGES, IN AXIAL PLANE



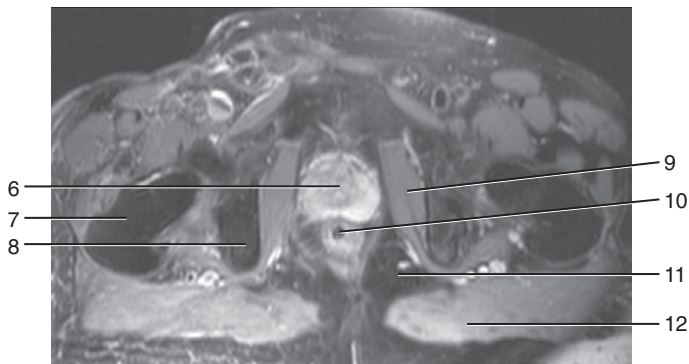
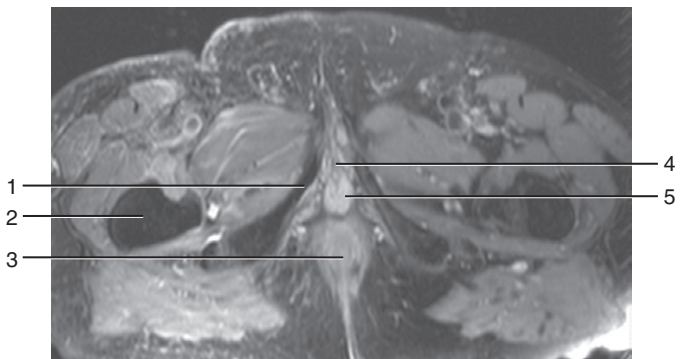
1. Corpora cavernosa
2. Femur
3. Corpus spongiosum
4. Corpora cavernosa and crura of penis
5. Femur
6. Anus
7. Corpus spongiosum and bulb of penis

Figures from Gray's Basic Anatomy, p. 256.

**MALE PELVIC CAVITY AND PERINEUM:
T2-WEIGHTED MR IMAGES, IN AXIAL PLANE**

387

Identify the indicated structures.



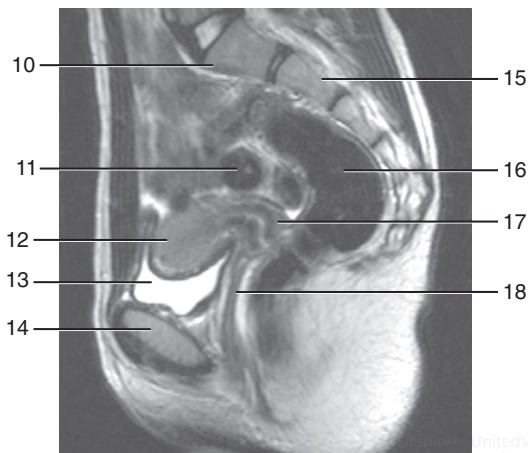
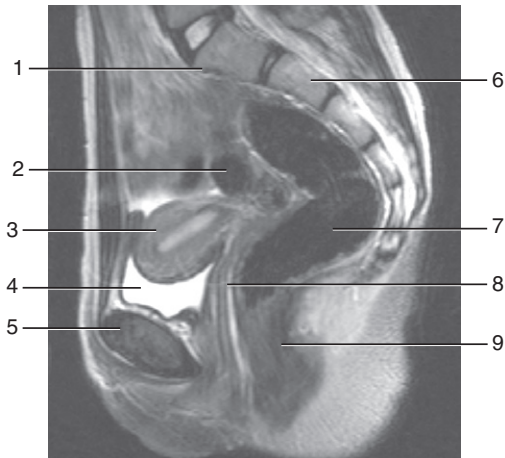
MALE PELVIC CAVITY AND PERINEUM: T2-WEIGHTED MR IMAGES, IN AXIAL PLANE



1. Ischiopubic ramus
2. Femur
3. Anal canal
4. Urethra
5. Bulb of penis
6. Prostate
7. Femur
8. Ischial tuberosity
9. Obturator internus
10. Anal canal
11. Ischio-anal fossa
12. Gluteus maximus

Figures from Gray's Basic Anatomy, pp. 257 and 258.

Identify the indicated structures.





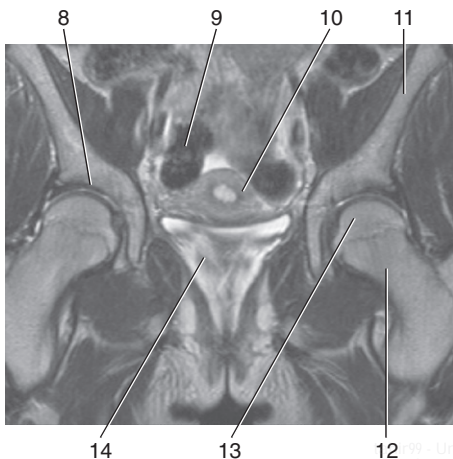
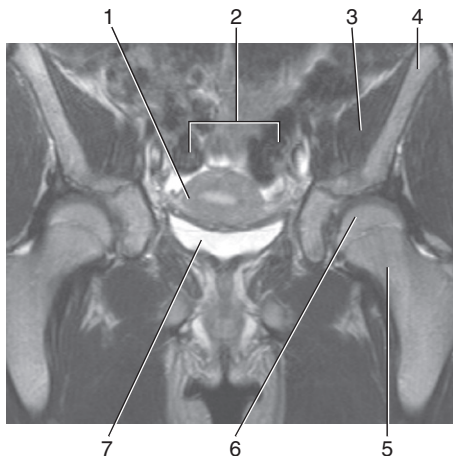
FEMALE PELVIC CAVITY AND PERINEUM: T2-WEIGHTED MR IMAGES, IN SAGITTAL PLANE



1. Sacral promontory
2. Small intestine
3. Uterus
4. Bladder
5. Pubis
6. Sacrum
7. Rectum
8. Vagina
9. Anal canal
10. Sacral promontory
11. Small intestine
12. Uterus
13. Bladder
14. Pubis
15. Sacrum
16. Rectum
17. Cervix
18. Vagina

Figures from Gray's Basic Anatomy, p. 259.

Identify the indicated structures.





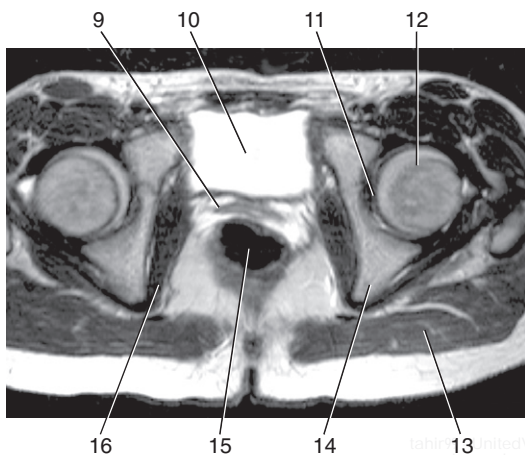
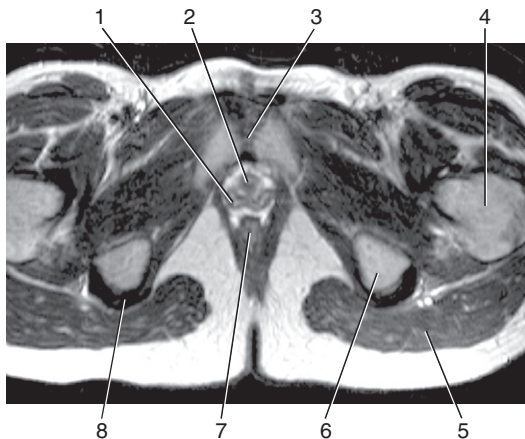
FEMALE PELVIC CAVITY AND PERINEUM: T2-WEIGHTED MR IMAGES, IN CORONAL PLANE



1. Uterus
2. Small intestine
3. Iliacus
4. Ilium
5. Neck of femur
6. Head of femur
7. Bladder
8. Acetabulum
9. Small intestine
10. Uterus
11. Ilium
12. Neck of femur
13. Head of femur
14. Bladder

Figures from Gray's Basic Anatomy, pp. 261 and 262.

Identify the indicated structures.



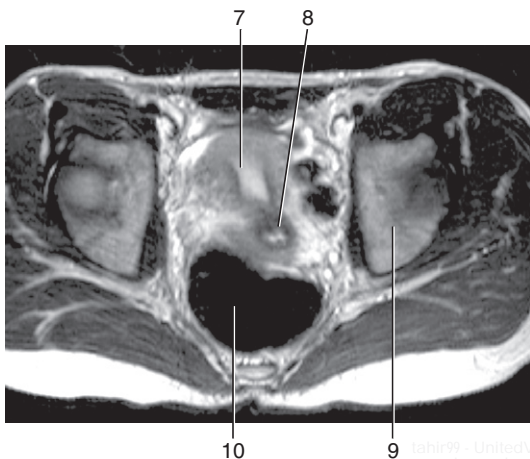
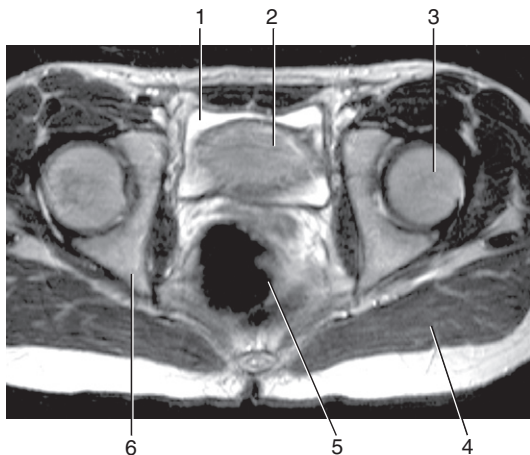
FEMALE PELVIC CAVITY AND PERINEUM: T2-WEIGHTED MR IMAGES, IN AXIAL PLANE



1. Vagina
2. Urethra
3. Pubic symphysis
4. Femur
5. Gluteus maximus
6. Ischial tuberosity
7. Anus
8. Obturator internus (passing thorough lesser sciatic foramen)
9. Vagina
10. Bladder
11. Acetabulum
12. Head of femur
13. Gluteus maximus
14. Ischium
15. Rectum
16. Obturator internus

Figures from Gray's Basic Anatomy, p. 262.

Identify the indicated structures.



FEMALE PELVIC CAVITY AND PERINEUM: T2-WEIGHTED MR IMAGES, IN AXIAL PLANE



1. Bladder
2. Uterus
3. Head of femur
4. Gluteus maximus
5. Rectum
6. Ischium
7. Uterus
8. Cervix
9. Ilium
10. Rectum

Figures from Gray's Basic Anatomy, p. 263.